



# Anatomy of the eye

## Department of Optics

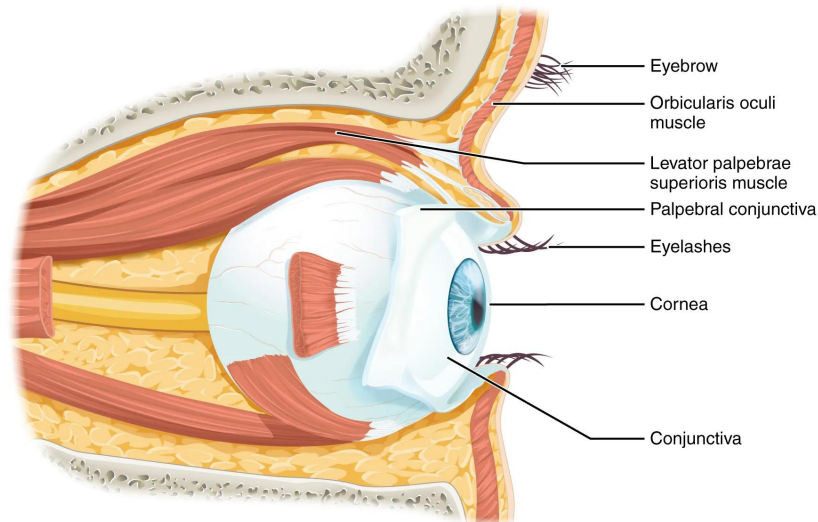
### The first stage

Dr. Fawzi Hammadi Mahdi

# Conjunctiva of Eye

Dr.Fawzi Hammadi

The conjunctiva of the eye seems to be the transparent, thin **membrane** that lines the interiors of the eyelids and a portion of the front of the eye. The conjunctiva is the membrane that covers the sclera, the tough **white fibre layer** that covers the eye, up to the edge of the cornea. It lines the eyelid (the clear layer in front of the iris and pupil). The conjunctiva contributes to the maintenance of the tear film and serves as a barrier against microscopic foreign objects and bacteria that can cause infections.



## Conjunctiva Parts and Anatomy

The **palpebral** or tarsal, bulbar or ocular, and conjunctival fornices are the three parts of the conjunctiva. Marginal, tarsal, and orbital regions make up the remainder of the palpebral conjunctiva. Scleral and limbal portions make up the **bulbar conjunctiva**. The superior, inferior, lateral, and medial regions of the conjunctival fornices are the final divisions.

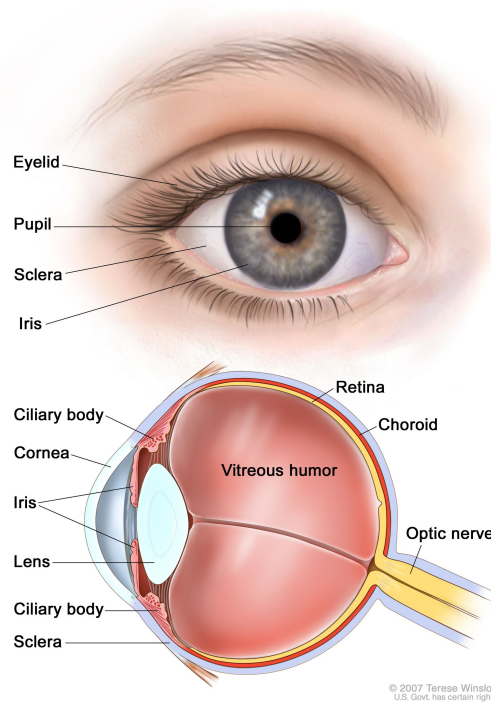
The conjunctiva palpebral lines the eyelids. On the **eyeball**, the anterior sclera is covered by the bulbar conjunctiva. It adheres to the underlying sclera thanks to **Tenon's capsule**. The conjunctiva of this eye is 33 microns thick on average. Last but not least, the intersection of the palpebral and bulbar conjunctiva is formed by the conjunctival fornices. Contrary to its bulbar counterpart, this protective covering is loose and flexible, allowing the globe and eyelids to move. Conjunctiva layers from outside to inside are **epithelium**, adenoid layer, and Fibrous layer.

## Functions of Conjunctiva

- Conjunctiva functions as eye lubricant through the production of mucus and tears, and thus protects the eye.
- It guards the immune system and stops microbes from getting inside the eye. It provides a covering for the sclera and lines the inside of the eyelids.
- It has numerous lymphatic vessels and is highly vascularized.
- 

## Sclera

**Strong tissue** that surrounds the eyeball is known as the sclera, or white of the eye. It shields your eyeball from harm and aids in maintaining its shape. The outermost, hard layer of the eyeball is called the **sclera**. It is white. The eyeball's sclera gives it structural support and guards against rupture and piercing. The entire sclera can change colour or develop coloured spots for a variety of reasons. Many scleral issues go away on their own in a few weeks, but not all of them do.



## Sclera Parts and Anatomy

From the exterior to the interior, the sclera is made up of four layers: The episclera is the transparent, delicate tissue that covers the whites of your eyes. Fibroblast- and collagen-fiber-rich stroma fusing with the episclera. Between the **sclera and the choroid and ciliary body**, the outer layer is a layer known as the lamina fusca.

## Functions of Sclera

The sclera serves as the eyeball's retaining wall. It safeguards your eyeball from harm and aids in maintaining its shape. **Conjunctiva**, which is transparent mucous membranes that lubricate (moisturise) your eye, cover the sclera. Your eyeball can be moved side to side and up and down with the assistance of sclera-attached [muscles](#).

## Difference Between Sclera and Conjunctiva

The **conjunctiva and sclera** are two crucial components of the eye. Both are layers of the eye's defence system. The sclera, or white component of the eye, covers the cornea and more than 80% of the rest of the eye. The inside lining of the eyelids and the sclera are covered by a thin, translucent membrane called the conjunctiva. The sclera has a small blood supply, but the conjunctiva has a high level of vascularization. Sclera and conjunctiva differences are compared side by side in the infographic below.

## Cornea

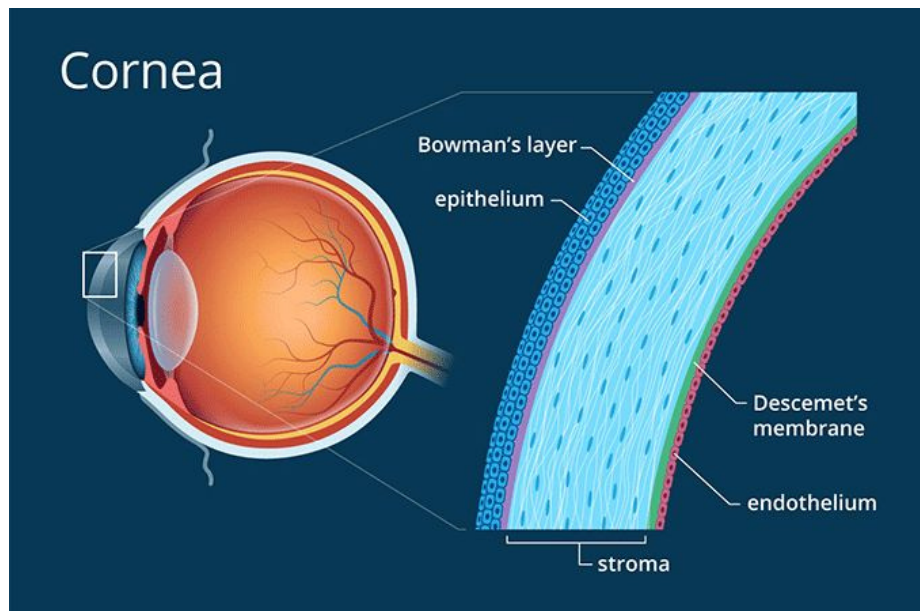
The cornea is the transparent part of the eye that covers the front portion of the eye. It covers the pupil (the opening at the center of the eye), iris (the colored part of the eye), and anterior chamber (the fluid-filled inside of the eye). The cornea's main function is to refract, or bend, light. The cornea is responsible for focusing most of the light that enters the eye.

The cornea is composed of proteins and cells. It does not contain blood vessels, unlike most of the tissues in the human body. Blood vessels may cloud the cornea, which may prevent it from refracting light properly and may adversely affect vision.

Since there are no nutrient-supplying blood vessels in the cornea, tears and the aqueous humor (a watery fluid) in the anterior chamber provide the cornea with nutrients.

The cornea is comprised of five layers: the epithelium, Bowman's layer, the stroma, Descemet's membrane, and the endothelium. The first layer, the epithelium, is a layer of cells covering the cornea. It absorbs nutrients and oxygen from tears and conveys it to the rest of the cornea. It contains free nerve endings. It also prevents foreign matter from entering the eye.

The cornea tends to repair itself quickly from minor abrasions. However, deeper abrasions may cause scars to form on the cornea, which causes the cornea to lose its transparency, leading to visual impairment

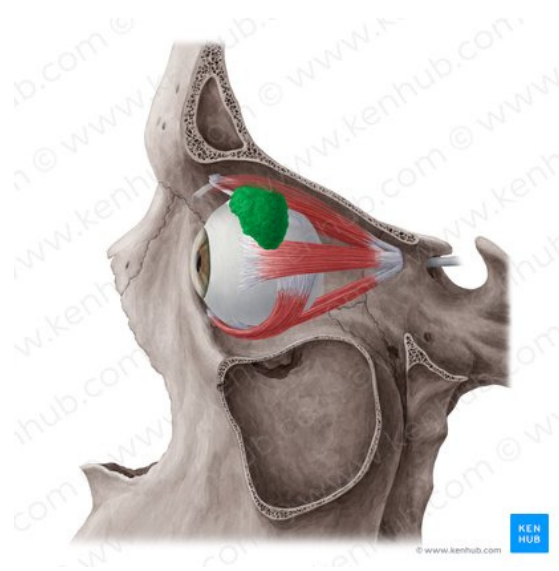


layers of cornea

# Lacrimal gland

Dr.Fawzi Hammadi

## Structure



Lacrimal gland / Glandula lacrimalis

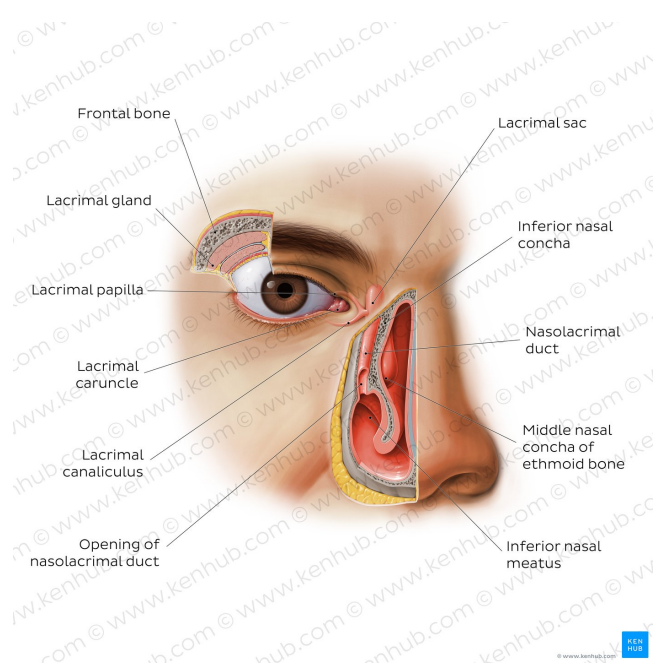
The lacrimal gland is an almond-shaped structure, about 2 cm in length. It is located in the anterior, superotemporal aspect of the orbit, within the lacrimal fossa of the frontal bone. The gland is split into two contiguous parts (lobes) by the lateral aponeurotic fibers of the levator palpebrae superioris muscle into an orbital part and a palpebral part. This division is only partial due to a posterior wall of parenchyma between the lobes.

- The larger orbital part rests above the aponeurosis of the levator palpebrae superioris muscle and the lateral rectus muscle laterally. It attaches to the periosteum of the orbit superiorly and the fascial sheath of the levator palpebrae superioris aponeurosis inferiorly. Anteriorly, it is bounded by the orbital septum, with the orbital fat serving as its posterior border.
- The palpebral part of the gland lies below the levator palpebrae superioris aponeurosis and projects into the superolateral aspect of the upper eyelid to attach to the superior conjunctival fornix. This part of the lacrimal gland can be observed clinically by everting the eyelid.

The lacrimal gland contains about 12 main excretory ducts. Ducts from the orbital part of the gland accompany those of the palpebral part by piercing through the levator palpebrae superioris aponeurosis to empty into the conjunctival sac. These ducts open along the lateral aspect of the superior fornix of the conjunctiva. In addition to the lacrimal gland, several accessory lacrimal glands (glands of Krause and Wolfring) are usually present in the palpebral conjunctiva. Although these glands are considerably smaller, they are structurally similar to the main lacrimal gland. The accessory glands account for about 10% of the total lacrimal secretion. Compared to the upper eyelid, the lower eyelid has fewer accessory lacrimal glands.

## Pathway of lacrimal fluid

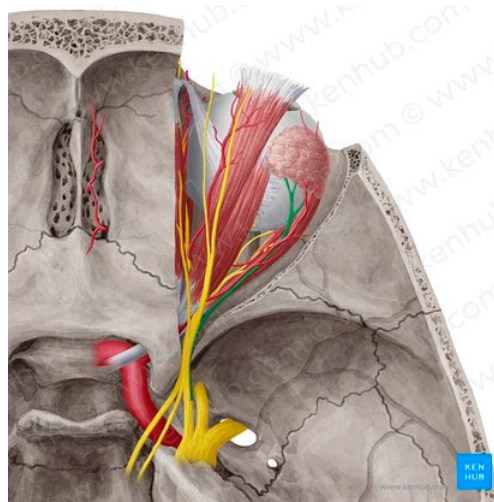
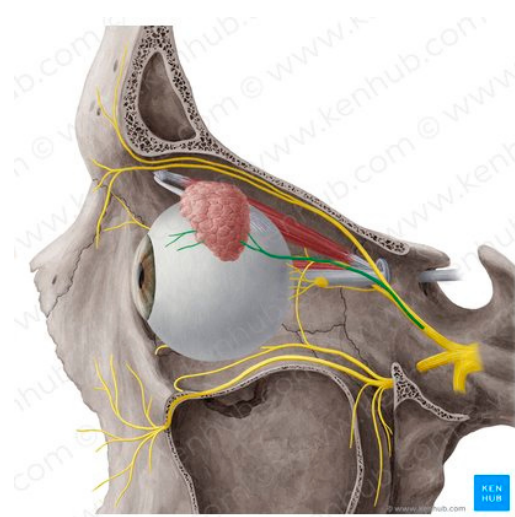
The lacrimal gland continuously secretes lacrimal fluid into the lateral aspect of the superior conjunctival fornix via the lacrimal ducts. The fluid is spread over the entire eye surface, from lateral to medial, with each blink. At the medial canthal region of the eye, the fluid collects in a triangular space called the lacrimal lake. The fluid is subsequently drained by capillary action into the lacrimal canaliculi which are small channels within each eyelid, via the lacrimal puncta. The lacrimal puncta are the openings of the lacrimal canaliculi which are located on the lacrimal papilla at the medial end of the upper and lower eyelids.



## Lacrimal apparatus

From the lacrimal canaliculi, lacrimal fluid drains medially into the lacrimal sac, the dilated upper aspect of the nasolacrimal duct. The lacrimal sac lies in a fossa formed by the lateral surface of the lacrimal bone and the frontal process of the maxilla. From the lacrimal sac, lacrimal fluid is carried by the nasolacrimal duct which opens at the anterior end of the inferior nasal meatus. This duct traverses a bony canal (nasolacrimal canal) formed by the lacrimal bone, maxilla and the inferior nasal concha. The fluid subsequently drains posteriorly through the nasal cavity to the nasopharynx, where it mixes with mucus and is ultimately swallowed. A small amount of lacrimal fluid is lost by evaporation or absorption across the conjunctiva.

## Innervation



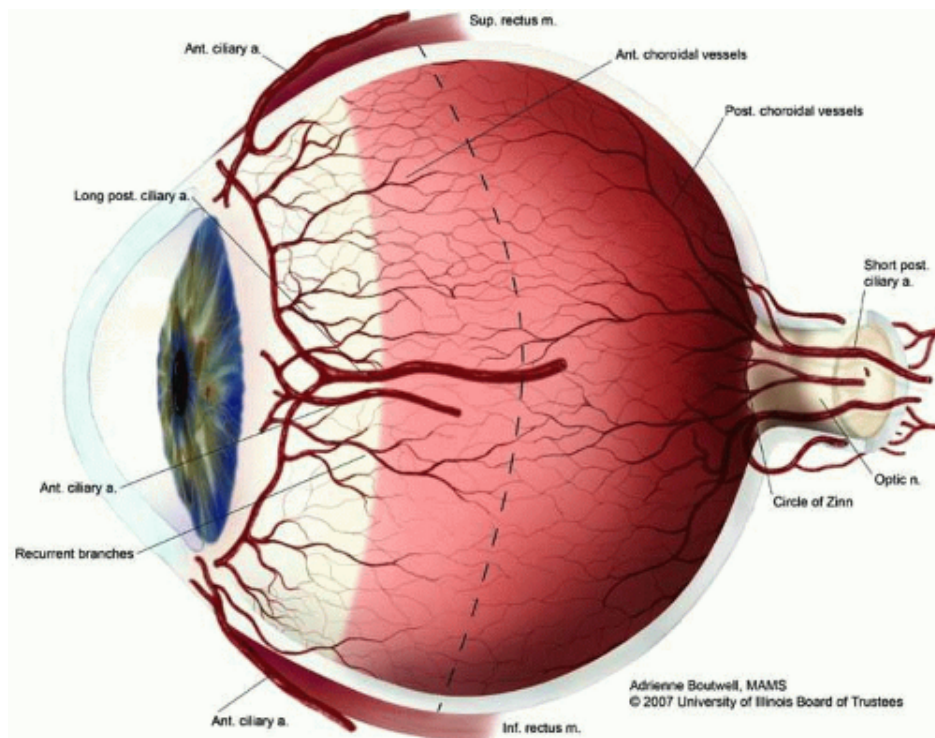
Lacrimal nerve /Nervus lacrimalis

The lacrimal gland receives sensory, parasympathetic, as well as sympathetic innervation.

- The lacrimal nerve, from the ophthalmic branch of the trigeminal nerve provides sensory innervation to the gland.
- Parasympathetic secretomotor neurons stimulate the secretion of lacrimal fluid. Preganglionic parasympathetic fibers from the central nervous system (CNS) reach the pterygopalatine ganglion via the greater petrosal nerve (a branch of the facial nerve) and the nerve of the pterygoid canal. These fibers synapse on postganglionic parasympathetic fibers within the ganglion, which then travel within the zygomatic and zygomaticotemporal branches of the maxillary nerve to supply the gland.
- Sympathetic innervation is from the superior cervical ganglion. From this ganglion, the nerve fibers reach the pterygopalatine ganglion via the internal carotid plexus and the deep petrosal nerve. The sympathetic fibers, subsequently, without synapsing in the ganglion, travel along the same path as the parasympathetic fibers supplying the lacrimal gland. Sympathetic innervation regulates blood flow through the lacrimal gland and glandular secretions.



Both the postganglionic parasympathetic secretomotor fibers and the postganglionic sympathetic fibers ultimately reach the lacrimal gland via the lacrimal nerve.



## History and etymology

The originally medieval Latin term comes from the Latin word *uva* ("grape") and is a reference to its grape-like appearance (reddish-blue or almost black colour, wrinkled appearance and grape-like size and shape when stripped intact from a cadaveric eye). In fact, it is a partial loan translation of the Ancient Greek term for the choroid, which literally means "covering resembling a grape". Its use as a technical term for part of the eye is ancient, but it only referred to the choroid in Middle English and before.

## Structure

### Regions

The uvea is the vascular middle layer of the eye. It is traditionally divided into three areas, from front to back:

- Iris
- Ciliary body
- Choroid

## Function

The prime functions of the uveal tract as a unit are:

- Nutrition and gas exchange: uveal vessels directly perfuse the ciliary body and iris, to support their metabolic needs, and indirectly supply diffusible nutrients to the outer

retina, sclera, and lens, which lack any intrinsic blood supply. (The cornea has no adjacent blood vessels and is oxygenated by direct gas exchange with the environment.)

- Light absorption: the uvea improves the contrast of the retinal image by reducing reflected light within the eye (analogous to the black paint inside a camera), and also absorbs outside light transmitted through the sclera, which is not fully opaque.

In addition, some uveal regions have special functions of great importance, including secretion of the aqueous humour by the ciliary processes, control of accommodation (focus) by the ciliary body, and optimisation of retinal illumination by the iris's control over the pupil. Many of these functions are under the control of the autonomic nervous system.

## Pharmacology

The pupil provides a visible example of the neural feedback control in the body. This is subserved by a balance between the antagonistic sympathetic and parasympathetic divisions of the autonomic nervous system. Informal pharmacological experiments have been performed on the pupil for centuries, since the pupil is readily visible, and its size can be readily altered by applying drugs—even crude plant extracts—to the cornea. Pharmacological control over pupil size remains an important part of the treatment of some ocular diseases.

Drugs can also reduce the metabolically active process of secreting aqueous humour, which is important in treating both acute and chronic glaucoma.

## Immunology

The normal uvea consists of immune competent cells, particularly lymphocytes, and is prone to respond to inflammation by developing lymphocytic infiltrates. A rare disease called sympathetic ophthalmia may represent 'cross-reaction' between the uveal and retinal antigens (i.e., the body's inability to distinguish between them, with resulting misdirected inflammatory reactions).

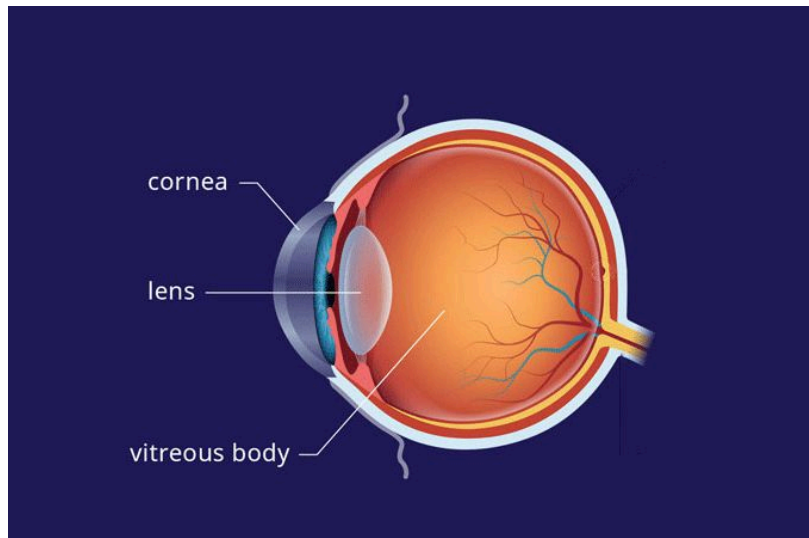
## Clinical significance

See uveitis, choroiditis, iritis, iridocyclitis, anterior uveitis, sympathetic ophthalmia, and uveal melanoma.

## Lens

The lens is a curved structure in the eye that bends light and focuses it for the retina to help you see images clearly. The crystalline lens, a clear disk behind the iris, is flexible and changes shape to help you see objects at varying distances.

As you age, the lens may become weaker or damaged. Since the lens changes shape to focus on images near or far, it can grow weaker and may not work as well later in life. Learn where the lens is and how it works.



# Anatomy

The lens is a clear, curved disk that sits behind the iris and in front of the vitreous of the eye. It is the part of the eye that focuses light and images from the outer world, bending them onto the retina.

## Structure

The crystalline lens is a clear, biconvex layer of the eye that is made up mostly of proteins. As much as 60% of the lens mass is made up of proteins—a concentration higher than almost any other tissue in the body. Four structures make up the crystalline lens:

Capsule

Epithelium

Cortex

Nucleus

Made up of collagen and proteins, the lens actually has no direct blood or nerve connections. Instead, it relies on the aqueous humor—the clear fluid between the lens and the cornea—to provide it with energy and carry away waste products.

The lens grows as you age, weighing about 65 milligrams at birth, 160 milligrams by age 10, and 250 milligrams by age 90.

The lens thickens and bends to transmit light from the cornea to the retina with the help of ciliary muscles. The ciliary body produces aqueous humor and bends the lens to refract light. The lens is held in place by zonular fibers, or zonules, that extend from the ciliary body.

# Location

Although the lens is thought to give the eye the most focusing power, the outermost structure of the eye, called the cornea, provides most of the focusing power. Behind the cornea is the iris, which creates a round aperture called the pupil. This pupil changes in size to regulate the amount of light that enters the eye. The crystalline lens sits just behind the iris.<sup>1</sup>

# Anatomical Variations

Anatomic variations can exist in the natural lens of the eye. Many different known and unknown congenital diseases can affect the lens in isolation or as part of a syndrome. Most often, these congenital defects present in the form of congenital cataracts or clouding of the crystalline lens.

Most congenital cataracts not associated with a syndrome have no identifiable cause, although genetic mutations are a common reason for cataract presentation. Cataracts at birth can present in one eye (unilaterally) or both eyes (bilaterally). Some of the syndromes associated with congenital cataracts include:

Galactosemia

Congenital rubella syndrome

Lowe syndrome

Down syndrome

Pierre-Robin syndrome

Hallerman-Streiff syndrome

Cerebrohepatorenal syndrome

Trisomy 13

Conradi syndrome

Ectodermal dysplasia

Marinesco-Sjogren syndrome

Congenital cataracts may not be evident for some time, progressing until the lens takes on a cloudy color and the child's sight is impaired. About one-third of congenital cataract cases are hereditary.

# Function

The lens works much like a camera lens, bending and focusing light to produce a clear image. The crystalline lens is a convex lens that creates an inverted image focused on the retina. The brain flips the image back to normal to create what you see around you. In a process called accommodation, the elasticity of the crystalline lens allows you to focus on images at far distances and near with minimal disruption.

Key facts about the neurovasculature of the eye

Arterial supply	<p><i>Origin:</i> ophthalmic artery</p> <p><i>Orbital group branches:</i> lacrimal, supraorbital, posterior ethmoidal, anterior ethmoidal and medial palpebral arteries</p> <p><i>Optical group branches:</i> long posterior ciliary, short posterior ciliary, anterior ciliary and central retinal arteries</p>
Venous drainage	<p>Central retinal, superior ophthalmic, inferior ophthalmic and middle ophthalmic veins</p>
Innervation	<p><i>Optic nerve:</i> sight</p> <p><i>Short ciliary nerves:</i> miosis and lens accommodation</p> <p><i>Long ciliary nerves:</i> mydriasis</p> <p><i>Oculomotor, trochlear, abducens nerves:</i> ocular movements</p> <p><i>Ophthalmic branch of trigeminal nerve:</i> eyeball, upper eyelid, nose ridge sensation</p>

in humans, specialized sense organ capable of receiving visual images, which are then carried to the brain.

### General description

#### [human eye](#)

Horizontal section of the eye.

The eyeball is not a simple sphere but can be viewed as the result of fusing a small portion of a small, strongly curved sphere with a large portion of a large, not so strongly curved sphere. The small piece, occupying about one-sixth of the whole, has a radius of 8 mm (0.3 inch); it is [transparent](#) and is called the cornea; the remainder, the scleral segment, is opaque and has a radius of 12 mm (0.5 inch). The ring where the two areas join is called the limbus. Thus, on looking directly into the eye from in front one sees the white sclera surrounding the cornea; because the latter is transparent one sees, instead of the cornea, a ring of tissue lying within the eye, the iris. The iris is the structure that determines the colour of the eye. The centre of this ring is called the pupil. It appears dark because the light passing into the eye is not reflected back to any great extent. By use of an ophthalmoscope, an instrument that permits the observer to [illuminate](#) the interior of the eyeball while observing through the pupil, the appearance of the interior lining of the globe can be made out. Called the fundus oculi, it is characterized by the large blood vessels that supply blood to the retina; these are especially distinct as they cross over the pallid optic disk, or papilla, the region where the optic nerve fibres leave the globe.

The dimensions of the eye are reasonably constant, varying among normal individuals by only a millimetre or two; the sagittal (vertical) [diameter](#) is about 24 mm (about one inch) and is usually less than the transverse diameter. At birth the sagittal diameter is about 16 to 17 mm (about 0.65 inch), it increases rapidly to about 22.5 to 23 mm (about 0.89 inch) by the age of three years, and between age three and 13 the globe attains its full size. The weight is about 7.5 grams (0.25 ounce) and its volume about 6.5 cm<sup>3</sup> (0.4 cubic inch).

The eye is made up of three coats, which enclose the optically clear aqueous humour, lens, and vitreous body. The outermost coat consists of the cornea and the sclera; the middle coat contains the main blood supply to the eye and consists, from the back forward, of the choroid, the ciliary body, and the iris. The innermost layer is the retina, lying on the choroid and receiving most of its nourishment from the [vessels](#) within the

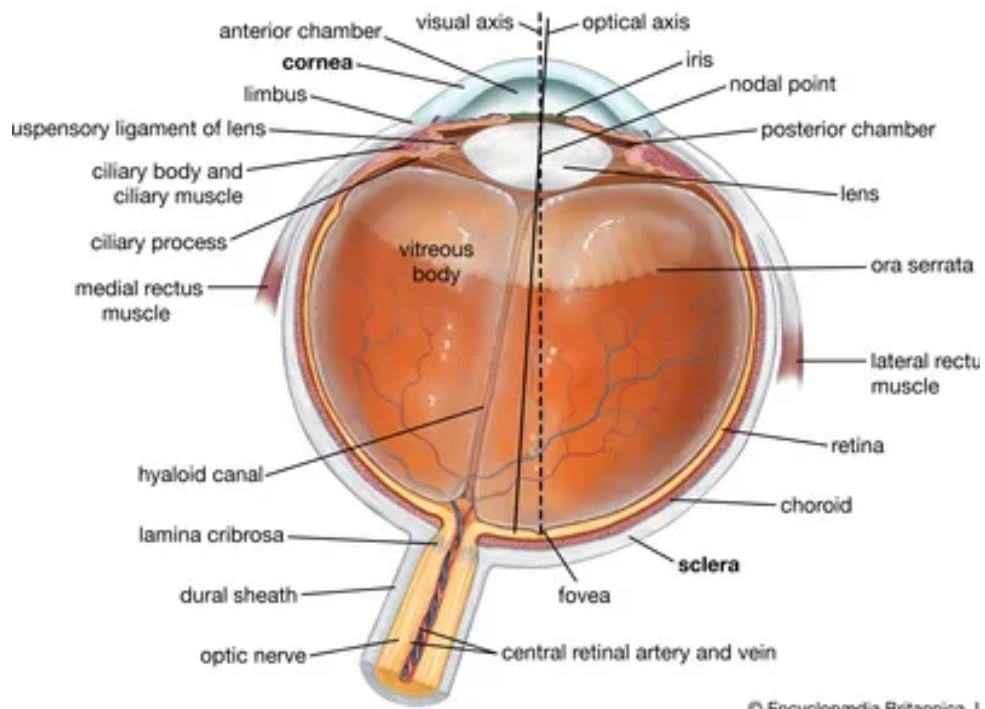
choroid, the remainder of its nourishment being derived from the retinal vessels that lie on its surface and are visible in the ophthalmoscope. The ciliary body and iris have a very thin covering, the ciliary epithelium and posterior epithelium of the iris, which is continuous with the retina.

Within the cavities formed by this triple-layered coat there are the crystalline lens, suspended by fine transparent fibres—the suspensory ligament or zonule of Zinn—from the ciliary body; the aqueous humour, a clear fluid filling the spaces between the cornea and the lens and iris; and the vitreous body, a clear jelly filling the much larger cavity enclosed by the sclera, the ciliary body, and the lens. The [anterior](#) chamber of the eye is defined as the space between the cornea and the forward surfaces of the iris and lens, while the posterior chamber is the much smaller space between the rear surface of the iris and the ciliary body, zonule, and lens; the two chambers both contain aqueous humour and are in connection through the pupil.

## The [orbit](#)

The eye is protected from mechanical injury by being enclosed in a socket, or orbit, which is made up of portions of several of the bones of the skull to form a four-sided pyramid, the apex of which points back into the [head](#). Thus, the floor of the orbit is made up of parts of the maxilla, zygomatic, and palatine bones, while the roof is made up of the orbital plate of the frontal bone and, behind this, by the lesser wing of the sphenoid. The [optic foramen](#), the opening through which the [optic nerve](#) runs back into the brain and the large ophthalmic artery enters the orbit, is at the nasal side of the apex; the superior orbital [fissure](#) is a larger hole through which pass large veins and nerves. These nerves may carry nonvisual sensory messages—e.g., pain—or they may be motor nerves controlling the muscles of the eye. There are other [fissures](#) and canals transmitting nerves and blood vessels. The [eyeball](#) and its functional muscles are surrounded by a layer of orbital fat that acts much like a cushion, permitting a smooth rotation of the eyeball about a virtually fixed point, the centre of rotation. The protrusion of the eyeballs—proptosis—in [exophthalmic](#) goitre is caused by the collection of fluid in the orbital [fatty tissue](#).





# The eyeball

Dr.Fawzi Hammadi

The **eyeball** is a bilateral and spherical organ, which houses the structures responsible for vision. It lies in a bony cavity within the facial skeleton – known as the [bony orbit](#).

Anatomically, the eyeball can be divided into three parts – the **fibrous**, **vascular** and **inner** layers. In this article, we shall consider the anatomy of the eyeball in detail, and its clinical correlations.

## Layers of the Eyeball

The eyeball is formed by three layers – fibrous, vascular and inner. Each of these layers has a specialised structure and function.

### Fibrous

The fibrous layer of the eye is the outermost layer. It consists of the **sclera** and **cornea**, which are continuous with each other. Their main functions are to provide shape to the eye and support the deeper structures.

The **sclera** comprises the majority of the fibrous layer (approximately 85%). It provides attachment to the [extraocular muscles](#) – these muscles are responsible for the movement of the eye. It is visible as the white part of the eye.

The **cornea** is transparent and positioned centrally at the front of the eye. Light entering the eye is refracted by the cornea.

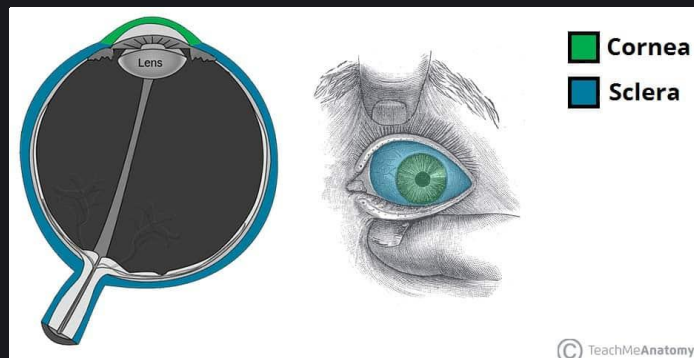


Fig 1.0 – The cornea and sclera of the eye.

### Vascular

The vascular layer of the eye lies underneath the fibrous layer. It consists of the choroid, ciliary body and iris:

- **Choroid** – layer of connective tissue and blood vessels. It provides nourishment to the outer layers of the retina.
- **Ciliary body** – comprised of two parts – the ciliary muscle and ciliary processes. The ciliary muscle consists of a collection of smooth muscle fibres. These are attached to the lens of the eye by the ciliary processes. The ciliary body controls the shape of the lens, and contributes to the formation of aqueous humor
- **Iris** – circular structure, with an aperture in the centre (the pupil). The diameter of the pupil is altered by smooth muscle fibres within the iris, which are innervated by the autonomic nervous system. It is situated between the lens and the cornea.

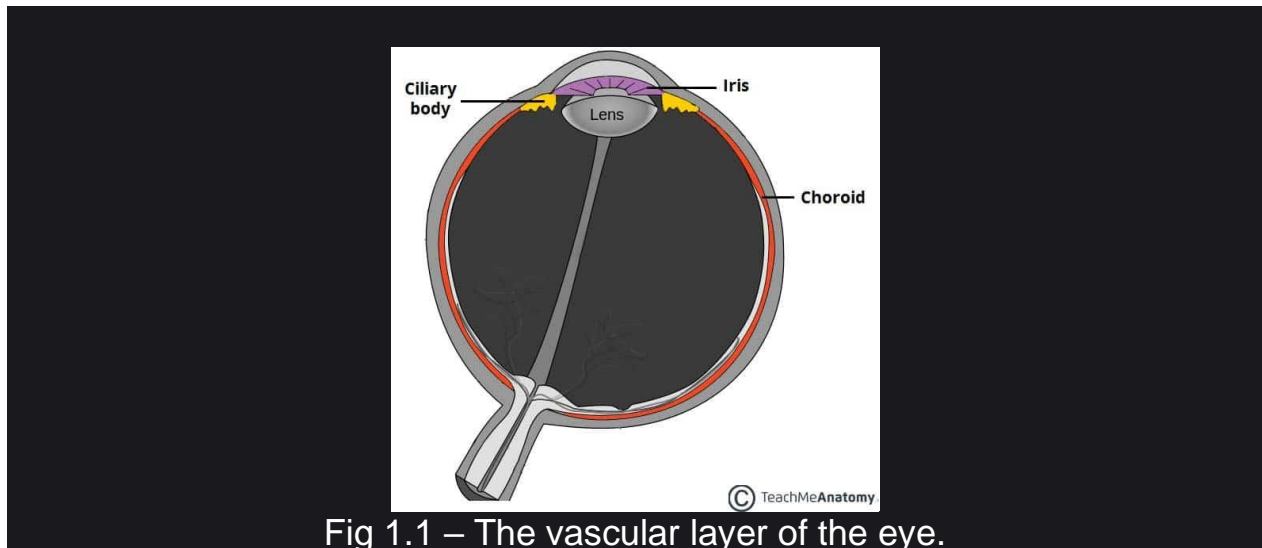


Fig 1.1 – The vascular layer of the eye.

### Inner

The inner layer of the eye is formed by the **retina**; its light detecting component. The retina is composed of two layers:

- **Pigmented (outer) layer** – formed by a single layer of cells. It is attached to the choroid and supports the choroid in absorbing light (preventing scattering of light within the eyeball). It continues around the whole inner surface of the eye.
- **Neural (inner) layer** – consists of photoreceptors, the light detecting cells of the retina. It is located posteriorly and laterally in the eye.

Anteriorly, the pigmented layer continues but the neural layer does not – this part is known as the **non-visual retina**. Posteriorly and laterally, both layers of the retina are present. This is the **optic** part of the retina.

The optic part of the retina can be viewed during ophthalmoscopy. The centre of the retina is marked by an area known as the **macula**. It is yellowish in colour, and highly pigmented. The macula contains a depression called the **fovea centralis**, which has a high concentration of light detecting cells. It is the area responsible for high acuity vision. The area that the optic nerve enters the retina is known as the optic disc – it contains no light detecting cells.

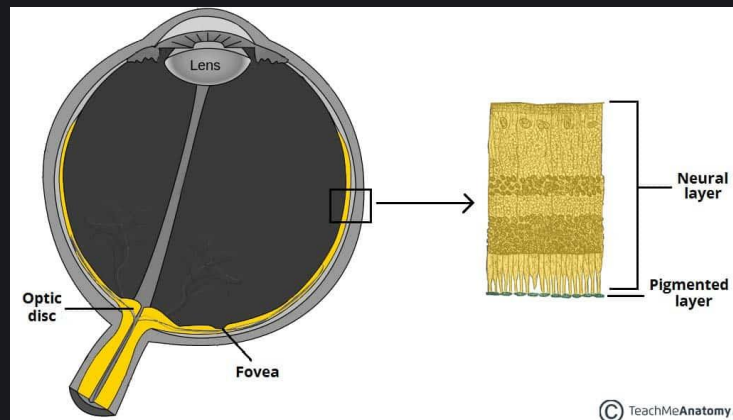


Fig 1.1 – The optic part of the retina.

## Structures of the Eyeball

### Vitreous Body

The **vitreous body** is a transparent gel which fills the posterior segment of the eyeball (the area posterior to the lens).

It is marked by a narrow canal which runs from the optic disc to the lens – the **hyaloid canal**. This is a fetal remnant.

The vitreous body has three main functions:

- Contributes to the magnifying power of the eye
- Supports the lens
- Holds the layers of the retina in place

### Lens

The lens of the eye is located anteriorly, between the vitreous humor and the pupil. The shape of the lens is altered by the **ciliary body**, altering its refractive power. In old age, the lens can become opaque – a condition known as a cataract.

## Anterior and Posterior Chambers

There are two fluid filled areas in the eye – known as the **anterior** and **posterior chambers**. The anterior chamber is located between the cornea and the iris, and the posterior chamber between the iris and ciliary processes.

The chambers are filled with **aqueous humor** – a clear plasma-like fluid that nourishes and protects the eye. The aqueous humor is produced constantly, and drains via the trabecular meshwork, an area of tissue at the base of the cornea, near the anterior chamber.

If the drainage of aqueous humor is obstructed, a condition known as **glaucoma** can result.

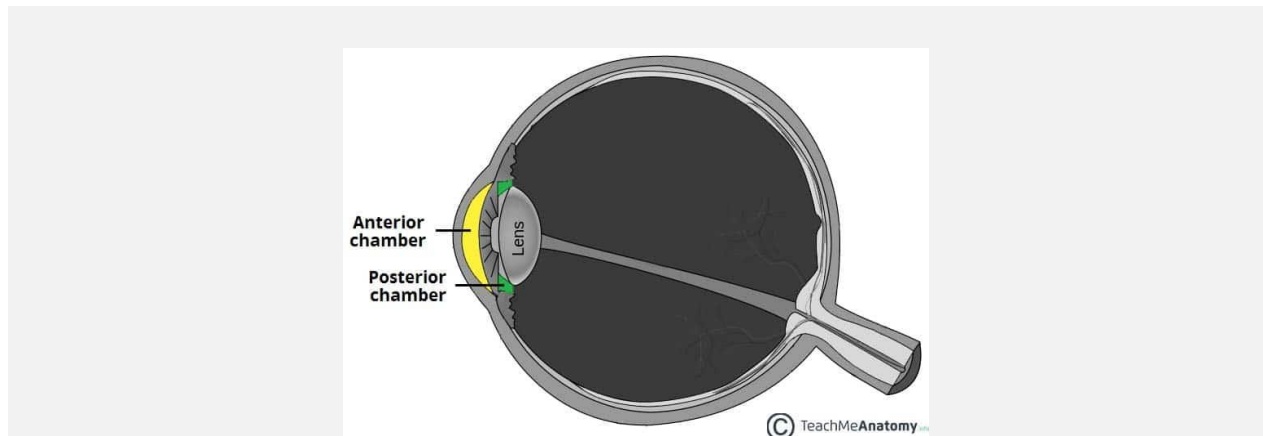


Fig 1.3 – Anterior and posterior chambers of the eye.

## Vasculature

The eyeball receives arterial blood primarily via the **ophthalmic artery**. This is a branch of the internal carotid artery, arising immediately distal to the cavernous sinus. The ophthalmic artery gives rise to many branches, which supply different components of the eye. The central artery of the retina is the most important branch – supplying the internal surface of the retina. Occlusion of this artery will quickly result in blindness.

Venous drainage of the eyeball is carried out by the **superior** and **inferior ophthalmic veins**. These drain into the cavernous sinus, a dural venous sinus in close proximity to the eye.

## The extraocular muscles and their nerve supply

---

The rectus muscles originate from the annulus of Zinn as described above and course forward through the orbital fat to insert onto the globe in their respective meridians along the spiral of Tillaux 5-8 mm from the limbus, medial rectus being closest to the limbus and superior rectus furthest from it. Together with the intramuscular septa they demarcate the intraconal space.

The medial rectus is closely applied to the lamina papyracea of the medial wall and is prone to entrapment in medial wall fractures with resultant retraction of the globe and narrowing of the palpebral aperture on attempted abduction (pseudo-Duane's syndrome).<sup>12</sup> It is also susceptible to iatrogenic damage in ethmoid sinus surgery, when inadvertent orbital entry may occur.<sup>3</sup>

The inferior rectus lies close to the floor posteriorly but has fat interposed anteriorly. In blow-out floor fractures, the inferior rectus may prolapse into the bony defect together with fat herniating into the maxillary antrum. Incarceration of the inferior rectus muscle sheath and its fibrous septa that radiate towards the orbital floor may occur in blow-out floor fractures, even in the absence of a significant bony defect or soft tissue herniation, resulting in restricted elevation and depression of the eye.

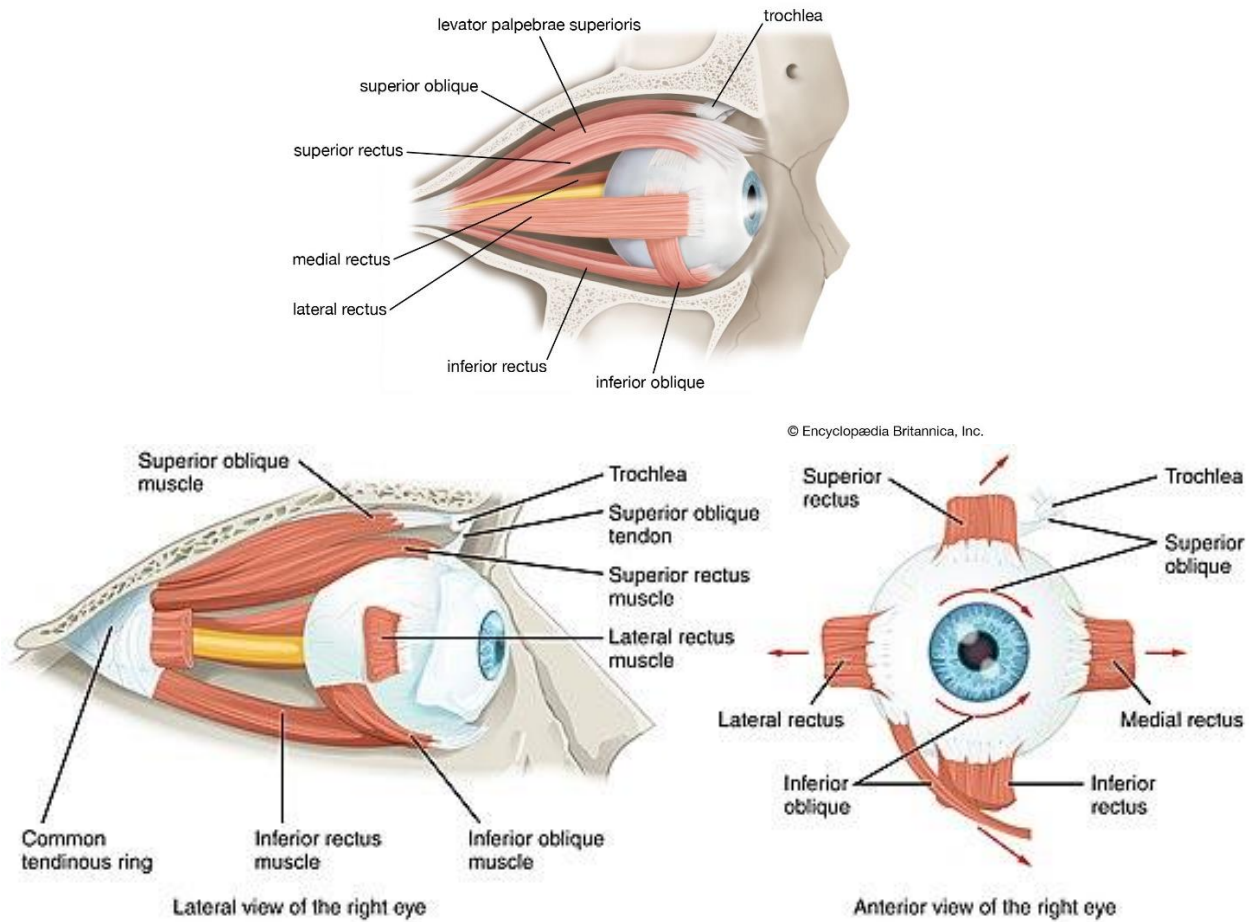
The lateral rectus muscle is separated from the lateral orbital wall by fat. Posteriorly, the ciliary ganglion lies between it and the optic nerve. The nerves entering the orbit within the annulus of Zinn also separate it from the optic nerve. The lacrimal gland lies superior to its terminal portion and the lacrimal artery and nerve also lie above it.

The levator palpebrae superioris originates from the lesser wing of sphenoid just above and slightly medial to the superior rectus. The two arise from the same embryonic mesenchyme and are intimately related. They diverge about the equator of the globe, at which point the superior rectus travels inferiorly to attach to the globe whereas the levator continues forward becoming aponeurotic in the region of Whitnall's ligament. The aponeurosis fans out to insert onto the anterior surface of the tarsal plate and the eyelid skin. It also attaches via the 'horns' adjacent to the medial and lateral canthal tendons. While passing forward in the orbit, the nasociliary nerve and ophthalmic artery cross from lateral to medial below the superior rectus. Superior relations of the levator are the supraorbital artery and the lacrimal and frontal nerves.

The superior oblique arises from the annulus of Zinn superomedially and courses close to the periorbita just above the fronto-ethmoid suture towards the trochlea. After passing through the trochlea, its tendon fans out laterally, inferiorly, and posteriorly below the superior rectus to insert onto the globe in a broad fashion extending to the posterolateral aspect of the globe.

The inferior oblique arises from the periorbita of the inferomedial orbit just lateral to the origin of the nasolacrimal duct and courses laterally and posteriorly below the inferior rectus. Before inserting onto the inferolateral aspect of the globe in a broad attachment, the muscle is enveloped by fibres of the capsulopalpebral fascia and Lockwood's inferior suspensory ligament of the globe.

### Muscles of the right eye



The extraocular muscles are supplied by the oculomotor nerve (III) except lateral rectus, which is supplied by the abducens nerve (VI) and the superior oblique, which is supplied by the trochlear nerve (IV). The nerve supply to the recti travel forward in the intraconal space and enter the respective muscles on their deep surface at the junction of the posterior third and anterior two-thirds.

The oculomotor nerve divides in the cavernous sinus into superior and inferior divisions that enter the orbit separately inside the annulus of Zinn. The superior division supplies the levator and superior rectus muscles, whereas the inferior division supplies the medial rectus, inferior rectus and the inferior oblique. The branch to inferior oblique travels along the lateral border of inferior rectus and enters the inferior oblique as it crosses the inferior rectus, where it is susceptible to iatrogenic injury. It carries preganglionic parasympathetic fibres to the ciliary body and iris sphincter which synapse in the ciliary ganglion.

The trochlear nerve enters the orbit just outside the annulus, having crossed superior to the oculomotor nerve in the lateral wall of the cavernous sinus. It travels forward in the orbit crossing from lateral to medial to enter the lateral border of superior oblique at the junction of the posterior third and anterior two-thirds.

The abducens nerve enters the orbit within the cone and travels along the medial surface of lateral rectus piercing the muscle at the junction of the posterior third and anterior two-thirds.

## Sensory nerves

---

The sensory nerves of the orbit ([Figure 11](#)) derive mostly from the ophthalmic division of the trigeminal nerve ( $V_1$ ) with some contribution from the maxillary division ( $V_2$ ).  $V_1$  divides in the lateral wall of the cavernous sinus into lacrimal, frontal, and nasociliary branches that enter the superior orbital fissure.

The lacrimal and frontal nerves enter the fissure outside the annulus of Zinn and travel forward in the superior orbit. The lacrimal nerve, the smallest branch of  $V_1$ , travels along the superior border of the lateral rectus muscle towards the lacrimal fossa, where it supplies postganglionic secretomotor fibres to the lacrimal gland and sensory fibres to the surrounding skin and conjunctiva. The preganglionic secretomotor fibres originate in the facial nerve nucleus in the brainstem and travel in the nervus intermedius to enter the internal auditory meatus. They pass through the geniculate ganglion to reach the pterygopalatine ganglion via the greater petrosal nerve. After synapsing in the pterygopalatine ganglion, the postganglionic secretomotor fibres join the maxillary nerve which they later leave, via its zygomaticotemporal branch, to anastomose with the lacrimal nerve just before it supplies the lacrimal gland.

The frontal nerve, the largest branch of  $V_1$ , passes anteriorly in the superior orbit between the levator muscle and the periorbita. It divides into the supraorbital and supratrochlear branches. The former exits at the supraorbital notch and occupies a bony canal in 25% of cases. It supplies the brow, forehead, and scalp just beyond the vertex. The supratrochlear nerve passes medially towards the trochlea and supplies the medial upper lid and forehead.

The nasociliary nerve enters the superior orbital fissure within the muscle cone, crosses over the optic nerve and passes forward between the superior oblique and medial rectus muscles. Its branches include the anterior and posterior ethmoidal nerves, two or three long posterior ciliary nerves to the globe and the sensory root to the ciliary ganglion. It terminates as the infratrochlear nerve which supplies the medial canthus and the tip of the nose.

The maxillary nerve ( $V_2$ ) enters the pterygopalatine fossa from the foramen rotundum. After giving off sphenopalatine, posterior superior alveolar, and zygomatic branches the main bulk of the nerve passes through the inferior orbital fissure to enter the infraorbital sulcus as the infraorbital nerve, which passes forward through the infraorbital canal exiting at the infraorbital foramen and supplying the lower lid skin and conjunctiva, cheek, and the upper lip. Within the infraorbital canal, the infraorbital nerve gives off the anterior superior alveolar branch supplying the upper front teeth. The zygomatic branch of  $V_2$  passes through the inferior orbital fissure and divides into zygomaticotemporal and zygomaticofacial branches that supply the skin overlying the lateral orbit and zygoma. The zygomaticotemporal branch also delivers secretomotor fibres destined for the lacrimal gland to the lacrimal nerve.



## The ciliary ganglion

---

The ciliary ganglion sits on the lateral aspect of the optic nerve, close to the orbital apex. It receives a sympathetic, parasympathetic, and sensory root. The sympathetic fibres, destined for the iris dilator and ocular blood vessels, reach the ganglion from the carotid plexus via the superior orbital fissure. Preganglionic parasympathetic fibres to the iris sphincter and ciliary body are delivered to the ganglion by the nerve to inferior oblique. The sensory fibres to the globe are supplied by the nasociliary nerve. Only the parasympathetic fibres synapse in the ciliary ganglion. Five to six short ciliary nerves pass from the ciliary ganglion to the globe, inserting around the optic nerve.

# THE ORBIT

Dr.Fawzi Hammadi

The bony orbits (or eye sockets) are bilateral and symmetrical **cavities** in the head. They enclose the eyeball and its associated structures.

In this article, we shall look at the borders, contents and clinical correlations of the bony orbit.

## STRUCTURE AND ANATOMICAL RELATIONS

The orbit can be thought of as a **pyramidal** structure, with the apex pointing posteriorly and the base situated anteriorly. The boundaries of the orbit are formed by seven bones.

It is also important to consider the anatomical relations of the orbital cavity – this is clinically relevant in the spread of infection, and in cases of trauma.

The borders and anatomical relations of the bony orbit are as follows:

**Roof** (superior wall) – Formed by the frontal bone and the lesser wing of the **sphenoid**. The frontal bone separates the orbit from the **anterior cranial fossa**.

**Floor** (inferior wall) – Formed by the maxilla, palatine and zygomatic bones. The maxilla separates the orbit from the underlying maxillary sinus.

**Medial wall** – Formed by the **ethmoid**, maxilla, lacrimal and **sphenoid** bones. The **ethmoid** bone separates the orbit from the ethmoid sinus.

**Lateral wall** – Formed by the zygomatic bone and greater wing of the **sphenoid**.

**Apex** – Located at the opening to the optic canal, the optic foramen.

**Base** – Opens out into the face, and is bounded by the eyelids. It is also known as the orbital rim.

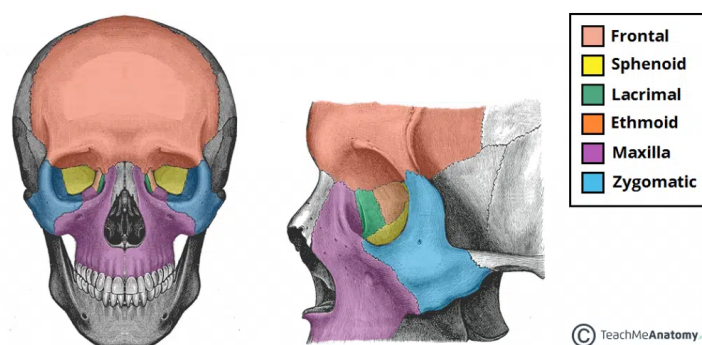


Fig 1 – The anterior and lateral views of the bony orbit.

# Contents

The bony orbit contains the **eyeballs** and their associated structures:

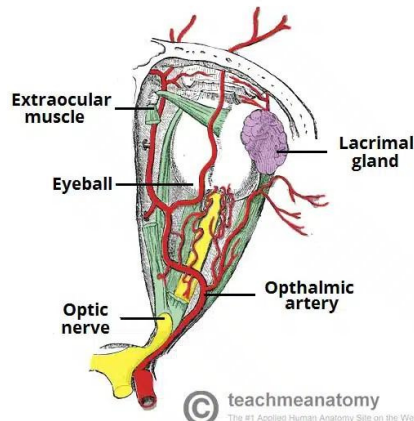


Fig 1.1 – Diagram of the arterial supply to the eye.

**Extra-ocular muscles** – These muscles are separate from the eye. They are responsible for the movement of the eyeball and superior eyelid.

**Eyelids** – These cover the orbits anteriorly.

**Nerves:** Several cranial nerves supply the eye and its structures; **optic**, **oculomotor**, **trochlear**, **trigeminal** and **abducens** nerves.

**Blood vessels:** The eye receives blood primarily from the ophthalmic artery. Venous drainage is via the superior and inferior ophthalmic veins.

Any space within the orbit that is not occupied is filled with **orbital fat**. This tissue cushions the eye, and stabilises the **extraocular muscles**.

# OPENINGS AND Pathways into the Orbit

There are three main pathways by which structures can enter and leave the orbit:

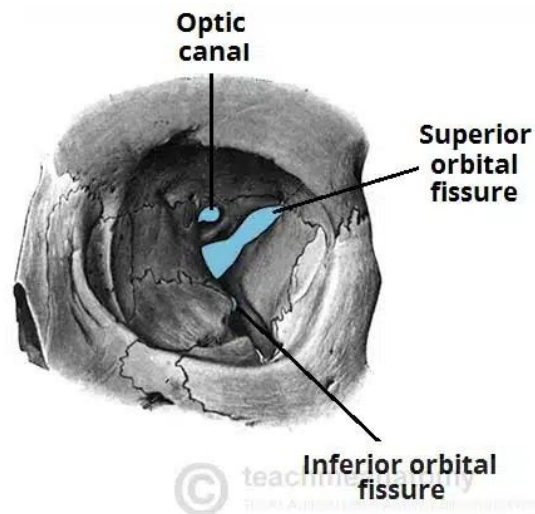


Fig 1.2 – The major openings into the orbit.

**Optic canal** – transmits the **optic nerve** and ophthalmic artery.

**Superior orbital fissure** – transmits the lacrimal, frontal, **trochlear** (CN IV), **oculomotor** (CN III), nasociliary and abducens (CN VI) nerves. It also carries the superior ophthalmic vein.

**Inferior orbital fissure** – transmits the zygomatic branch of the maxillary nerve, the inferior ophthalmic vein, and sympathetic nerves.

There are other minor openings into the orbital cavity. The **nasolacrimal canal**, which drains tears from the eye to the nasal cavity, is located on the medial wall of the orbit. Other small openings include the **supraorbital foramen** and **infraorbital canal** – they carry small neurovascular structures.