



علم الحركة
قسم تقنيات العلاج الطبيعي
المرحلة الأولى
م.د. صلاح فاضل عبد الجبار

Review

CHARACTERISTICS OF GAIT

Vertical displacement occurs as the centre of gravity rises at mid-stance and falls at double support. The range of movement during vertical displacement is less than 50 mm.

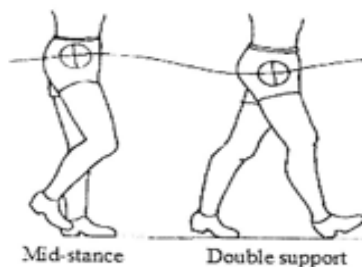
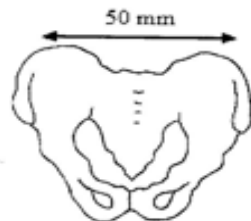


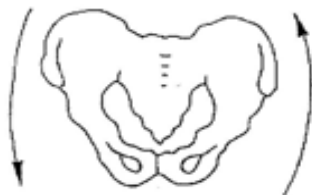Fig. 10.5 Vertical displacement

Lateral displacement of the occurs as body sways in the direction of the leg that is on the ground. The CoG must be over the base of support. The range of movement that occurs during lateral displacement is less than 50 mm.



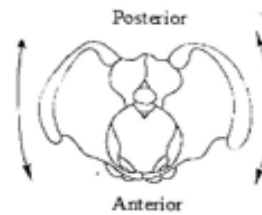
Posterior view of pelvis showing lateral displacement

Pelvic dip occurs as the pelvis drops towards the side that is in swing phase. The size of the drop is about 5°.



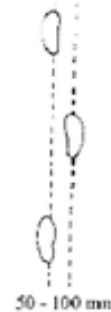
Posterior view of pelvis

showing pelvic dip
Pelvic rotation occurs as the pelvis swings in an anterior-posterior direction. The pelvis swings anterior with the swinging leg. The range of movement is about 4°.



Top view of pelvis showing pelvic rotation

Walking base is the distance between the mid-point of the heels. The usual distance is 50-100 mm.



Walking base

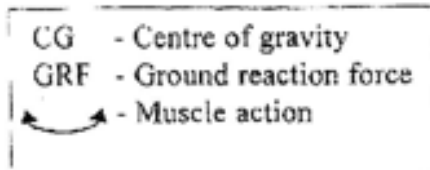
Double support is when both feet are on the ground. It occurs when one foot is at heel strike, and the other is between heel off and toe off. Double support occurs only in walking. The period of double support is reduced as the speed of walking increases. When there is no double support, a person is running.

Timing-At normal speed, 60% of the time is spent in stance phase, 40% in swing phase and 10% in double support.

Cadence is the number of steps taken per minute. 70 steps per minute is normal. 130 steps per minute is the fastest we can walk without running

ANALYSIS OF NORMAL WALKING MOTION

The following pictures present one complete gait cycle showing the line of the ground reaction force, muscle action and joint position at specific times during the cycle

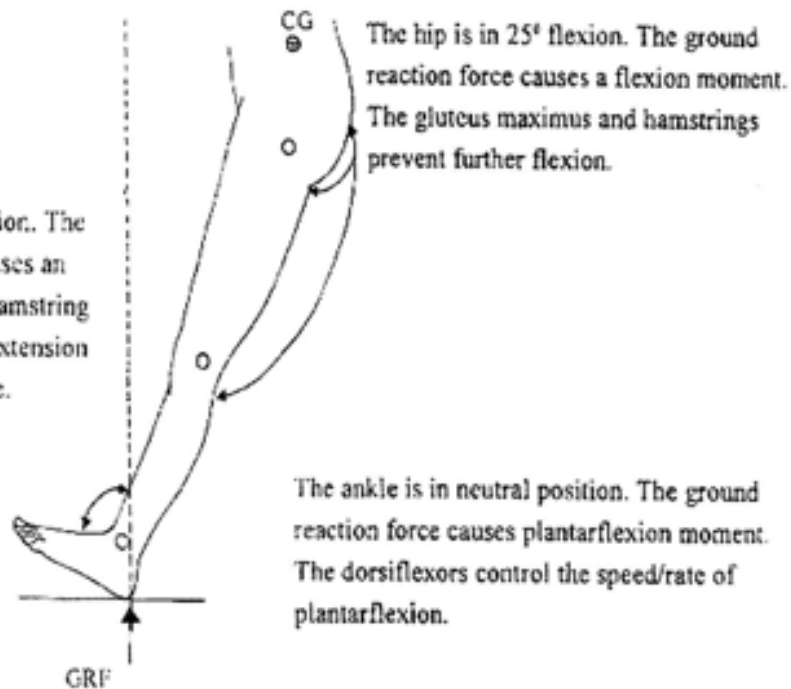


Reaction

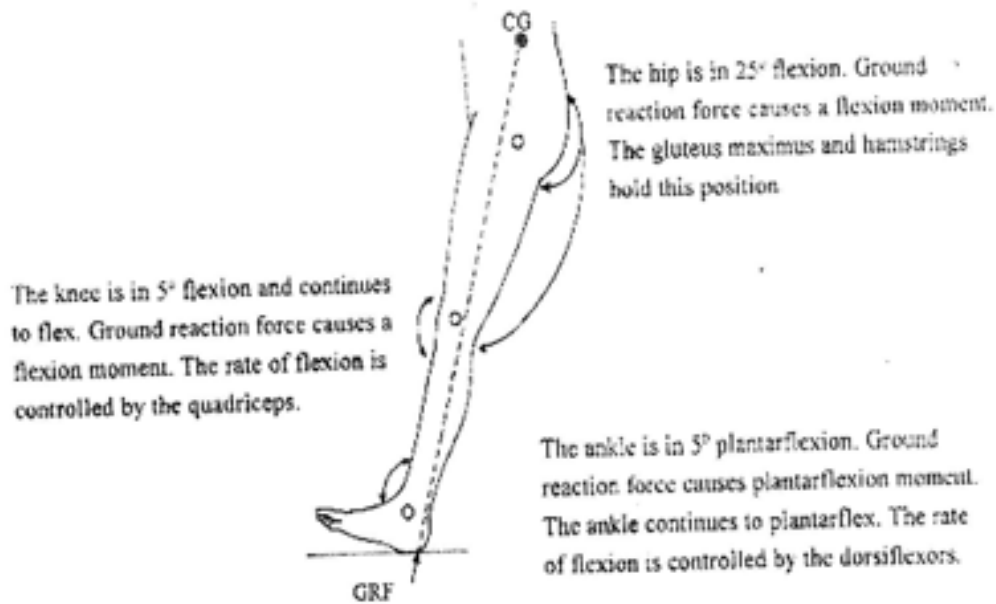
- Anterior to hip causing flexion moment
- Anterior to knee causing extension moment
- Posterior to ankle causing plantarflexion moment

Heel strike

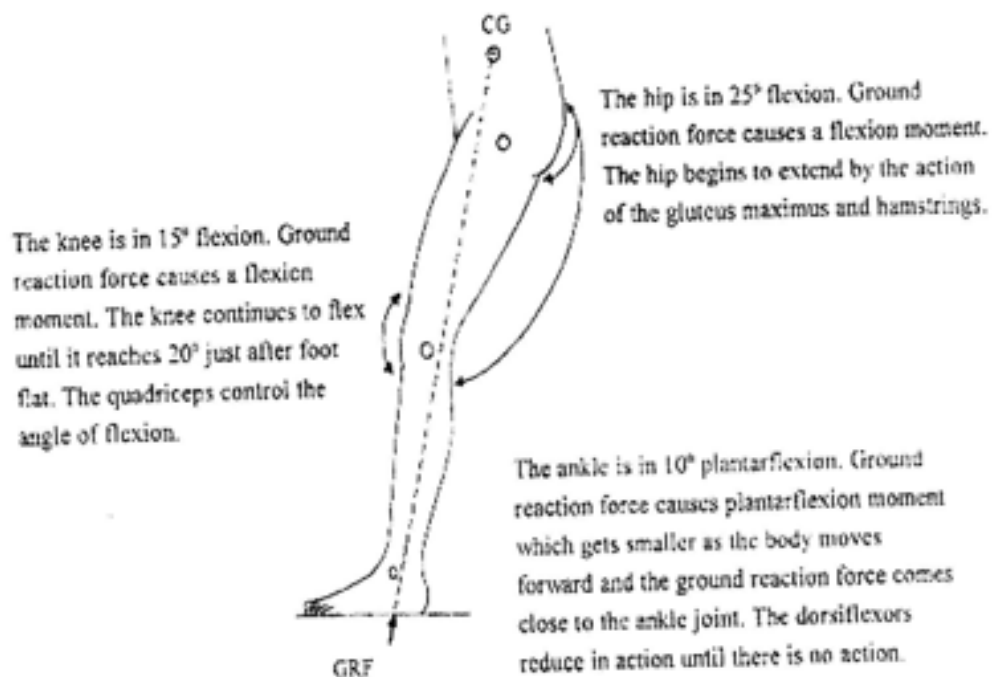
The knee is in full extension. The ground reaction force causes an extension moment. The hamstring muscles prevent further extension and begin to flex the knee.



Shortly after heel strike




Foot flat



Toe-off

The ground reaction force is not significant for all three joints as most of the weight is on the other leg.

The knee is in 40° of flexion. Flexion continues due to the small ground reaction force moment and the plantarflexion of the foot.

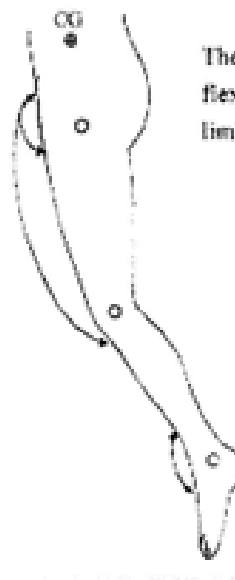


The hip is in 10° of extension and continues to flex due to the plantarflexion of the foot and the activity of the rectus femoris.

The ankle is in 20° of plantarflexion. The plantarflexor muscles stop acting as soon as the toes leave the ground.

Acceleration

The knee is in 40° of flexion and continues to flex under pendulum action as the limb accelerates.

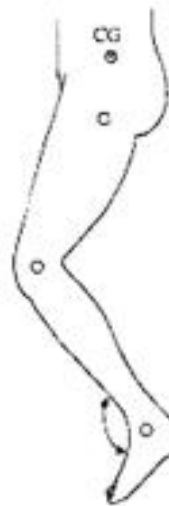

The hip is in 10° of extension and flexes as the hip flexors accelerate the limb forward.

The ankle is in 20° of plantarflexion directly after toe off. It then begins to dorsiflex under the action of the peroneal group of muscles.

Mid-swing

The knee reaches about 65° of flexion then begins to extend under pendulum action.

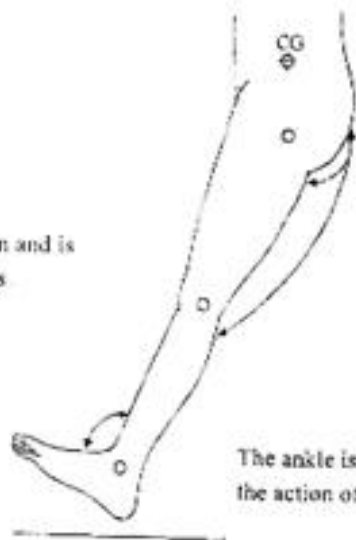


The hip is flexed to about 20° and continues to flex.

The ankle has reached its neutral position and is held there by slight activity of the pretibial muscles.

Deceleration

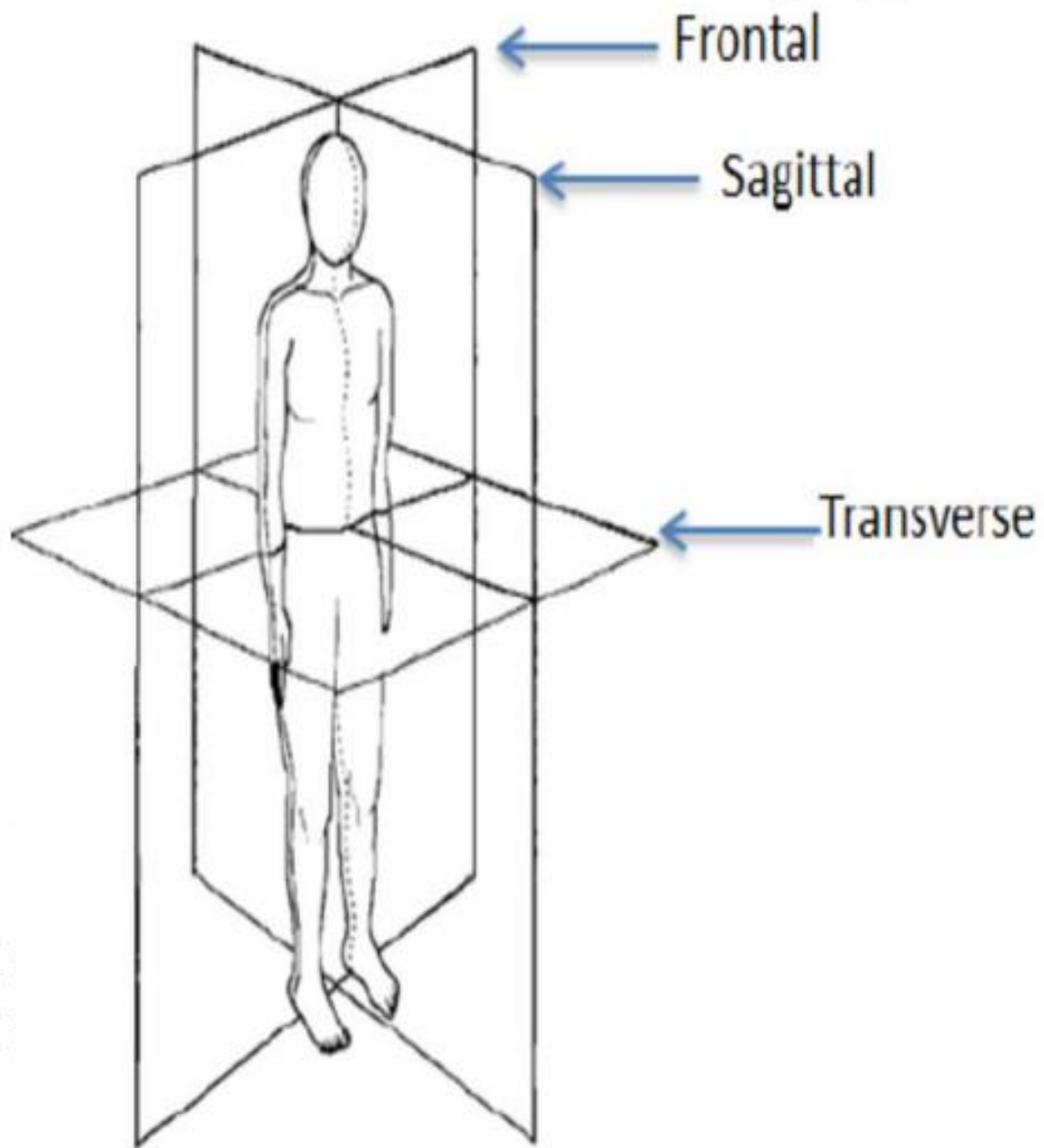
The knee is in full extension and is restrained by the hamstrings.



The hip reaches 25° of flexion and is restrained by the gluteus maximus and the hamstrings.

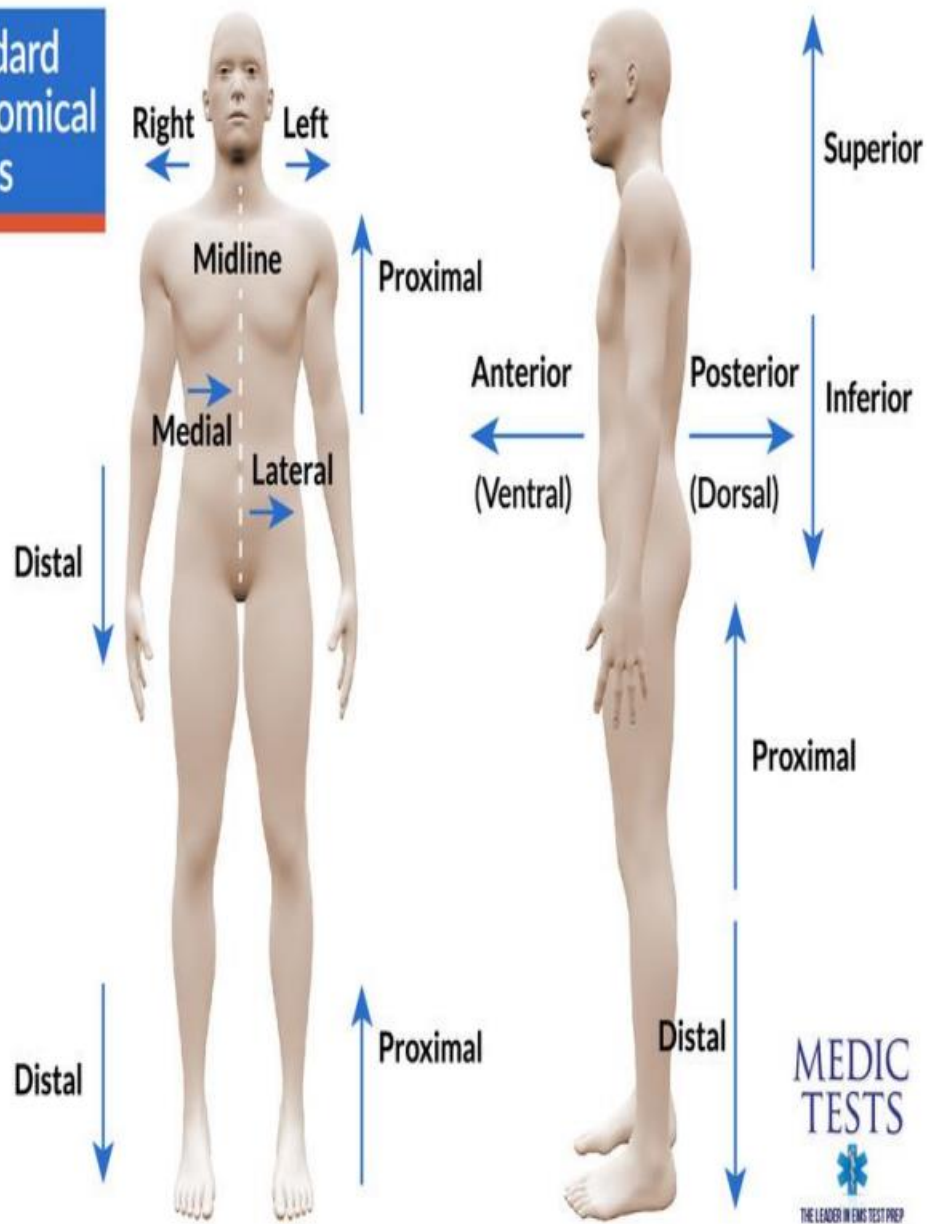
The ankle is still held in the neutral position by the action of the pretibial muscles.

The hip, knee and ankle are now positioned for the following heel strike.
All the muscle groups that are necessary to counteract the ground reaction force are now active.

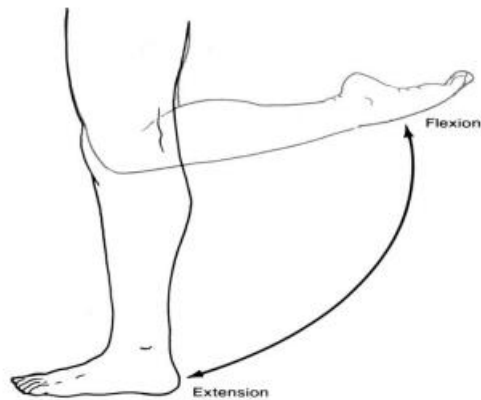


1/10/2024

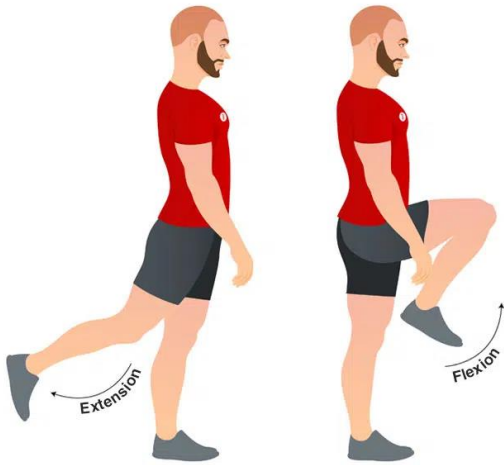
**Standard
Anatomical
Terms**



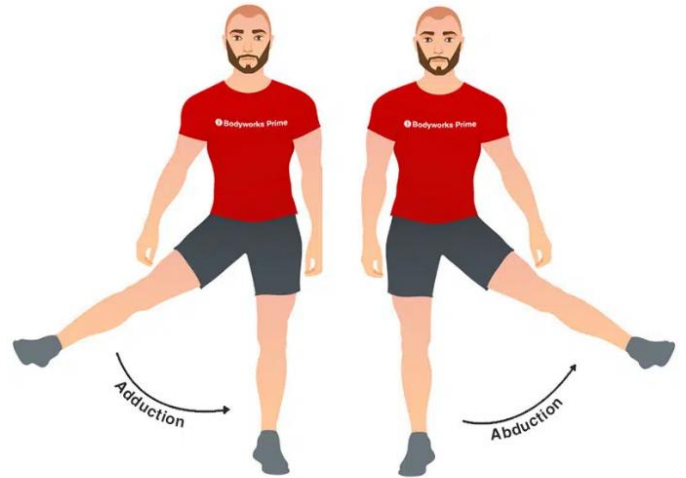
- Knee – flexion/extension



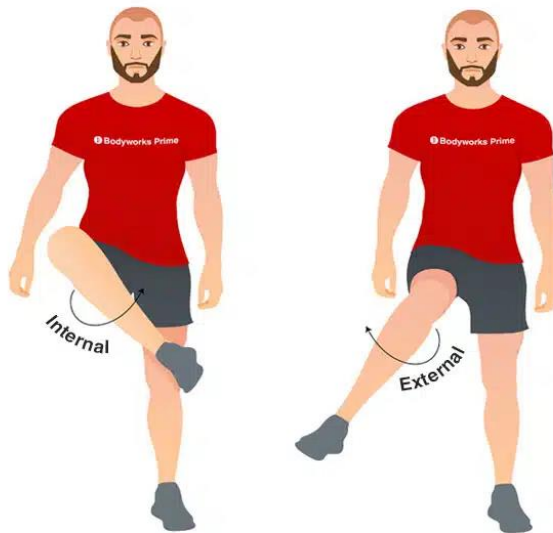
Hip Flexion



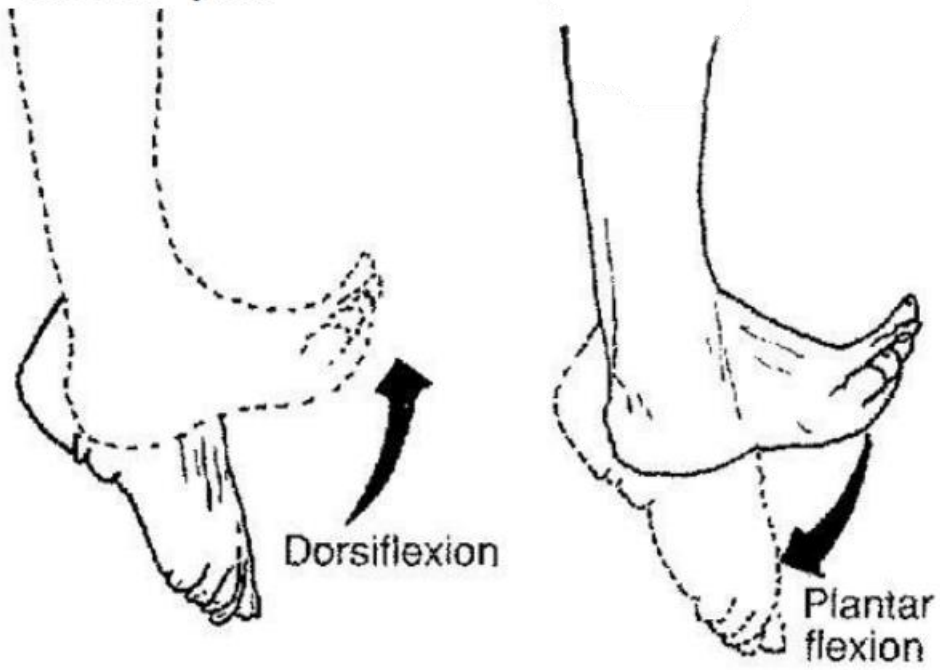
Hip Adduction



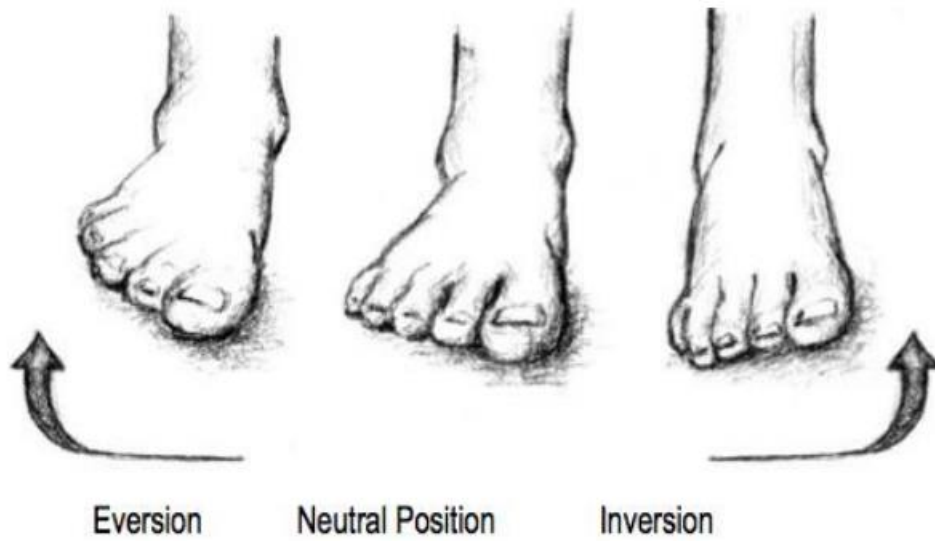
Hip Internal & External Rotation

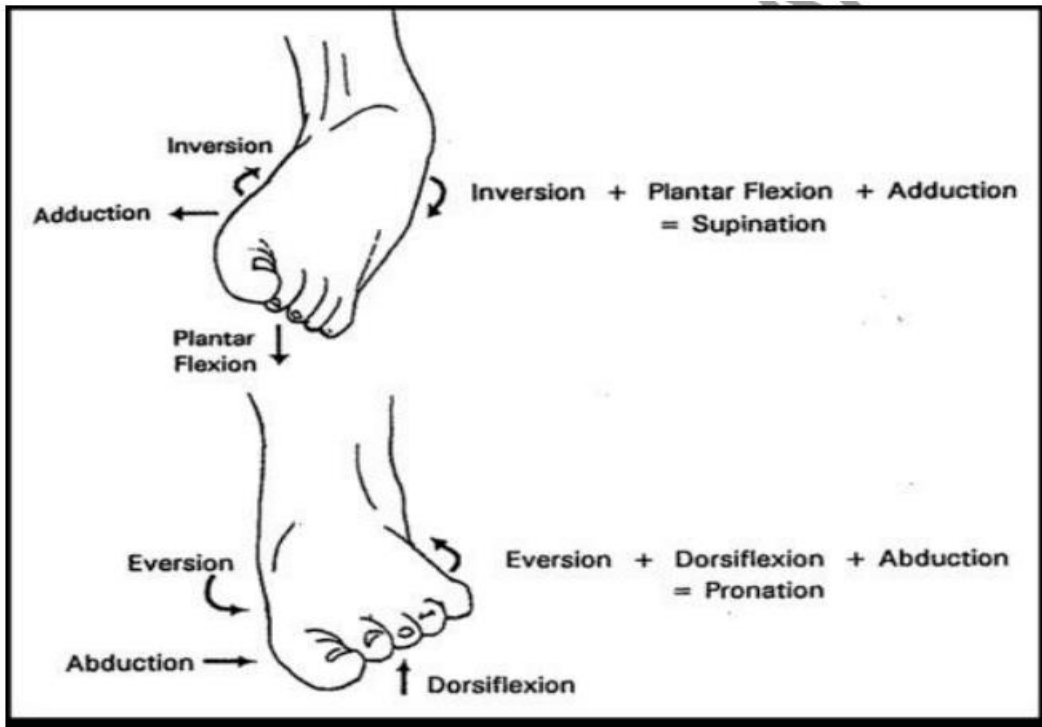


- Ankle Joint – plantar flexion/dorsiflexion



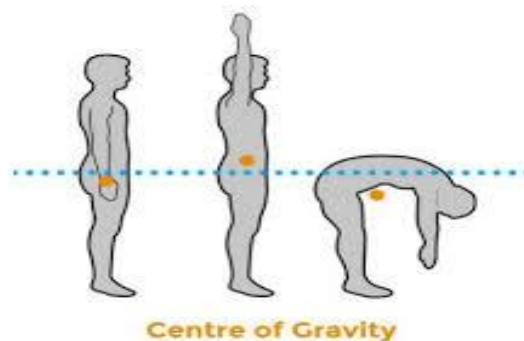
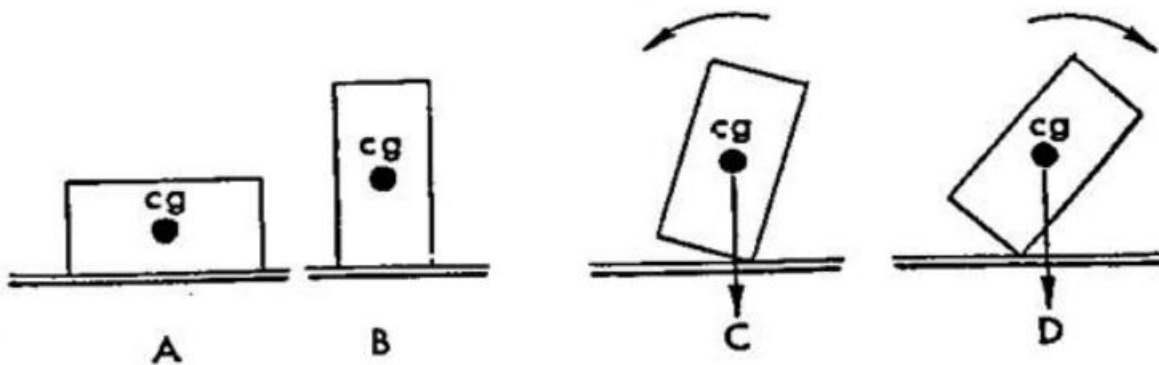
- Subtalar Joint – inversion/eversion

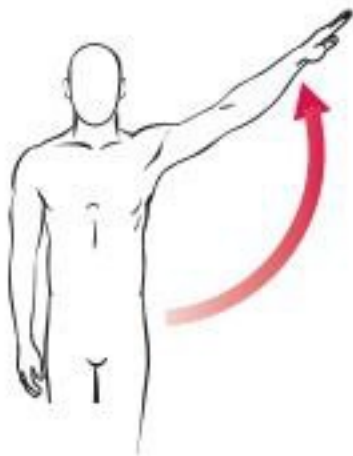




Center Of Gravity

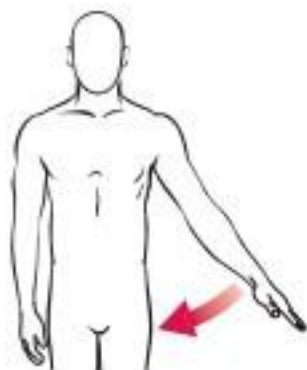
The center of gravity (CG) location is the average location of all the weight of an object. The center of gravity is the balance point of an object, also expressed as the point where all the mass appears to be located.





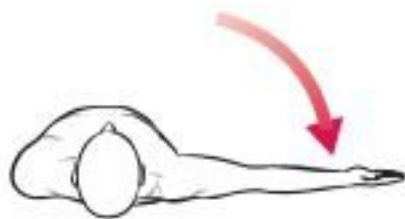
Shoulder abduction

A



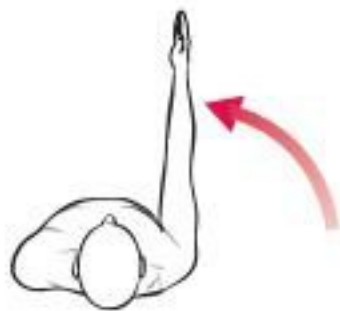Shoulder adduction

B



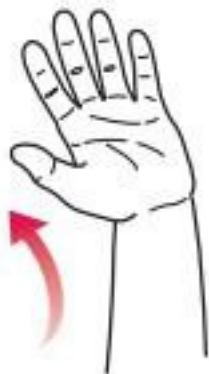Shoulder horizontal
abduction

C



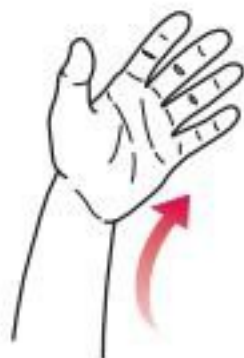Shoulder horizontal
adduction

D



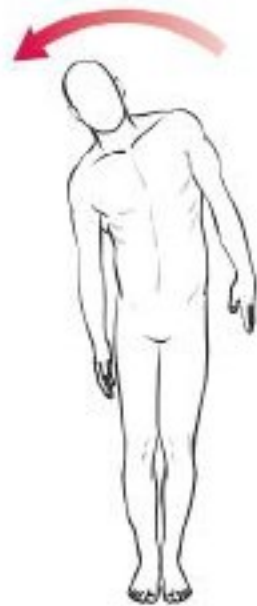Wrist radial deviation

E



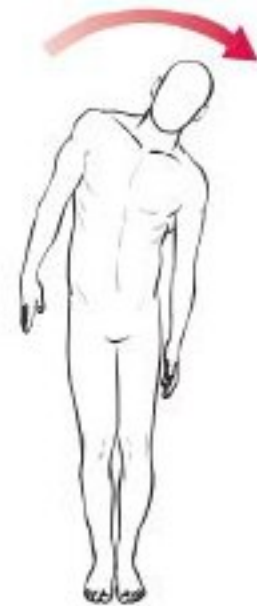Wrist ulnar deviation

F



Trunk right lateral bending

G



Trunk left lateral bending

H

Figure 1-9. Joint motions of abduction and adduction.

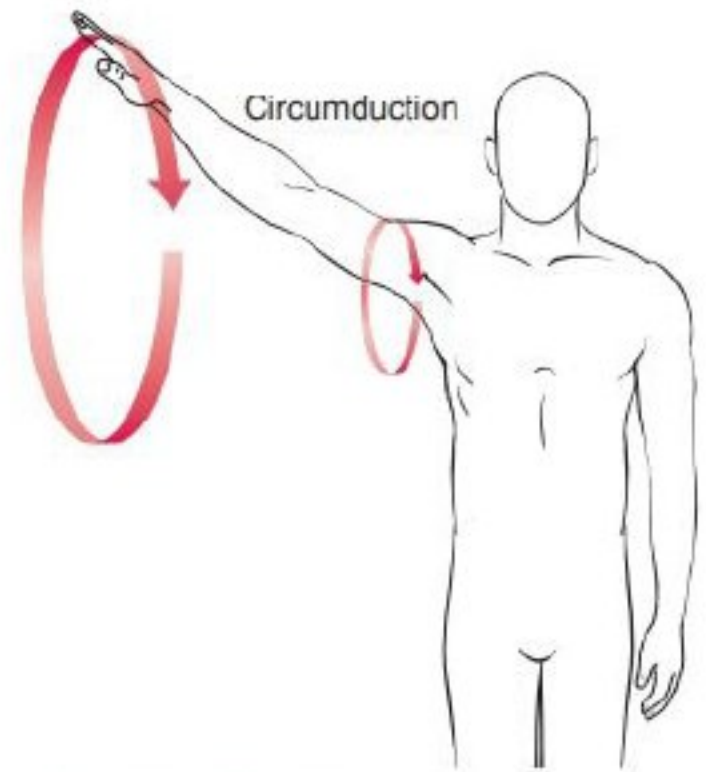


Figure 1-10. Circumduction motion.

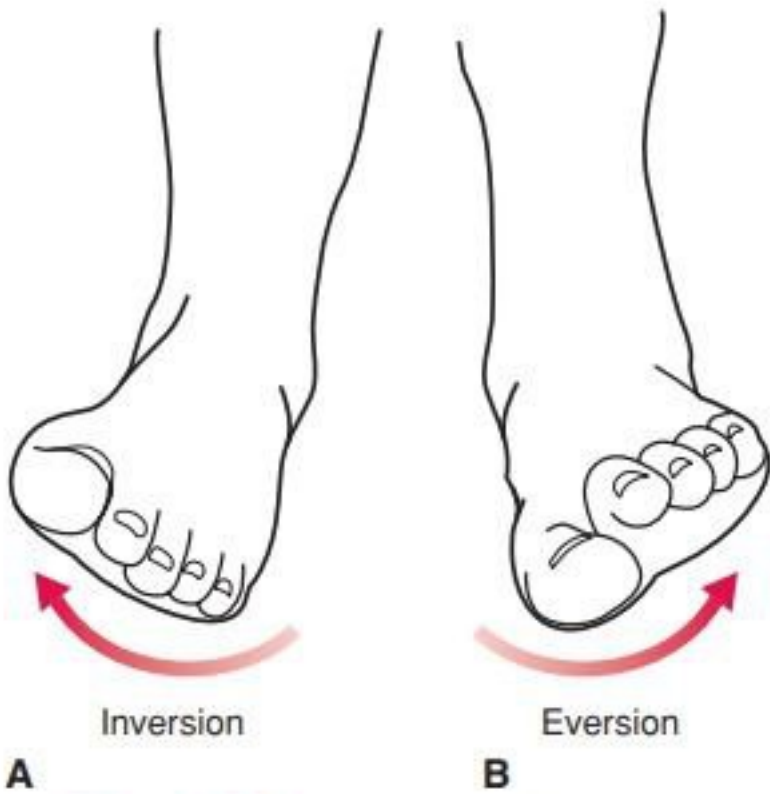
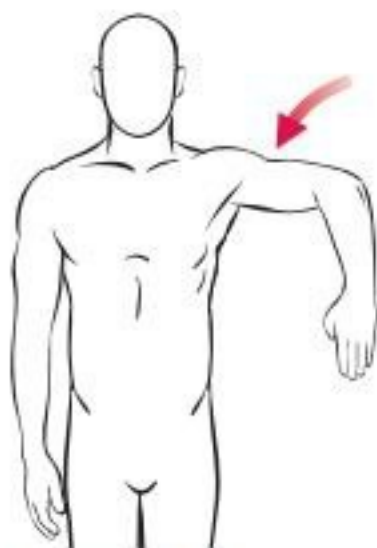
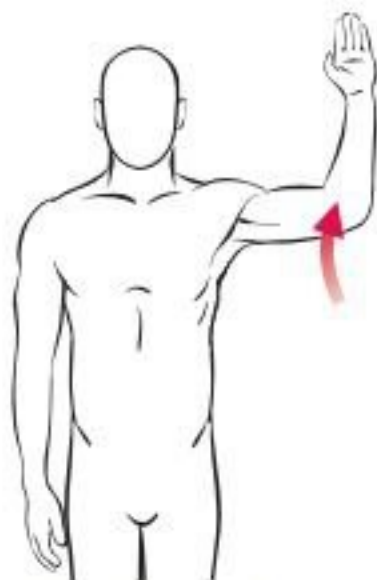

Figure 1-12. Inversion and eversion.



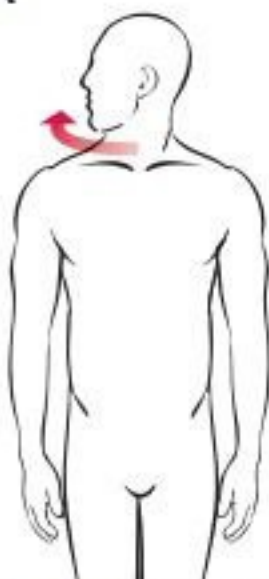Medial rotation

A



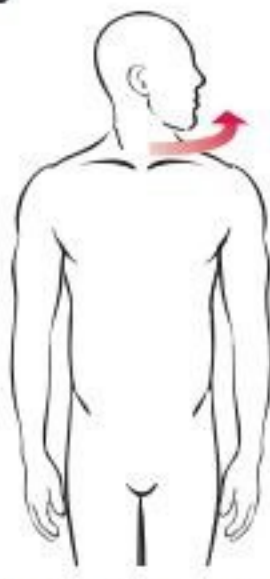Lateral rotation

B



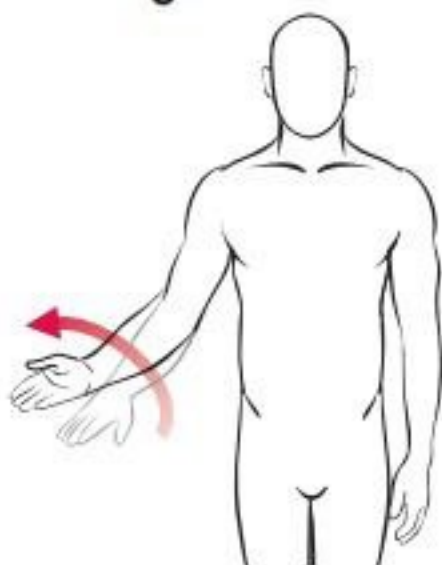
Neck rotation to right

C



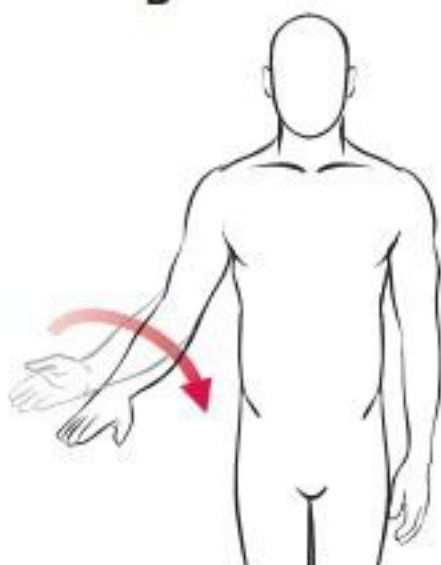
Neck rotation to left

D



Forearm supination

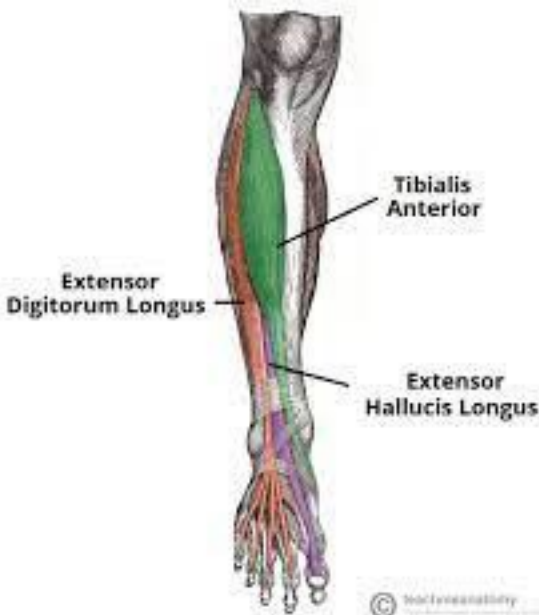
E



Forearm pronation

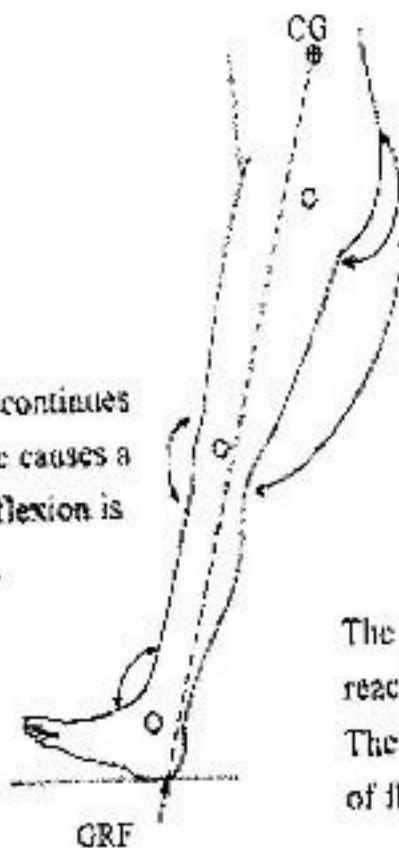
F

Figure 1-11. Joint rotation motions.



Shortly after heel strike

The knee is in 5° flexion and continues to flex. Ground reaction force causes a flexion moment. The rate of flexion is controlled by the quadriceps.



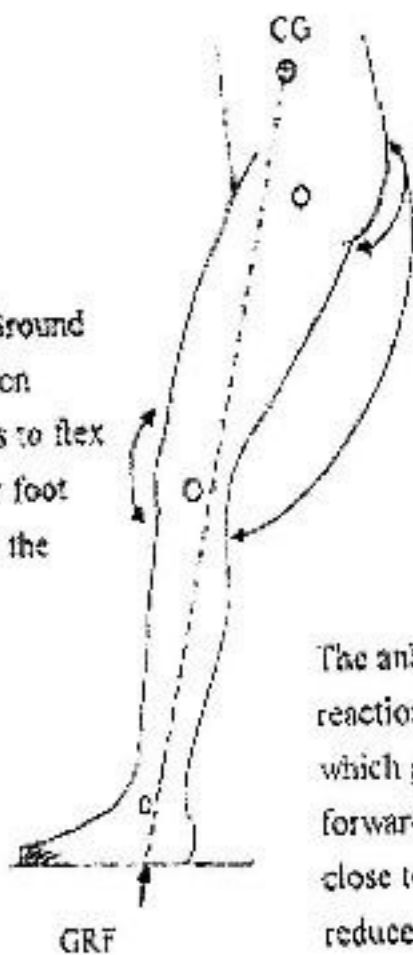
The hip is in 25° flexion. Ground reaction force causes a flexion moment. The gluteus maximus and hamstrings hold this position.

The ankle is in 5° plantarflexion. Ground reaction force causes plantarflexion moment. The ankle continues to plantarflex. The rate of flexion is controlled by the dorsiflexors.

Fig 10.11

Foot flat

The knee is in 15° flexion. Ground reaction force causes a flexion moment. The knee continues to flex until it reaches 20° just after foot flat. The quadriceps control the angle of flexion.



The hip is in 25° flexion. Ground reaction force causes a flexion moment. The hip begins to extend by the action of the gluteus maximus and hamstrings.

The ankle is in 10° plantarflexion. Ground reaction force causes plantarflexion moment which gets smaller as the body moves forward and the ground reaction force comes close to the ankle joint. The dorsiflexors reduce in action until there is no action.

Fig 10.12

10.5. CHARACTERISTICS OF GAIT

Vertical displacement occurs as the centre of gravity rises at mid-stance and falls at double support. The range of movement during vertical displacement is less than 50 mm.

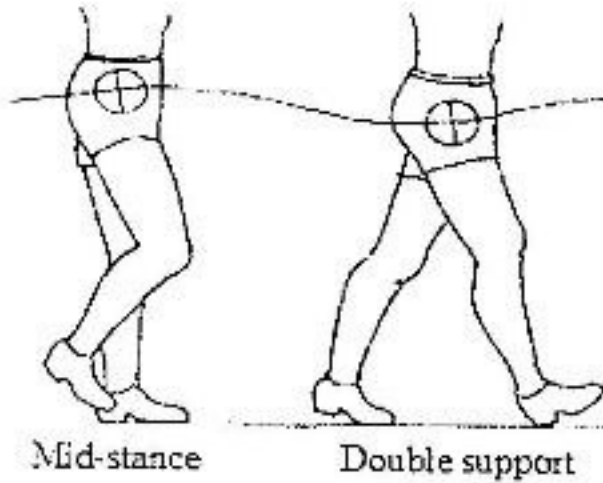


Fig. 10.5 Vertical displacement

Lateral displacement of the occurs as body sways in the direction of the leg that is on the ground. The CoG must be over the base of support. The range of movement that occurs during lateral displacement is less than 50 mm.

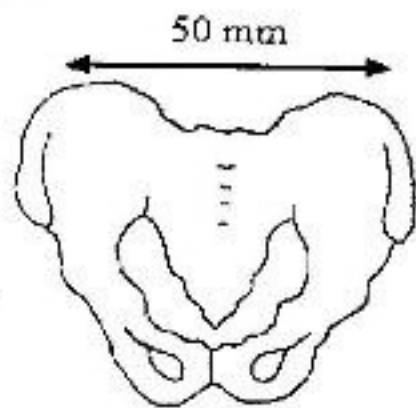


Fig. 10.6 Posterior view of pelvis showing lateral displacement

Pelvic dip occurs as the pelvis drops towards the side that is in swing phase. The size of the drop is about 5°.

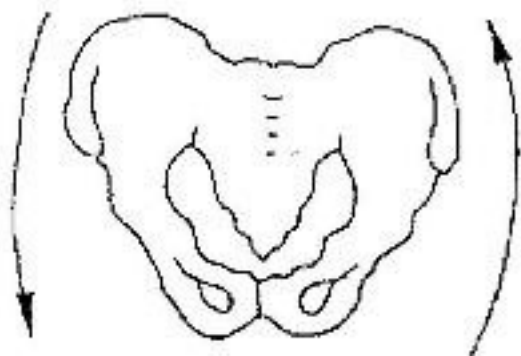


Fig. 10.7 Posterior view of pelvis

showing pelvic dip
Pelvic rotation occurs as the pelvis swings in an anterior-posterior direction. The pelvis swings anterior with the swinging leg. The range of movement is about 4°.

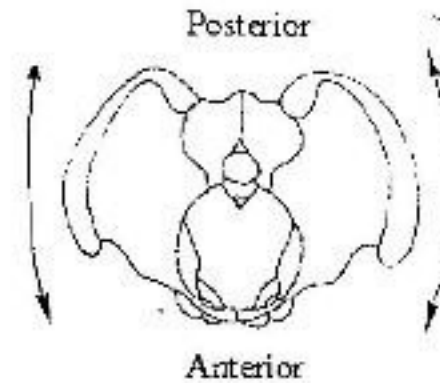


Fig. 10.8 Top view of pelvis showing pelvic rotation

Walking base is the distance between the mid-point of the heels. The usual distance is 50-100 mm.

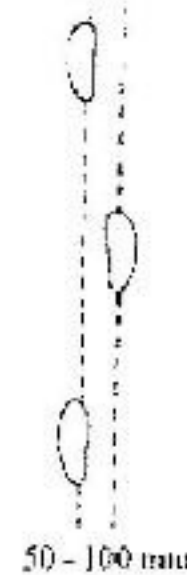


Fig. 10.9 Walking base

Double support is when both feet are on the ground. It occurs when one foot is at heel strike, and the other is between heel off and toe off. Double support occurs only in walking. The period of double support is reduced as the speed of walking increases. When there is no double support, a person is running.

Timing-At normal speed, 60% of the time is spent in stance phase, 40% in swing phase and 10% in double support.

Cadence is the number of steps taken per minute. 70 steps per minute is normal. 130 steps per minute is the fastest we can walk without running

Mid-swing

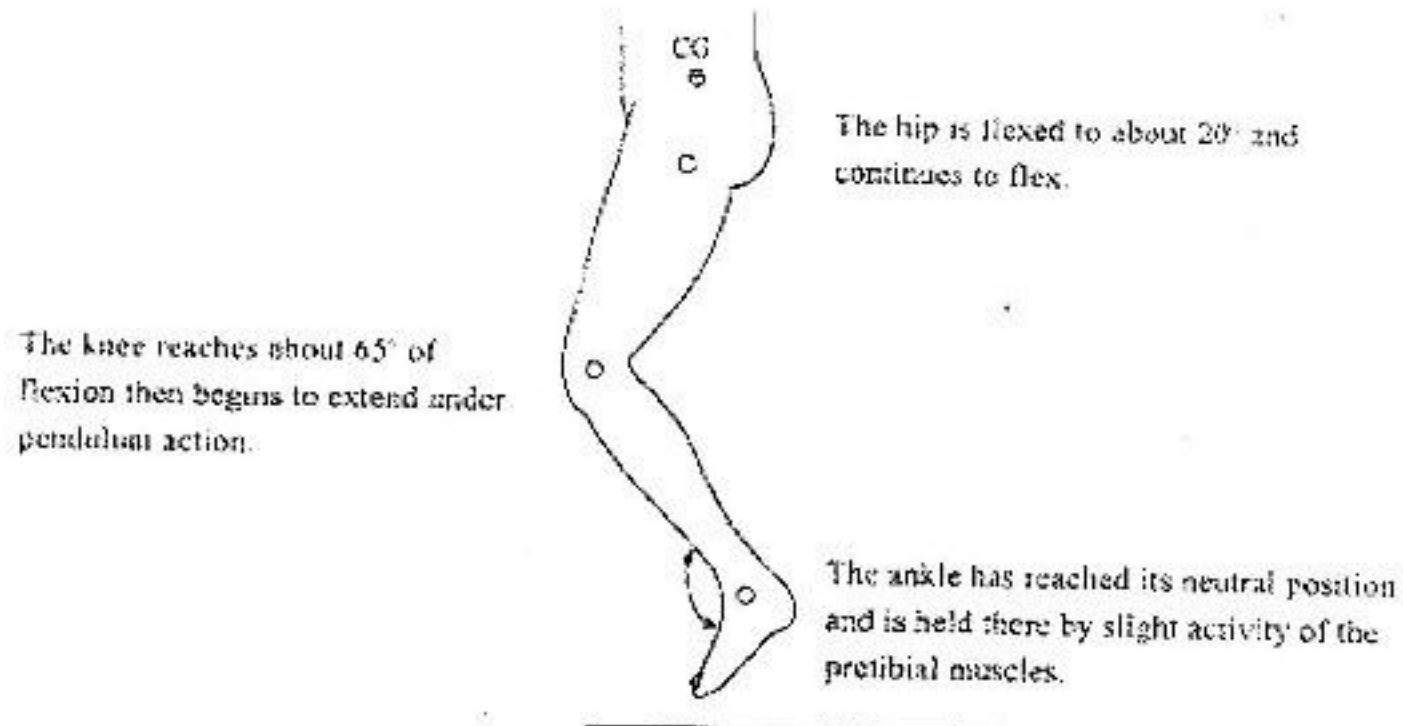


Fig 10.17

Deceleration

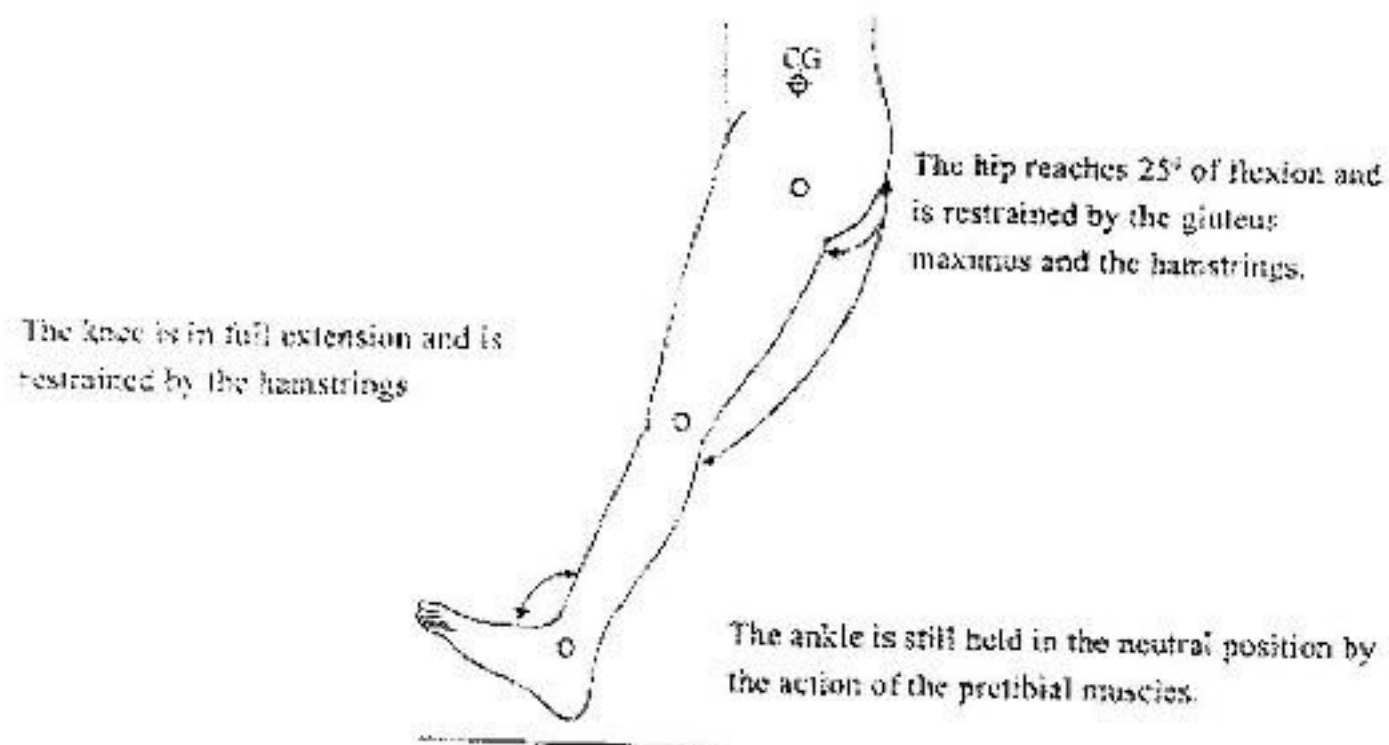


Fig 10.18

The hip, knee and ankle are now positioned for the following heel strike.
All the muscle groups that are necessary to counteract the ground reaction force are now active.

10.6 ANALYSIS OF NORMAL WALKING MOTION

The following pictures present one complete gait cycle showing the line of the ground reaction force, muscle action and joint position at specific times during the cycle

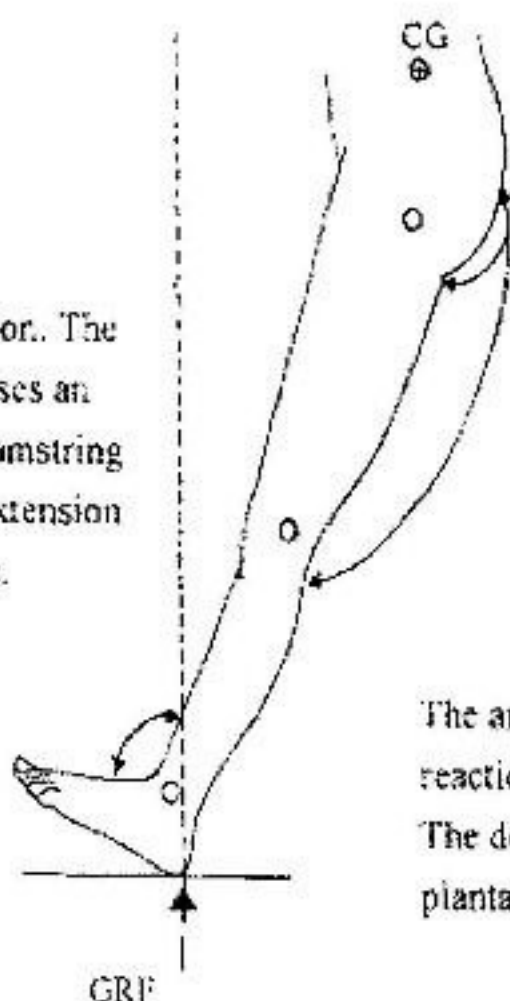
CG - Centre of gravity
GRF - Ground reaction force
↔ - Muscle action

Reaction

- Anterior to hip causing flexion moment
- Anterior to knee causing extension moment
- Posterior to ankle causing plantarflexion moment

Heel strike

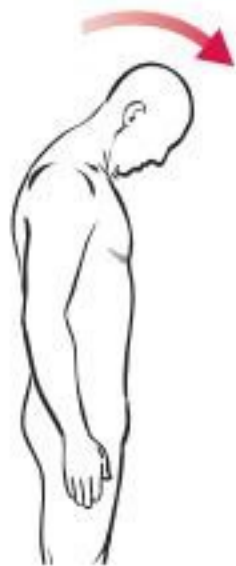The knee is in full extension. The ground reaction force causes an extension moment. The hamstring muscles prevent further extension and begin to flex the knee.



The hip is in 25° flexion. The ground reaction force causes a flexion moment. The gluteus maximus and hamstrings prevent further flexion.

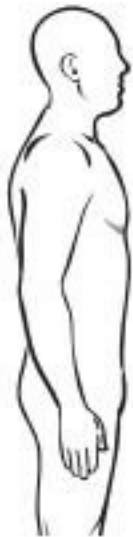The ankle is in neutral position. The ground reaction force causes plantarflexion moment. The dorsiflexors control the speed/rate of plantarflexion.

Fig 10.10



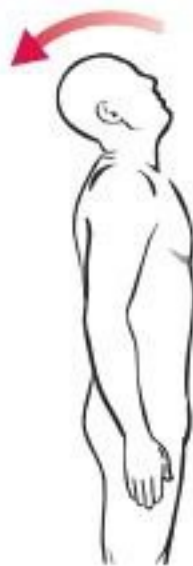Flexion

A



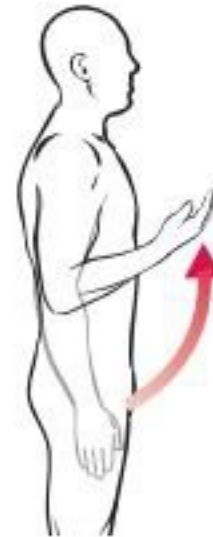Extension

B



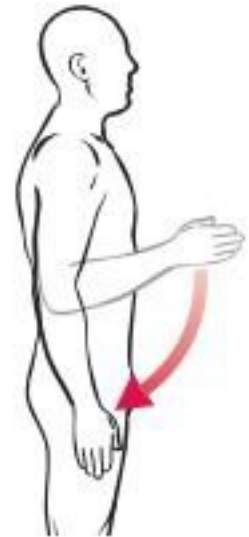Hyperextension

C



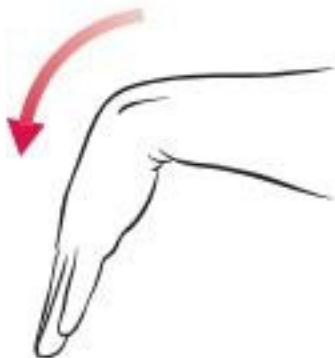Flexion

D



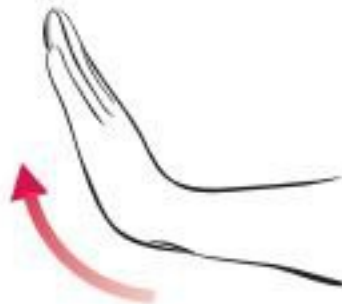
Extension

E



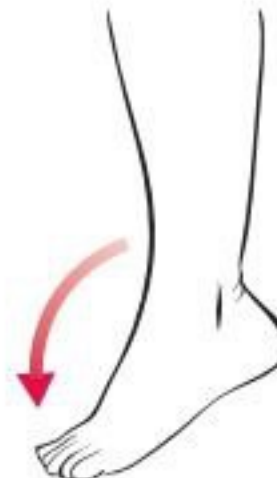Palmar flexion

F



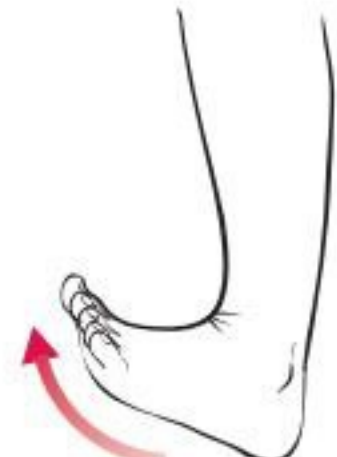
Dorsiflexion

G



Plantar flexion

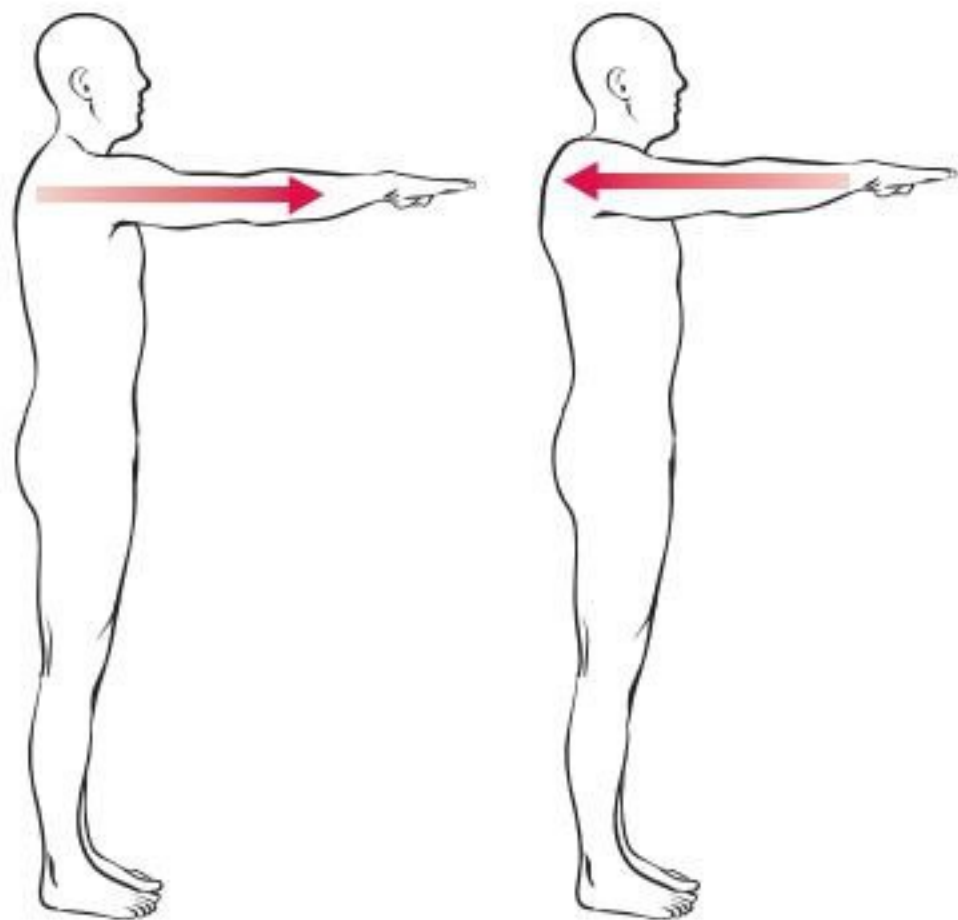
H



Dorsiflexion

I

Figure 1-8. Joint motions of flexion and extension.



A Protraction

B Retraction

Figure 1-13. Protraction and retraction.

Toe-off

The ground reaction force is not significant for all three joints as most of the weight is on the other leg.

The knee is in 40° of flexion. Flexion continues due to the small ground reaction force moment and the plantarflexion of the foot.

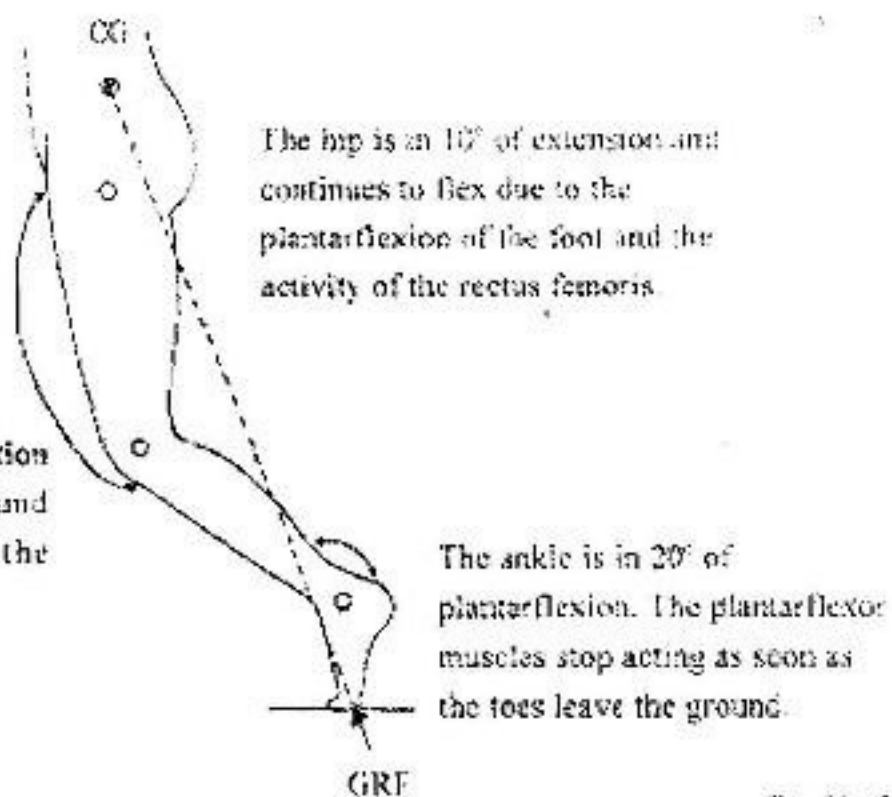


Fig 10.15

Acceleration

The knee is in 40° of flexion and continues to flex under pendulum action as the limb accelerates.

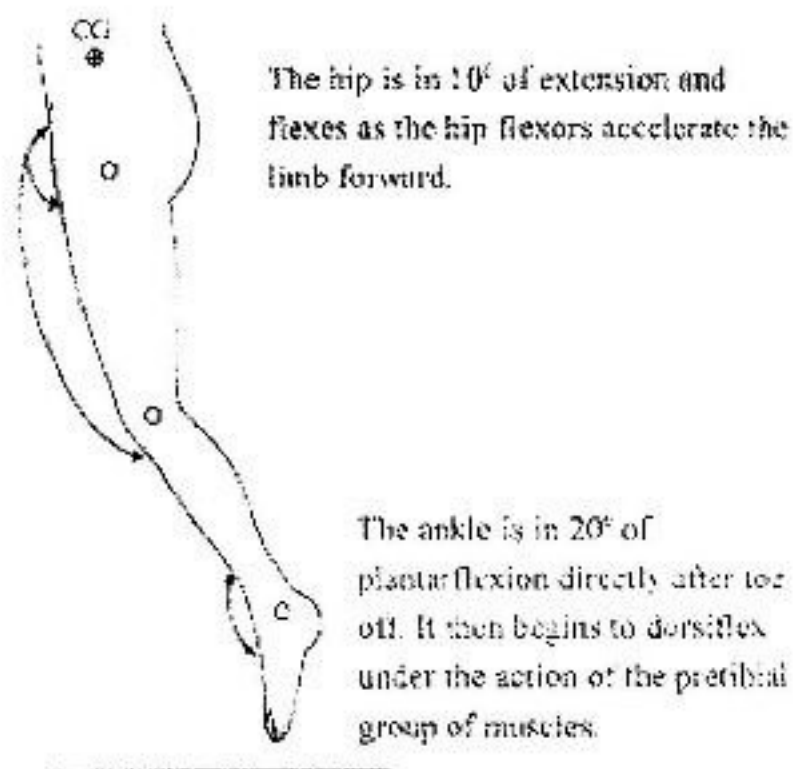


Fig 10.16

10.6 ANALYSIS OF NORMAL WALKING MOTION

The following pictures present one complete gait cycle showing the line of the ground reaction force, muscle action and joint position at specific times during the cycle


CG - Centre of gravity
GRF - Ground reaction force
↔ - Muscle action

Reaction

- Anterior to hip causing flexion moment
- Anterior to knee causing extension moment
- Posterior to ankle causing plantarflexion moment

Heel strike

The knee is in full extension. The ground reaction force causes an extension moment. The hamstring muscles prevent further extension and begin to flex the knee.



The hip is in 25° flexion. The ground reaction force causes a flexion moment. The gluteus maximus and hamstrings prevent further flexion.

The ankle is in neutral position. The ground reaction force causes plantarflexion moment. The dorsiflexors control the speed/rate of plantarflexion.

Fig 10.10

Types of Joints

Joint (articulation)— any point where two bones meet, whether or not the bones are movable at that interface.

Joints link the bones of the skeletal system, permit effective movement, and protect the softer organs.

Arthrology—science of joint structure, function, and dysfunction.

Joints classified according to the manner in which the bones are bound to each other.

Four major joint categories

- Bony joints
- Fibrous joints
- Cartilaginous joints
- Synovial joints

Bony joint

Bony joint—an immobile joint formed when the gap between two bones ossifies, and the bones become, in effect, a single bone.

- Examples:
 - Left and right mandibular bones in infants
 - Cranial sutures in elderly
 - Attachment of first rib and sternum with old age

Fibrous Joints

- Fibrous joint, synarthrosis, or synarthrodial joint

—adjacent bones are bound by collagen fibers that emerge from one bone and penetrate into the other.

Three kinds of fibrous joints

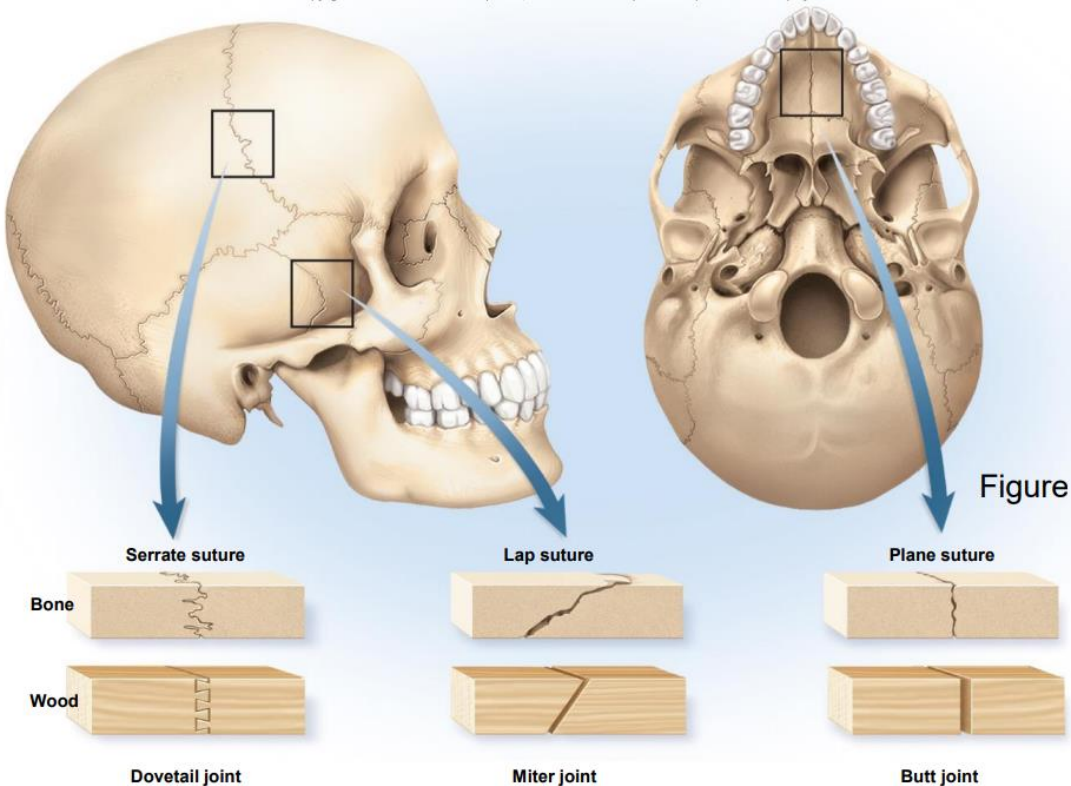
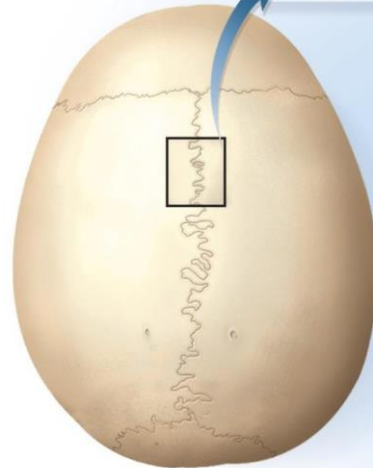
- Sutures
- Gomphoses
- Syndesmoses

Sutures—immobile or slightly mobile fibrous joints in which short collagen fibers bind the bones of the skull to each other •

Sutures can be classified as:

- **Serrate**: interlocking wavy lines • Coronal, sagittal, and lambdoid sutures.
- **Lap (squamous)**: overlapping beveled edges • Temporal and parietal bones.
- **Plane (butt)**: straight, nonoverlapping edges • Palatine processes of the maxillae.

Fibrous connective tissue



Gomphoses

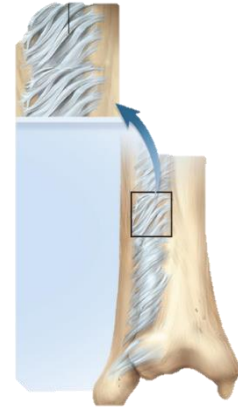
Gomphosis (fibrous joint)— attachment of a tooth to its socket.

Syndesmoses

—a fibrous joint at which two bones are bound by long collagen fibers.

Example of a very mobile syndesmosis: interosseus membrane joining radius to ulna allowing supination and pronation.

Example of a less mobile syndesmosis: joint between tibia to fibula.



Cartilaginous Joints

—two bones are linked by cartilage •

Two types of cartilaginous joints

– Synchondroses

– Symphyses

Synchondroses

• Synchondrosis—bones joined by hyaline cartilage

– Temporary joints in the epiphyseal plates in children. Bind epiphysis to diaphysis.

– First rib attachment to sternum. Other costal cartilages joined to sternum by synovial joints.

Symphyses

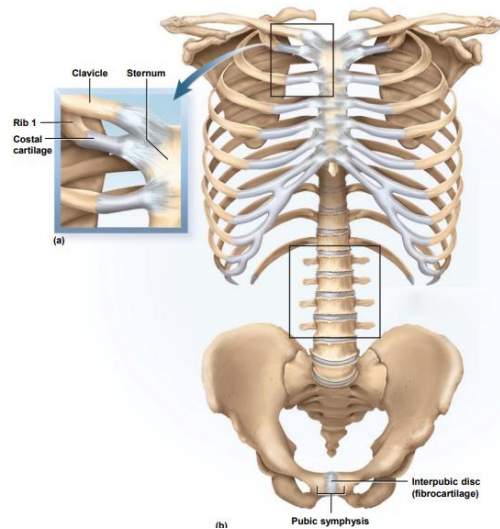
• Symphysis—two bones joined by fibrocartilage

– Pubic symphysis joins right and left pubic bones with interpubic disc

– Bodies of vertebrae joined by intervertebral discs.

-Only slight movements between adjacent vertebrae.

-Collective effect of all 23 discs gives spine considerable flexibility.



Synovial Joints

Synovial joints are a type of joint with an articular capsule, consisting of an outer fibrous layer and an inner synovial membrane, which surrounds a fluid-filled synovial cavity. The articulating surfaces are covered by hyaline cartilage, designed to slide with little friction and to absorb compressive forces.

These joints are termed diarthroses, meaning they are freely mobile. They are more mobile than cartilaginous joints and fibrous joints.

Synovial joints are the most common type of joint in the body.

Most likely to develop painful dysfunction • Most important joints for physical and occupational therapists, athletic coaches, nurses, and fitness trainers.

Their mobility makes them important to quality of life.

A key structural characteristic for a synovial joint that is not seen at fibrous or cartilaginous joints is the presence of a joint cavity. The joint cavity contains synovial fluid, secreted by the synovial membrane, which lines the articular capsule. This fluid-filled space is the site at which the articulating surfaces of the bones contact each other. Hyaline cartilage forms the articular cartilage, covering the entire articulating surface of each bone. The articular cartilage and the synovial membrane are continuous.

Synovial joints are often further classified by the type of movements they permit.

General Anatomy of Synovial Joints

Articular cartilage—layer of hyaline cartilage that covers the facing surfaces of two bones.

– Usually 2 or 3 mm thick.

Joint (articular) cavity—separates articular surfaces.

Synovial fluid—slippery lubricant in joint cavity

- Rich in albumin and hyaluronic acid
- Gives it a viscous, slippery texture like raw egg whites
- Nourishes articular cartilage and removes waste
- Makes movement of synovial joints almost friction free.

Features of all Synovial Joints

- Articular capsule with synovial membrane
- Synovial cavity containing synovial fluid
- Hyaline articular cartilage: acts like a Teflon® coating over the bone surface, allowing the articulating bones to move smoothly against each other without damaging the underlying bone tissue.

Types of Synovial Joints

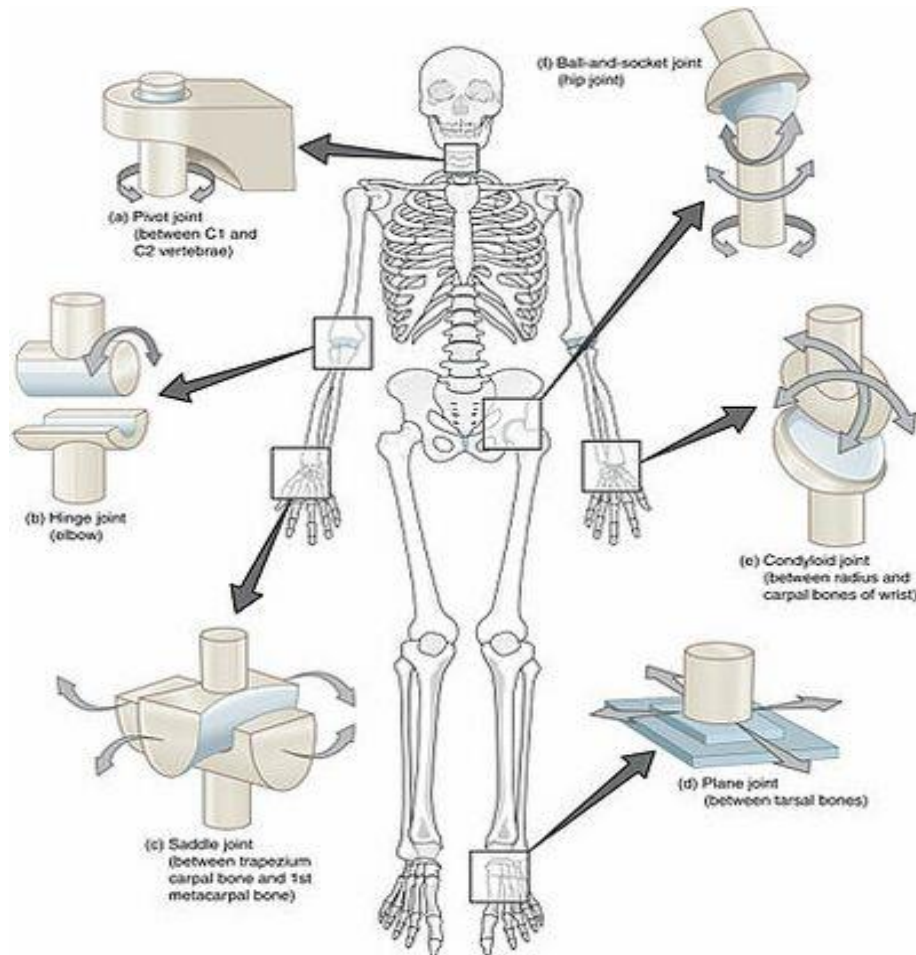
There are six such classifications:

hinge (elbow),
saddle (carpometacarpal joint),
planar (acromioclavicular joint),
pivot (atlantoaxial joint),
condyloid (metacarpophalangeal joint),
ball and socket (hip joint).

Image: Types of Synovial Joints:

The six types of synovial joints allow the body to move in a variety of ways.

(a) Pivot joints allow for rotation around an axis, such as between the first and second cervical vertebrae, which allows for side-to-side rotation of the head.



(b) The hinge joint of the elbow works like a door hinge.

(c) The articulation between the trapezium carpal bone and the first metacarpal bone at the base of the thumb is a saddle joint.

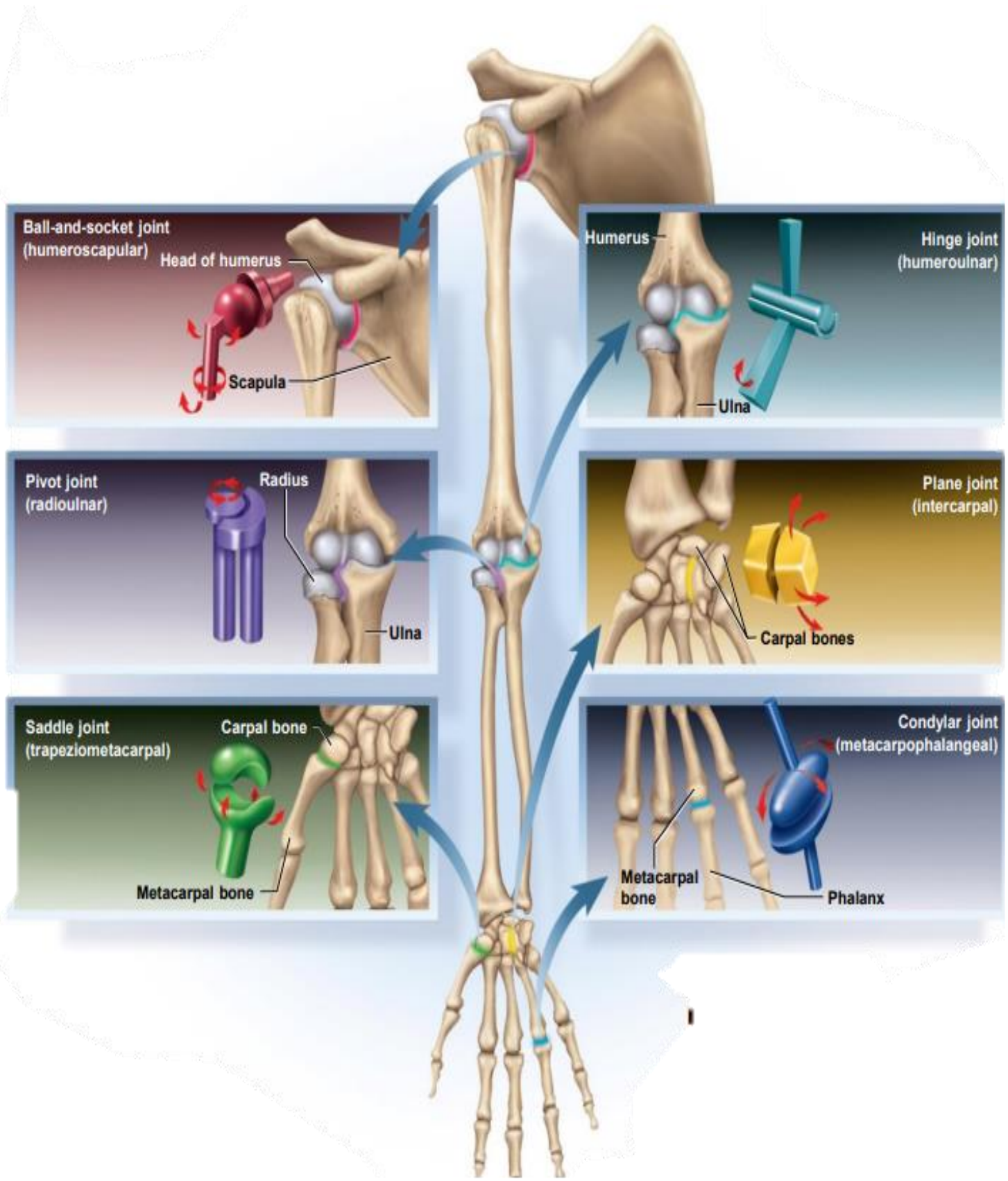
(d) Plane joints, such as those between the tarsal bones of the foot, allow for limited gliding movements between bones.

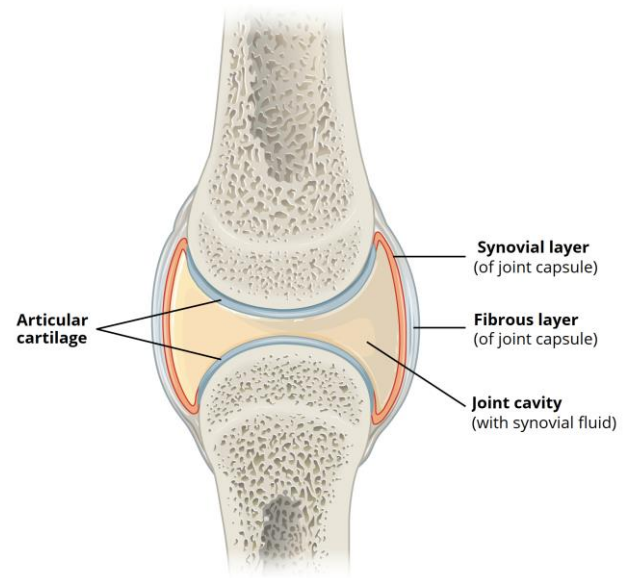
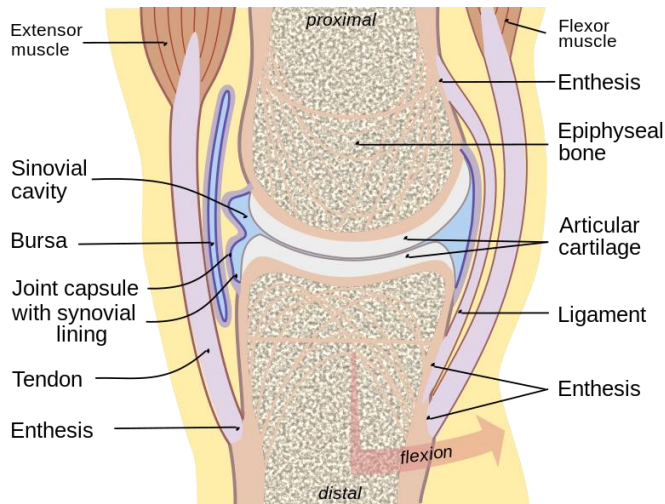
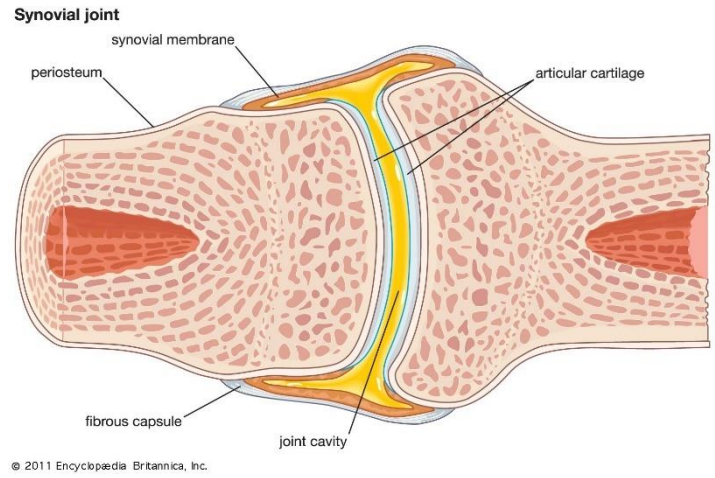
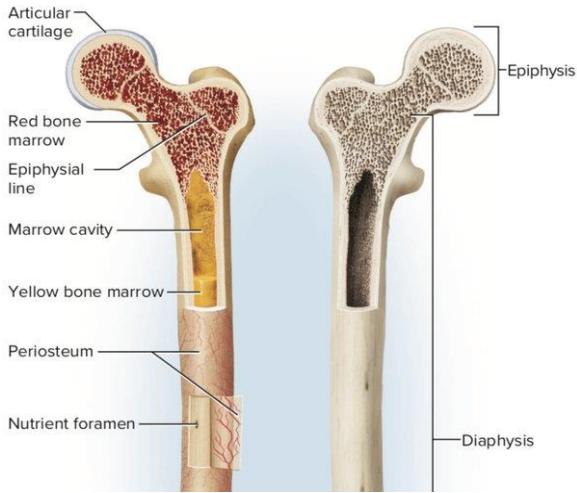
(e) The radiocarpal joint of the wrist is a condyloid joint.

(f) The hip and shoulder joints are the only ball-and-socket joints of the body.

The six types of synovial joints are:

1. **Plane Joints:** Multiaxial joint, the articular surfaces are essentially flat, and they allow only short nonaxial gliding movements. Examples are the gliding joints of the intercarpal and intertarsal joints, and the joints between vertebral articular. Gliding does not involve rotation around any axis.
2. **Hinge Joints:** Uniaxial Joint, the cylindrical end of one bone conforms to a trough-shaped surface on another. Motion is along a single plane and resembles that of a mechanical hinge. Uniaxial hinge joints permit flexion and extension only, typified by bending and straightening the elbow and interphalangeal joints.
3. **Pivot Joints:** Uniaxial Joint, the rounded end of one bone conforms to a "sleeve" ring composed of bone (and possibly ligaments) of another. The only movement allowed is uniaxial rotation of one bone around its own long axis. An example is the joint between the atlas and dens of the axis, which allows you to move your head from side to side to indicate "no." Another is the proximal radioulnar joint, where the head of the radius rotates within a ringlike ligament secured to the ulna.
4. **Condylod (ellipsoidal) Joints:** Biaxial joints, The oval articular surface of one bone fits into a complementary depression in another. The important characteristic is that both articulating surfaces are oval. The biaxial condylod joints permit all angular motions, that is, flexion and extension, abduction and adduction, and circumduction. The radiocarpal (wrist) joints and the metacarpophalangeal (knuckle) joints are typical condylod joints.
5. **Saddle Joints:** Biaxial Joints, resemble condylod joints, but they allow greater freedom of movement. Each articular surface has both concave and convex areas; that is, it is shaped like a saddle. The articular surfaces then fit together, concave to convex surfaces. The most clear-cut examples of saddle joints in the body are the carpometacarpal joints of the thumbs, and the movements allowed by these joints are clearly demonstrated by twiddling your thumbs.
6. **Ball-and-Socket Joints:** Multiaxial joint, In ball-and-socket joints, the spherical or hemispherical head of one bone articulates with the cuplike socket of another. These joints are multiaxial and the most freely moving synovial joints. Universal movement is allowed (that is, in all axes and planes, including rotation). The shoulder and hip joints are the only examples.



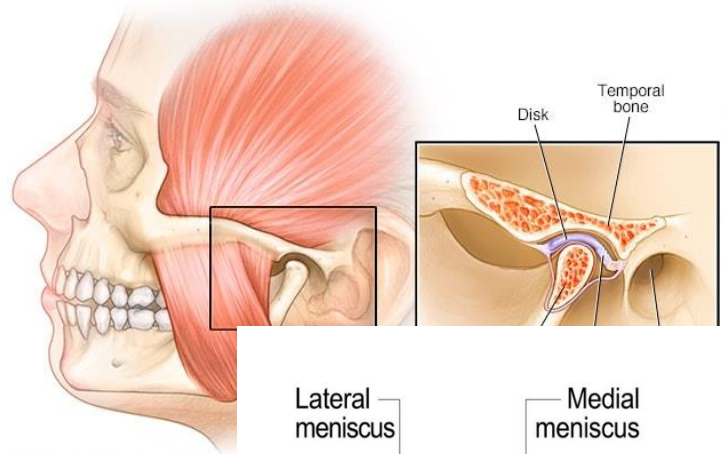


articular capsule—connective tissue that encloses the cavity and retains the fluid.

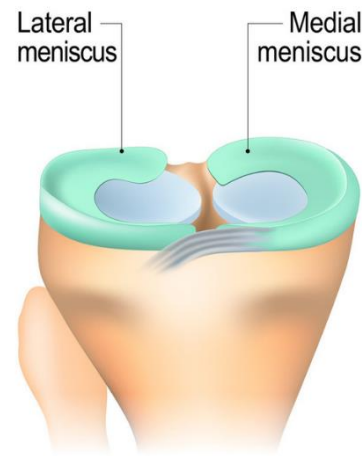
Outer fibrous capsule: continuous with periosteum of adjoining bones.

Inner cellular synovial membrane: composed mainly of fibroblast-like cells that secrete synovial fluid and macrophages that remove debris from the joint cavity.

- Articular disc forms a pad between articulating bones that crosses the entire joint capsule. Example found in temporomandibular joint.



- Meniscus: moon-shaped cartilage in knee; in each knee, menisci extend inward from the left and right. These cartilages absorb shock and pressure. Guide bones across each other and improve their fit together. Stabilize the joints, reducing the chance of dislocation.



Normal meniscus

Accessory structures

Tendon: strip of collagenous tissue attaching muscle to bone

Ligament: strip of collagenous tissue attaching one bone to another

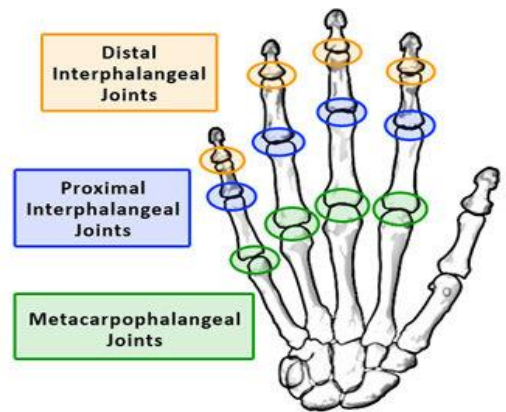
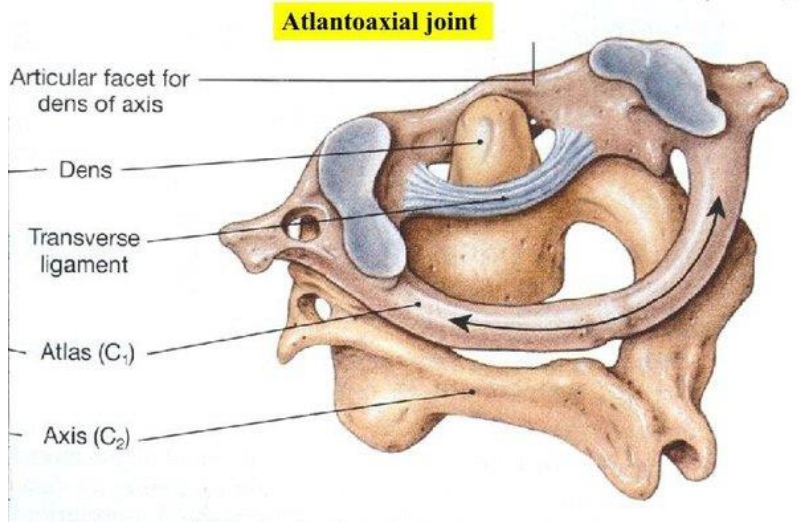
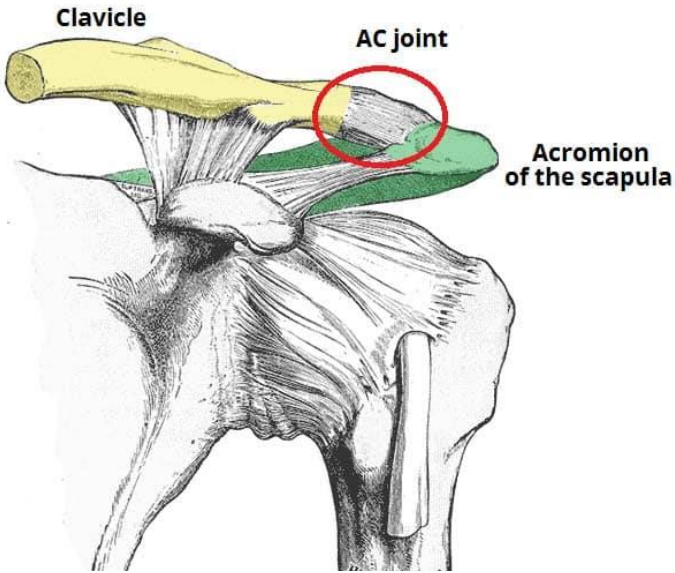
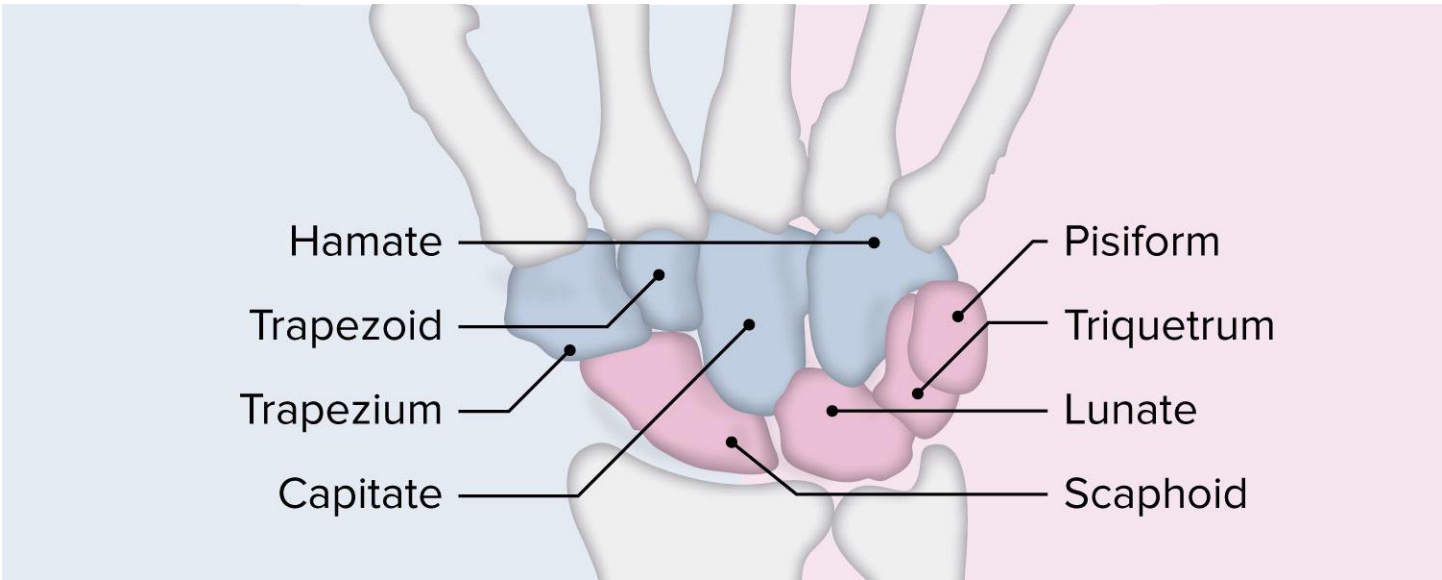
Bursa: fibrous sac filled with synovial fluid, located between muscles, where tendons pass over bone, or between bone and skin.

Cushions muscles, helps tendons slide more easily over joints, modifies direction of tendon pull.

Tendon sheath: elongated cylindrical bursa wrapped around a tendon.

In hand and foot.

Bursa is a connective tissue sac containing lubricating fluid that prevents friction between adjacent structures, such as skin and bone, tendons and bone, or between muscles.



The shoulder complex

Introduction

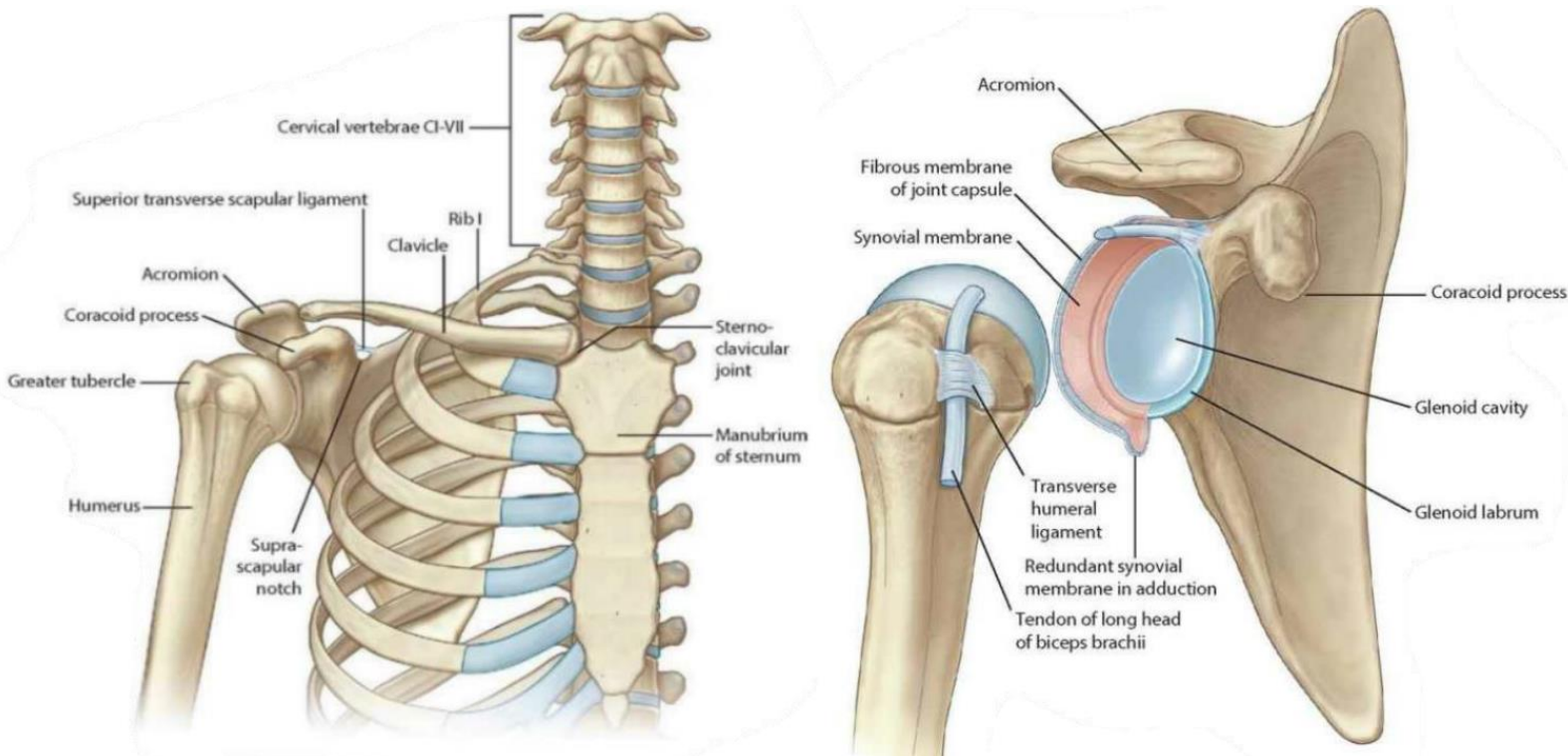
The glenohumeral joint allows the arm to perform countless and varied movements. This diversity generates a on the joint, which, in turn, tends to suffer dislocations, affecting 1-2% of the population. In addition, individuals who frequently perform activities such as swimming, baseball, tennis, among others, are more likely to have shoulder injuries due to the stress to which their joints and muscles are subjected.

The shoulder has one of the most complex joints of the Human body (glenohumeral joint), enabling a wide range of different movements (including flexion, extension, abduction, adduction, external rotation and internal rotation). This joint presents a compromise between stability and mobility, which requires the interplay between the structures that compose it. Thus, in case any of the structures gets injured, it can lead to weakness, pain or instability.

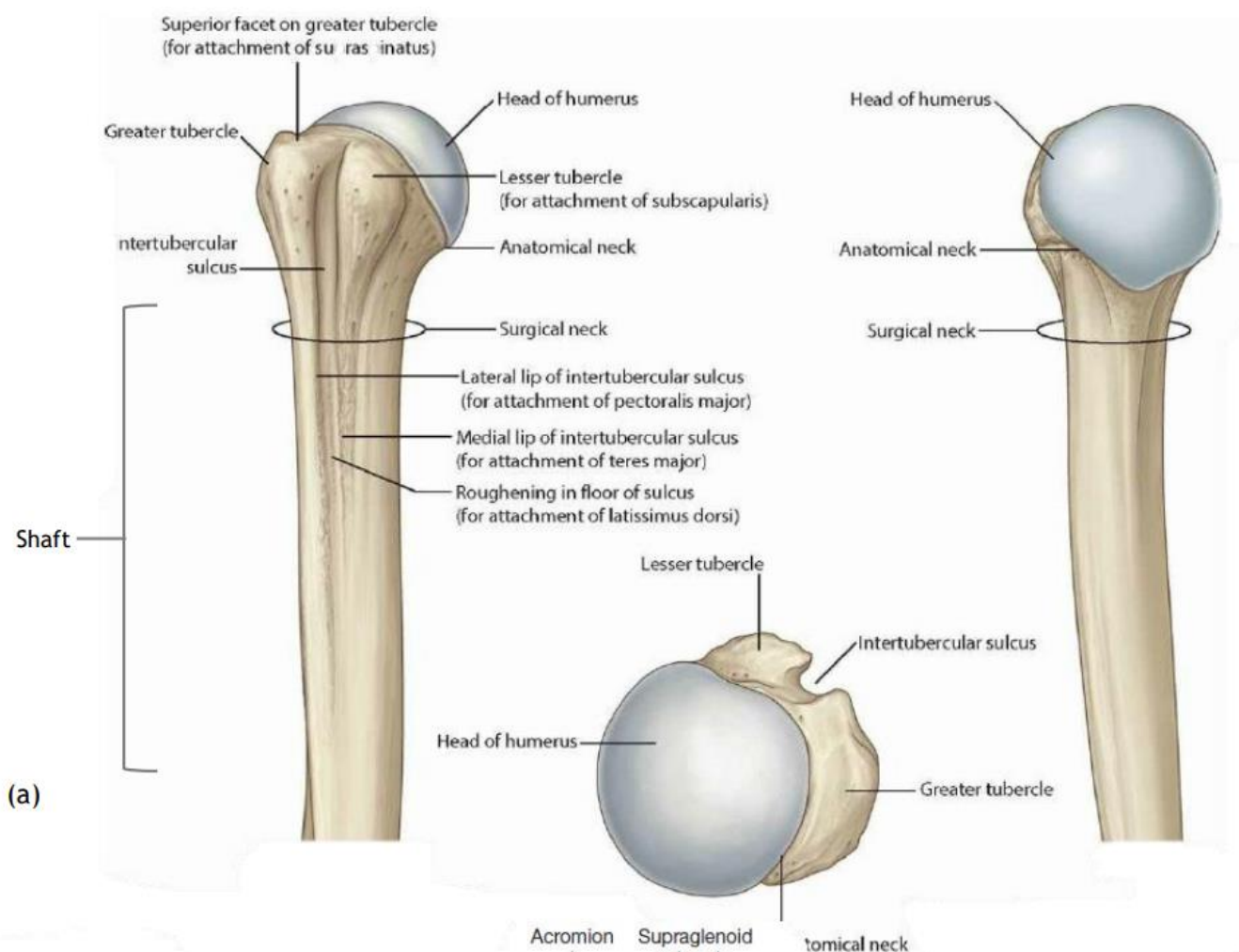
Shoulder anatomy

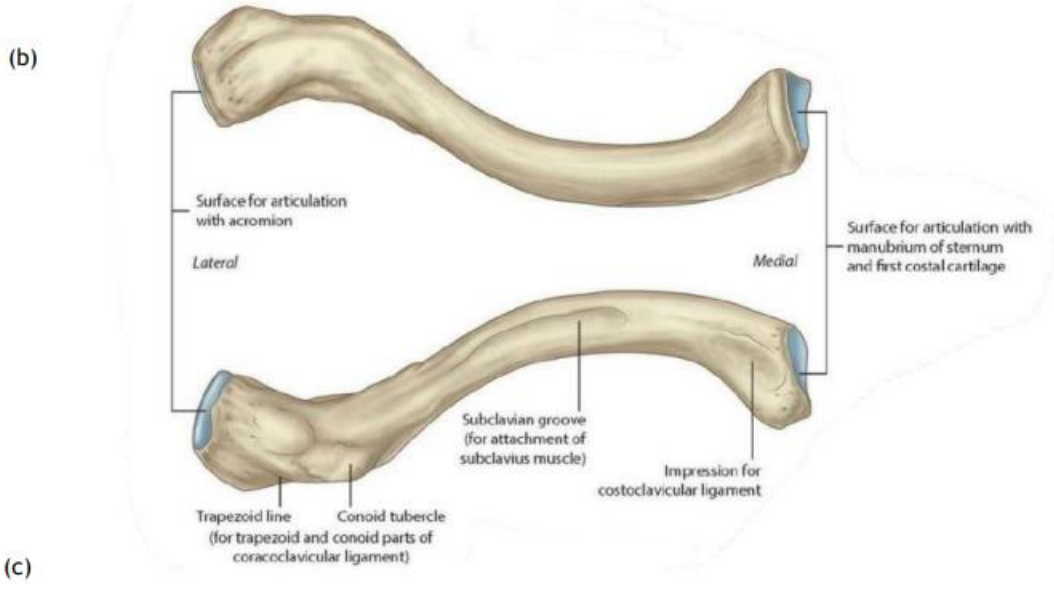
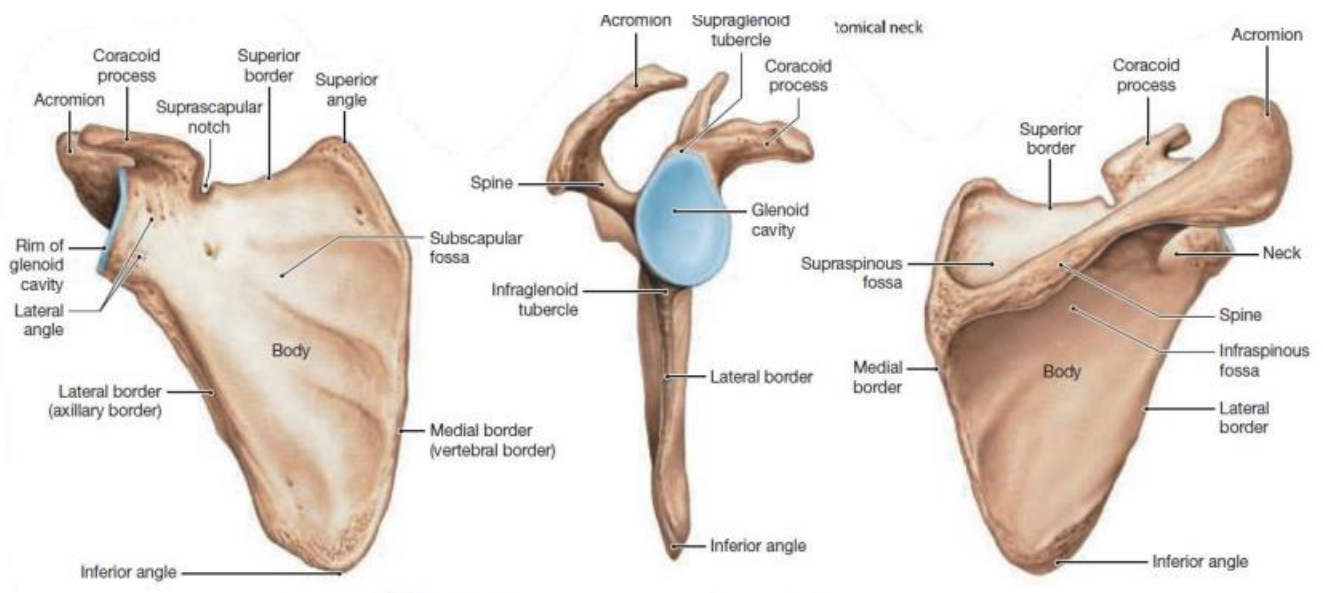
Bones

The bones of the shoulder complex include the scapula, the humerus and the clavicle. The contact between the scapula and the humerus is promoted by the glenoid, as shown in figure.



The humerus is the largest bone of the upper limb and it is divided into the head, anatomical neck, surgical neck and shaft, as shown in figure (a). The humeral head has a 25°-35° retroversion in relation to the elbow condyles, it is described as a third of a sphere with a radius of approximately 25 mm, and it is the section of the humerus that articulates with the glenoid. The anatomical neck is where the capsule is attached, while the surgical neck marks the metaphysis of the bone. Besides, the greater and the lesser tubercles are sites for muscle attachment, and the intertubercular sulcus (which separates the 2 tubercles) is where the tendon of the biceps brachii is inserted. The scapula is one of the most important bones since it plays a crucial role in normal shoulder function. It has three important landmarks, which are the acromion, the coracoid process and the spine of the scapula, as shown in figure (b). It is suspended on the axial skeleton by sternoclavicular ligaments, axioscapular muscles (which include the trapezius, rhomboids, serratus anterior and elevator scapulae), coracoclavicular ligaments, atmospheric pressure and fascia [30] and it is positioned obliquely between the frontal and sagittal planes. It is a site for muscle attachment, a link in proximal to distal sequencing of the kinetic chain and it elevates the acromion to reduce impingement and coracoacromial arch compression while executing actions such as throwing.



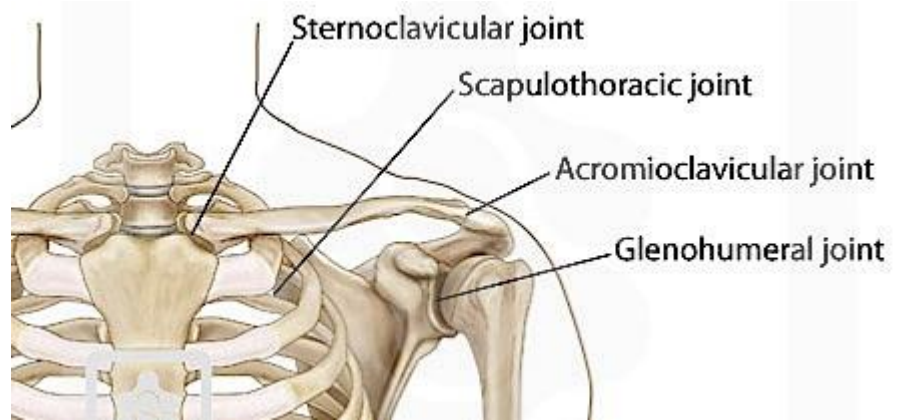


The clavicle is a long-curved bone, as shown in figure (c), which articulates medially with the sternal manubrium and laterally with the scapula acromion.

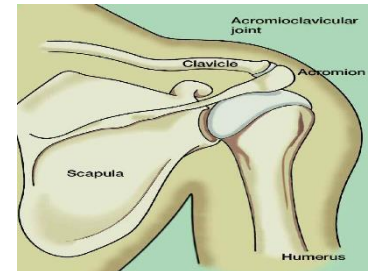
Joints

The shoulder complex is formed by four joints:

Acromioclavicular
sternoclavicular
scapulothoracic
glenohumeral.



The **acromioclavicular** joint is a plane synovial joint that joins the acromion of the scapula to the end of the clavicle, as shown in figure, and it contributes to the range of rotation of the scapula. It is formed by the articular disc and the acromioclavicular ligament.



The **sternoclavicular** joint is a plane synovial joint, and it articulates the clavicle to the manubrium of the sternum, as shown in figure. This joint is formed by the articular disc and the anterior and posterior sternoclavicular ligaments. It contributes to the performance of several shoulder movements, such as shrugging, elevating the arm above the head and moving the shoulders back and forth.

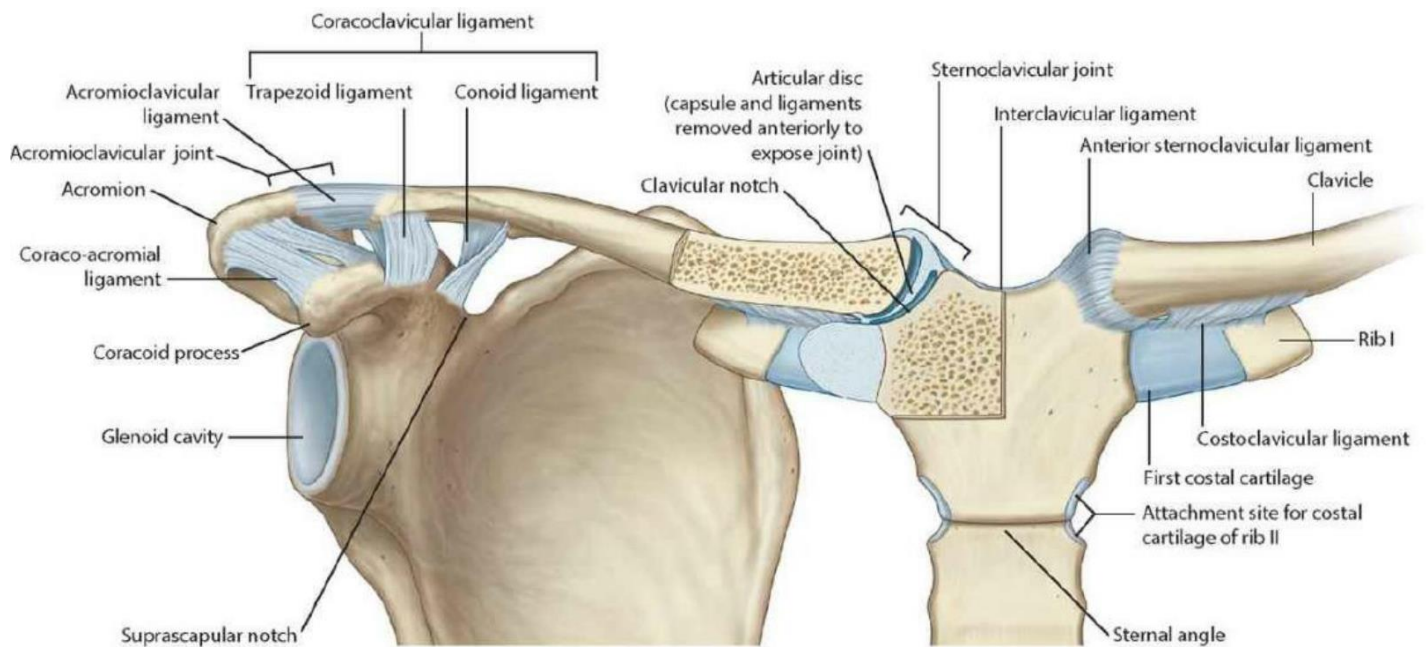
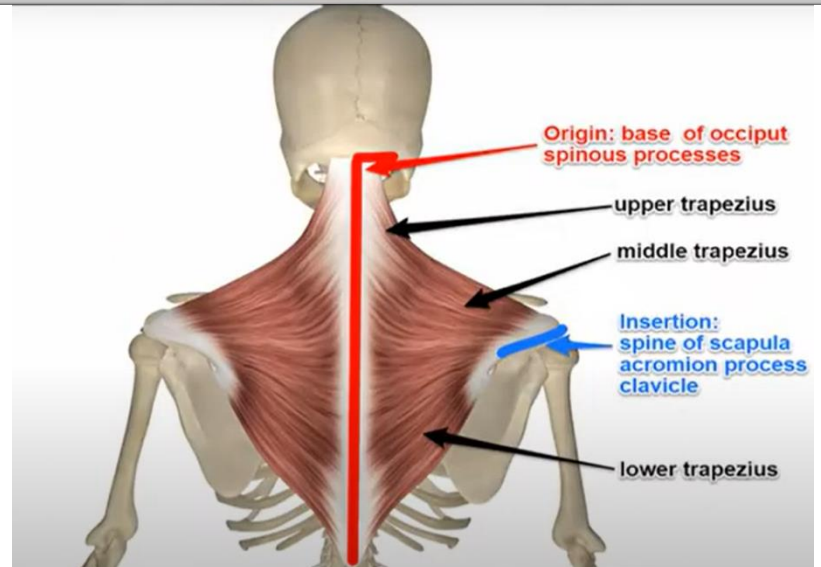
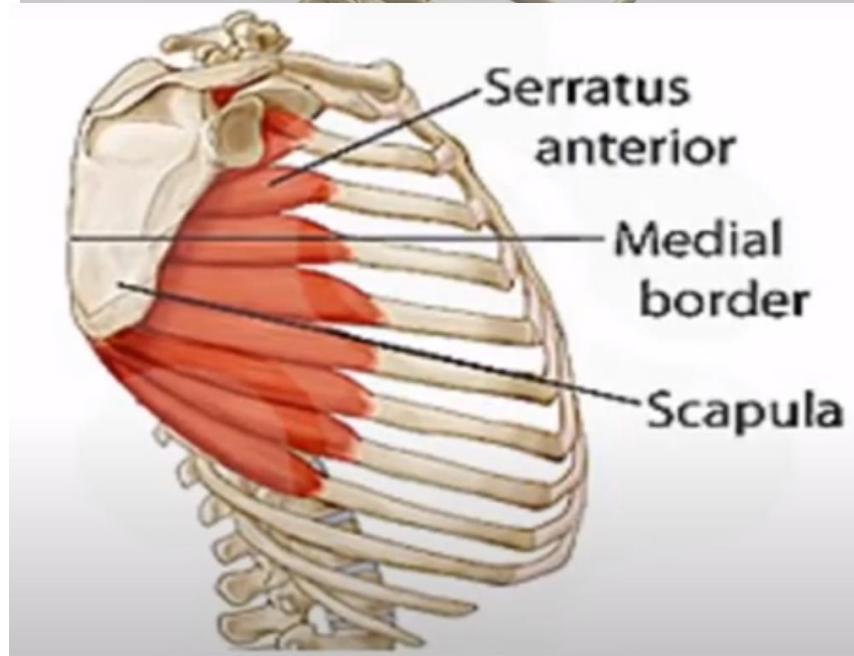
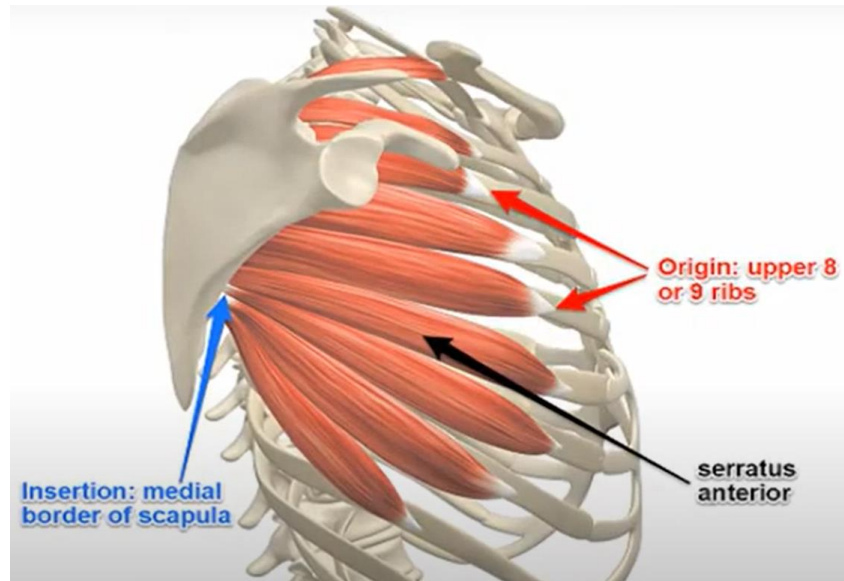


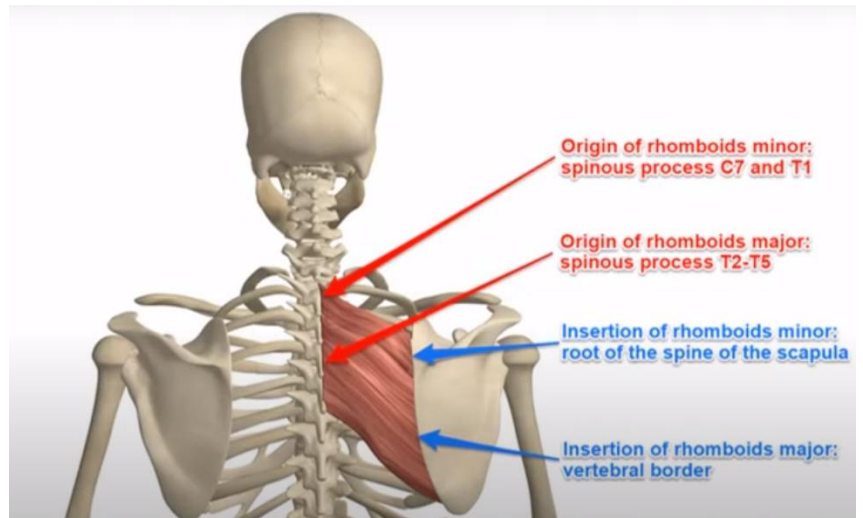
Figure - Anterior view of the scapula and clavicle and respective ligaments and joints

Before describing the glenohumeral and scapulothoracic joints, it is important to note that the combination of the movement of these two joints in a 2:1 ratio is essential to perform abduction of the arm. For instance, if the arm abducts 90°, the glenohumeral joint is responsible for rotating 60°, while the scapulothoracic joint rotates 30°.

The **scapulothoracic** joint connects the scapula to the thorax, as shown in figure, and consequently it allows the movement of the scapula against the rib cage.



The **glenohumeral** joint is a ball-and-socket synovial joint, that articulates the glenoid and the humeral head, as shown in figure. Since the humeral head has a larger surface than the glenoid, only 25% to 30% of the humeral head is in contact with it. Furthermore, the articular face of the humerus has a spherical shape, as mentioned above, while the glenoid fossa is pear-shaped (with a vertical diameter about 75% of the humeral head and a transverse



diameter of 55% of the humeral head). These aspects cause the surfaces to be incongruent, and the joint loose-packed. In contrast, the articular cartilage of the glenoid (which consists of hyaline cartilage) is thickest in the periphery and thinnest in the center, opposite to the articular cartilage of the humeral head, favoring the fitting of the humerus into the glenoid. This joint is characterized for being more suited for mobility than stability, which in turn leads to it being more commonly dislocated. For this reason, the presence of static and dynamic stabilizers is essential. The static stabilizers include the bones, the glenoid labrum, the glenohumeral ligaments along with the joint capsule and the negative intra-articular pressure, while the dynamic include the rotator cuff muscles and other surrounding muscles that compress the humeral head into the glenoid. In addition, this joint also includes the coracohumeral ligament and the transverse humeral ligament.

The negative intra-articular pressure, generated by the sealed capsule with limited volume, creates a vacuum effect, which helps in preventing excessive translation. The synovial fluid inside the capsule allows the interaction between the humeral head and the glenoid to occur smoothly and without pain, providing the cohesion and adhesion effect, where adhesion is described as the fluid retention on a surface and cohesion is the bonding of two surfaces by fluid.

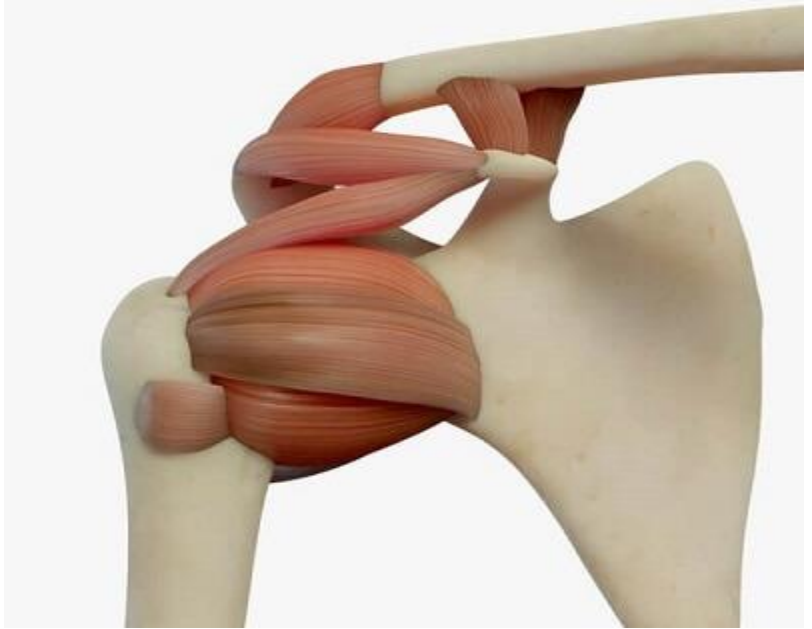
Shoulder Ligaments

The shoulder ligaments are tough, elastic bands of connective tissues.

They connect bone to bone, support the shoulder joints and limit their movement, playing a vital role in passive shoulder stability.

The shoulder is made up of a number of different joints, and each of these joints are supported by a number of ligaments.

The shoulder ligaments help to reinforce and support the joint capsules, draw the bones together and resist dislocation.



Ligaments are made up of tough bands of fibrous connective tissue that contain strong collagen fibers. As we age, the collagen fibers in ligaments change from being wavy to being straight, which makes them less elastic and stiffer, and therefore more prone to damage.

Here we will look at the different shoulder ligaments, where they are, how they work, why they are so important and what can go wrong.

Shoulder Joint Ligaments

The shoulder ligaments work together to connect the humerus (upper arm bone), scapula (shoulder blade), clavicle (collar bone) and sternum (breast bone) through a series of joints:

- **Glenohumeral Joint:** a ball and socket joint between the humeral head and the glenoid fossa (part of the scapula). More commonly referred to as the shoulder joint
- **Acromioclavicular Joint:** the joint between the acromion (part of the shoulder blade) and the clavicle
- **Sternoclavicular Joint:** the joint between the clavicle and the sternum

Any movement of the arm, particularly above head height involves movement at each of these joints and the shoulder ligaments play an important role in controlling the movement.

So let's look at the nine main shoulder ligaments, where they are and what they do.

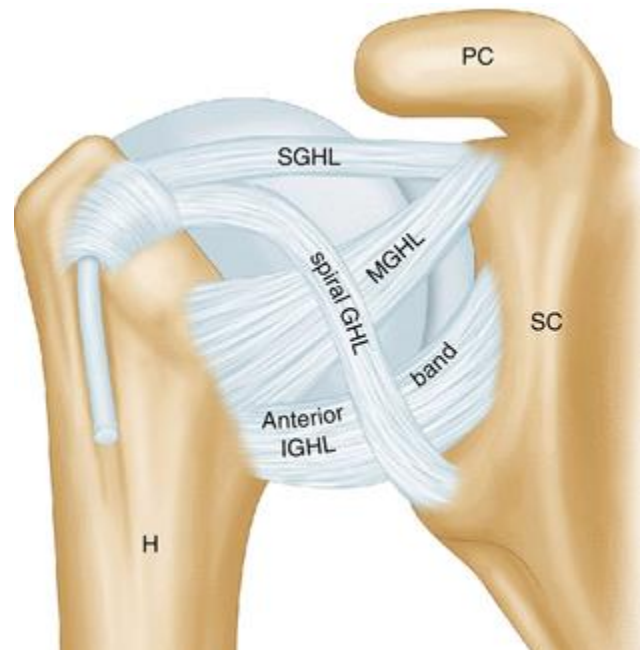
1. Glenohumeral Ligaments

The glenohumeral ligaments are one of the most important group of shoulder ligaments at the glenohumeral joint.

There are four glenohumeral ligaments found on the front of the shoulder joint, the *superior glenohumeral ligament*, *medial glenohumeral ligament*, the *inferior glenohumeral ligament* and the *spiral glenohumeral ligament*, but not everyone has all four.

They connect the humerus bone to the glenoid cavity on the scapula bone in various different places.

Function: the glenohumeral ligaments help to reinforce the glenohumeral joint capsule and improve stability at the front of the joint, particularly with shoulder abduction, adduction and external rotation. All four ligaments help reduce the risk of anteroinferior shoulder dislocation.



Superior Glenohumeral Ligament (SGHL)

Origin: apex (top) of the glenoid fossa near the root of the coracoid process

Insertion: upper portion of the lesser tubercle of the humerus

Special Features: Stabilizes the biceps brachii tendon. Present in 98% of the population

Inferior Glenohumeral Ligament (IGHL)

Origin: inferior (lower) edge of the glenoid fossa

Insertion: anatomical neck of the humerus, just above the lesser tuberosity

Special Features: Strongest of the four glenohumeral ligaments and the main stabilizer of the shoulder when it is abducted. Present in 94% of the population

Medial Glenohumeral Ligament (MGHL)

Origin: medial (inner) edge of the glenoid fossa

Insertion: lower part of the lesser tubercle of the humerus

Special Features: Reinforces the anterior joint capsule. The spiral ligament is the least common glenohumeral ligament, only found in around 45% of the population

2. Coracohumeral Ligament

The coracohumeral ligament (CHL) is a broad shoulder ligament divided into two bands, the superior and inferior bands.

Function: the coracohumeral ligament reinforces and strengthens the upper part of the glenohumeral joint capsule, and protects the head of humerus.

Superior Band

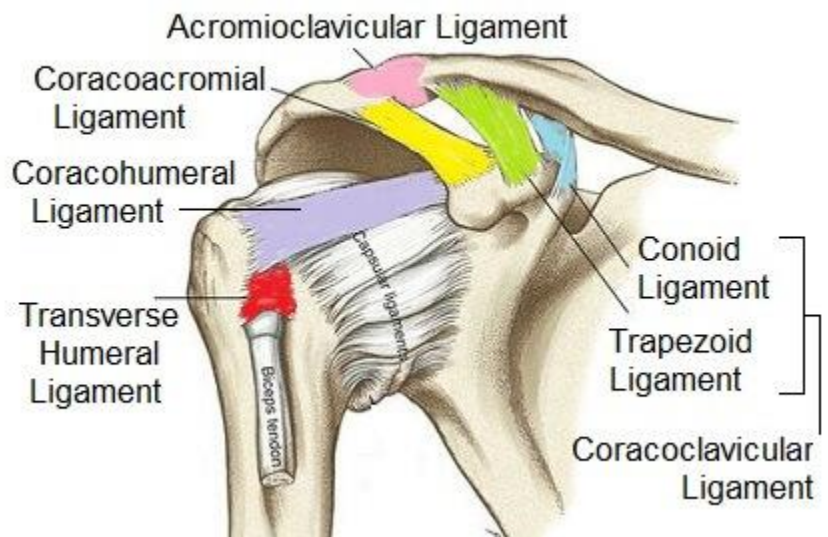
Origin: lateral (outer) border of the base of the coracoid process

Insertion: greater tubercle of the humerus with supraspinatus tendon

Inferior Band

Origin: lateral surface of the base of the coracoid process

Insertion: lesser tubercle of the humerus



3. Acromioclavicular Ligament

The acromioclavicular ligament (ACL) runs horizontally, connecting the shoulder blade and collar bone. It has two parts, the superior acromioclavicular ligament and the inferior acromioclavicular ligament.

Function: The acromioclavicular ligament reinforces the superior (upper) portion of the joint capsule and provides horizontal stability at the AC joint

Superior Acromioclavicular Ligament

Origin: Superior (upper) surface of the acromion

Insertion: lateral (outer) end of the clavicle

Inferior Acromioclavicular Ligament

Origin: inferior (lower) surface of the acromion

Insertion: lateral end of the clavicle

4. Coracoclavicular Ligament

The coracoclavicular ligament (CCL) also connects the shoulder blade to the collar bone. It is made up of two small, but strong parts, the conoid ligament at the back and the trapezoid ligament at the front. The conoid ligament, shaped like an inverted cone, lies medial to the thinner trapezoid ligament.

Function: The coracoclavicular ligament is extremely strong, carries a large load and keeps the scapula attached to the clavicle which provides the square shape to your shoulders. It provides vertical stability at the ACJ and transmits weight from the upper limb to the axial skeleton.

Conoid Ligament

Origin: posterior surface and root of the coracoid process of the scapula

Insertion: conoid tubercle on the inferior surface of the clavicle

Trapezoid Ligament

Origin: superior (upper) surface of the coracoid process

Insertion: trapezoid line on the under surface of the lateral clavicle

5. Coracoacromial Ligament

One of the major shoulder ligaments, the coracoacromial ligament (CAL), is a strong triangular shaped ligament. It connects two parts of the scapula forming an arch over the top of the glenohumeral joint known as the coracoacromial arch. The rotator cuff tendons run under this arch.

Function: The coracoacromial shoulder ligament protects the head of humerus, increases shoulder stability and prevents superior dislocation of the glenohumeral joint. It also transmits loads across the scapula

Origin: lateral border of the coracoid process

Insertion: inferior anterolateral surface of the acromion

Thickening of the coracoacromial ligament often results in impingement syndrome as it reduces the subacromial space.

6. Transverse Humeral Ligament

The transverse humeral ligament (THL), aka Brodie's Ligament, is slightly different to the other shoulder ligaments as it doesn't cross a joint. Instead it spans the gap between the greater and lesser tubercles at the humeral head

Function: The transverse humeral ligament holds the long head of biceps tendon into position in the intertubercular groove.

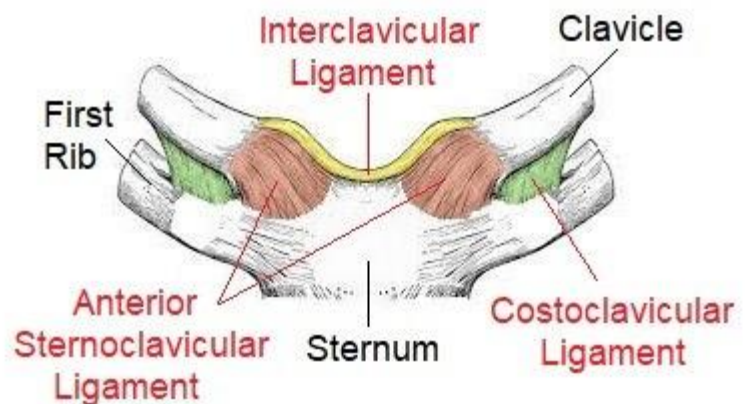
Origin: Greater tubercle of the humerus

Insertion: Lesser tubercle of the humerus (intertubercular sulcus)

7. Sternoclavicular Ligaments

The sternoclavicular ligaments (SCL) connects the collar bone with the breast bone.

There are two parts to this shoulder ligament, the anterior sternoclavicular ligament, and the posterior sternoclavicular ligament, found at the front and back of the joint respectively.



Function: The sternoclavicular ligaments reinforce the joint capsule and help to stabilise the sternoclavicular joint. They limit anterior/posterior translation of the clavicle i.e. stop it moving too far forwards and backwards

Anterior Sternoclavicular Ligament

Origin: medial end of the clavicle

Insertion: Anterosuperior manubrium on the sternum

Special Features: limits excess superior displacement at the joint and resists upward rotation and lateral movement of the clavicle

Posterior Sternoclavicular Ligament

Origin: posterior surface (back) of the sternal end of the clavicle

Insertion: Posteriosuperior manubrium

Special Features: resists downward rotation and medial movement of the clavicle

8. Costoclavicular Ligament

The costoclavicular ligament (CCL) connects the first rib to the collar bone and is a short, flat but very strong ligament. It is also known as Halsted's Ligament or the rhomboid ligament due to its shape.

Function: The Costoclavicular ligament is the main stabilizing structure of the sternoclavicular joint, reinforcing the inferior aspect underneath the sternoclavicular joint. It limits clavicle and shoulder girdle elevation and anteroposterior movement (forwards and backwards) at the sternoclavicular joint

Origin: superior (upper) surface of the 1st rib and its cartilage

Insertion: costal tuberosity on the inferomedial aspect of the clavicle

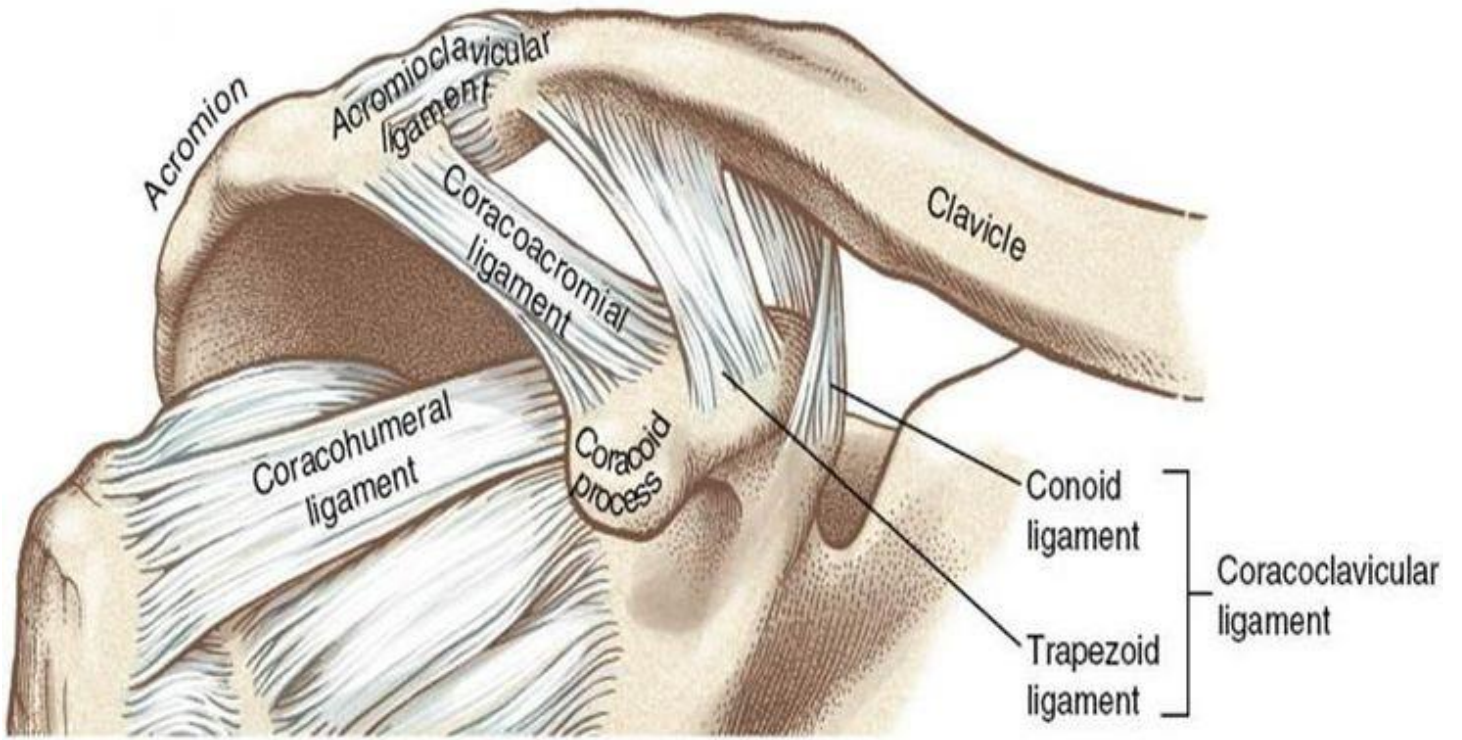
9. Interclavicular Ligament

The interclavicular ligament (ICL) is a flattened band that spans the gaps between the both clavicles running along the upper surface of the sternoclavicular joint.

Function: The interclavicular shoulder ligament reinforces the top part of the sternoclavicular joint capsule. It resists excessive downward glide and clavicular dislocation with shoulder depression

Origin: Upper part of the sternal end of one clavicle

Insertion: Upper part of the sternal end of the other clavicle



The elbow complex

The elbow joint:

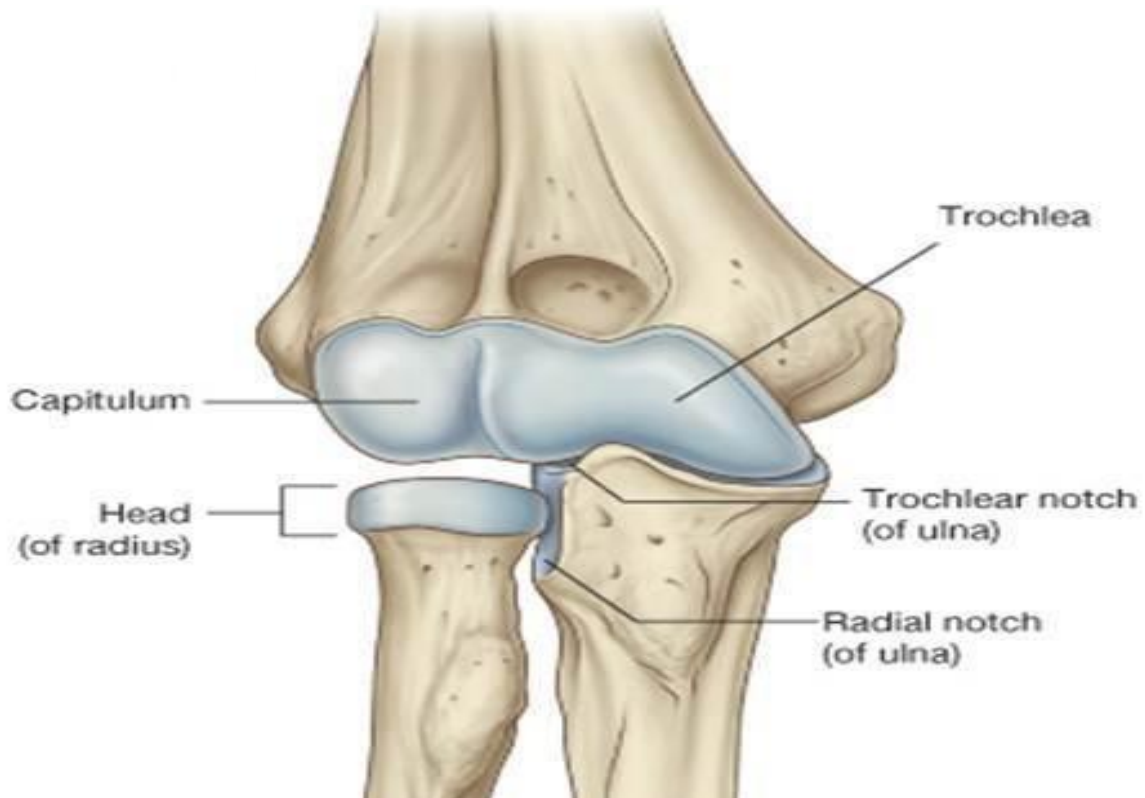
Type: Synovial joint, uniaxial of hinge variety.

Articular surfaces:

Proximally: trochlea and capitulum of humerus.

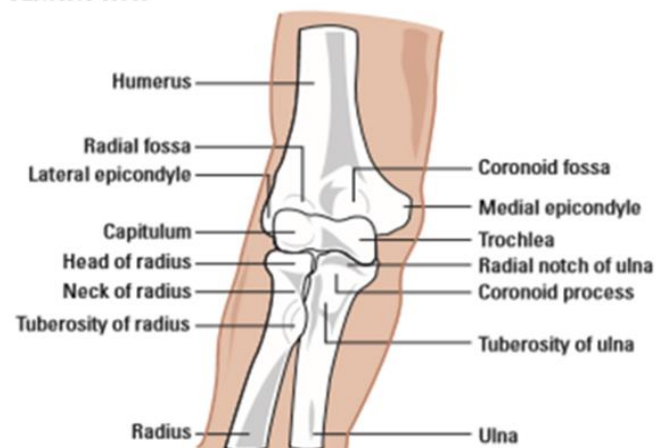
Distally: Trochlear notch of ulna and head of radius.

1. Medially trochlea articulates with trochlear notch of ulna.
2. Laterally capitulum articulates with upper surface of the head of radius.



The elbow joint is a complex structure that provides an important function as the mechanical link in the upper extremity between the hand, wrist and the shoulder. The elbow's functions include positioning the hand in space for fine movements, powerful grasping and serving as a fulcrum for the forearm.

Anterior view



Elbow anatomy (Bones)

The distal humerus comprises two condyles forming the articular surfaces of the capitellum laterally and trochlea medially.

The more prominent medial epicondyle is an attachment point for the ulnar collateral ligament and flexor–pronator group.

The less prominent lateral epicondyle is an attachment point for the lateral collateral ligament and extensor–supinator group.

Anteriorly, the coronoid and radial fossa accommodate the coronoid process of the ulna and radial head, respectively, during flexion.

The bony geometry of the proximal ulna provides the elbow articulation with an inherent stability, especially in full extension.

Posteriorly, the olecranon fossa accommodates the olecranon process of the ulna during extension.

The proximal radius includes the cylindrical shaped radial head, which articulates with both the radial notch of the ulna and capitellum of the humerus.

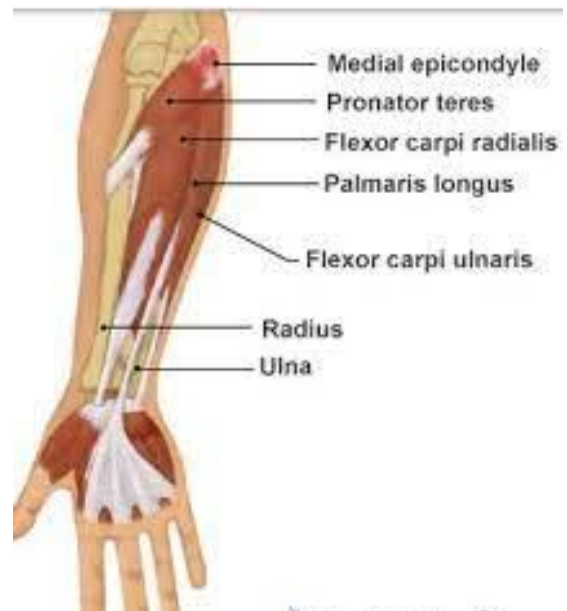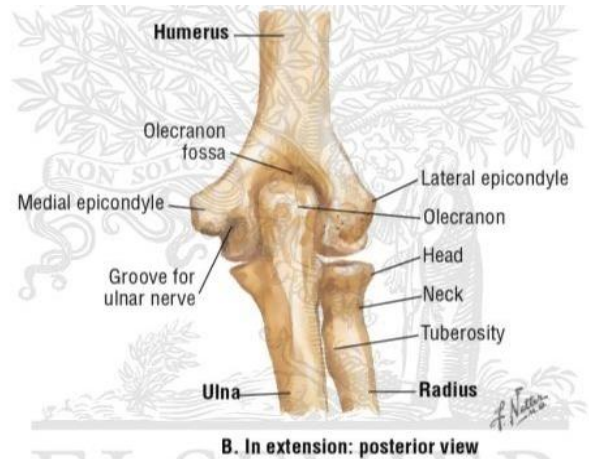The radial neck at its most distal aspect has the radial tuberosity, which is the insertion of the biceps tendon.

The beaked greater sigmoid notch (also known as the incisura semilunaris) articulates with the trochlea of the humerus, and comprises the olecranon (site of triceps attachment) and coronoid process (site of brachialis attachment).

On the lateral coronoid process, the radial notch (semilunar notch) articulates with the radial head.

The crista supinatoris tuberosity is on the lateral aspect of the proximal ulna and serves as the attachment for the lateral ulnar collateral ligament.

On the medial aspect of the proximal ulna, the anterior portion of the medial collateral ligament attaches to the coronoid process.



Capsule:

Attachment: the capsule is attached to the margins of the articular surfaces as follows:

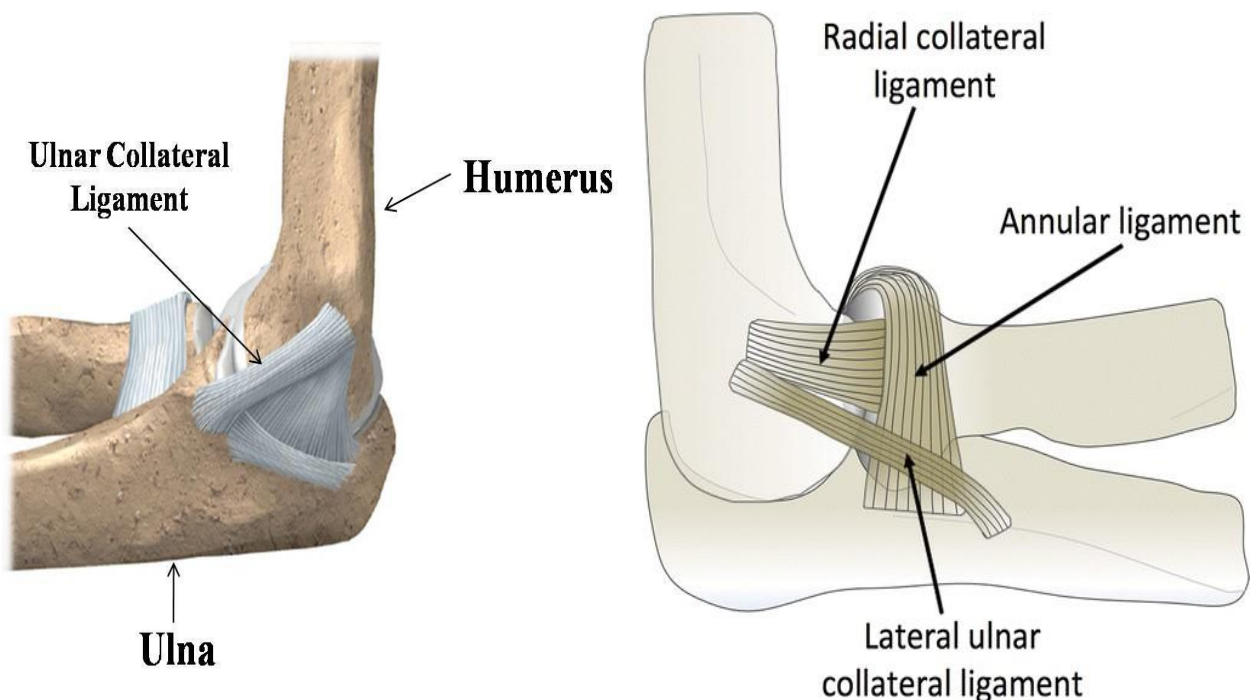
- **Proximal:** front & back of base of medial and lateral epicondyles, immediately above the coronoid, radial & olecranon fossae
- **Distal:** Margin of coronoid and olecranon processes as well as annular ligament which surrounds the head of radius.

Ligaments:

Medial (ulnar) collateral ligament:

- It **prevents abduction** of the elbow joint & composed of 2 bands attached above to the medial epicondyle:
 - **Anterior band:** attached below to the medial border of coronoid process.
 - **Posterior band:** attached below to the olecranon process.

Lateral (radial) collateral ligament: It prevents adduction and attached above to the lateral epicondyle and below to the outer surface of annular ligament.



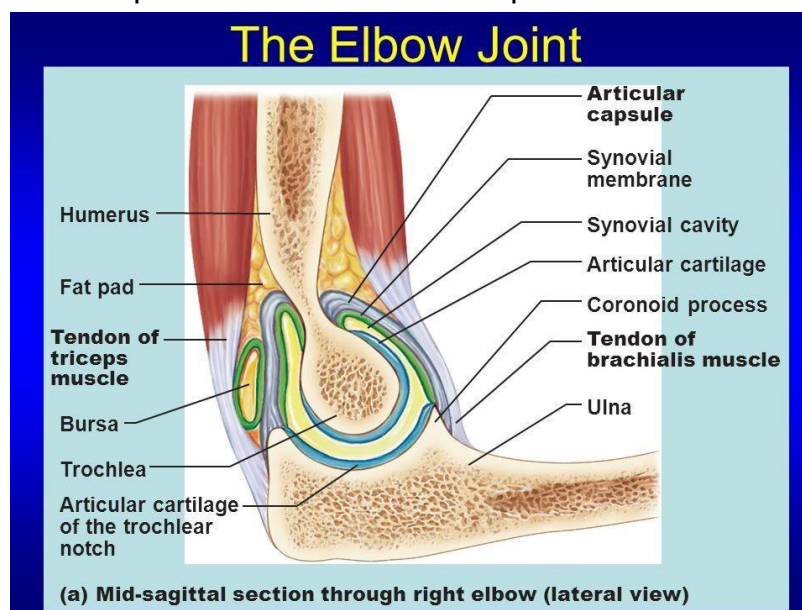
Strength: As any hinge joint, the capsule is thin both in front and behind to allow flexion and extension and thick at the sides to prevent abduction and adduction.

Notes

- Medial and lateral epicondyles are extra-capsular.
- The elbow joint & superior radio-ulnar joint have a common capsule.

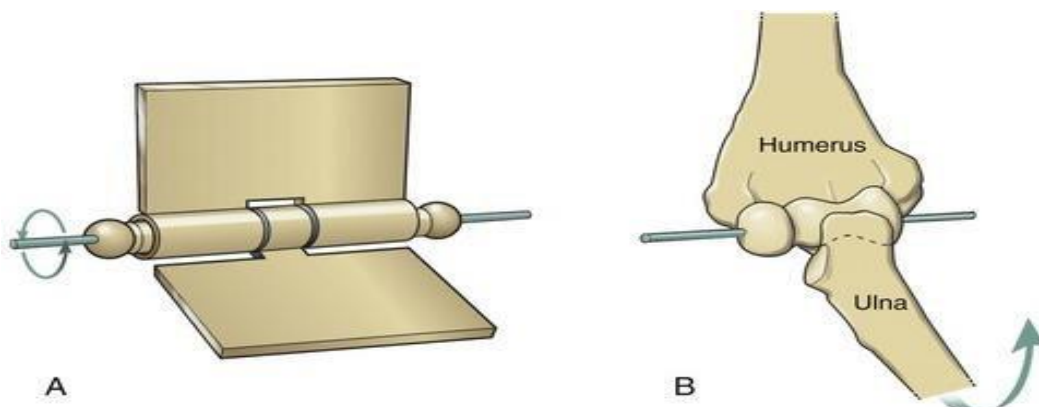
Synovial membrane: Is continuous with that of superior radioulnar joint.

Bursa: A bursa separates the tendon of triceps from the back of the capsule.

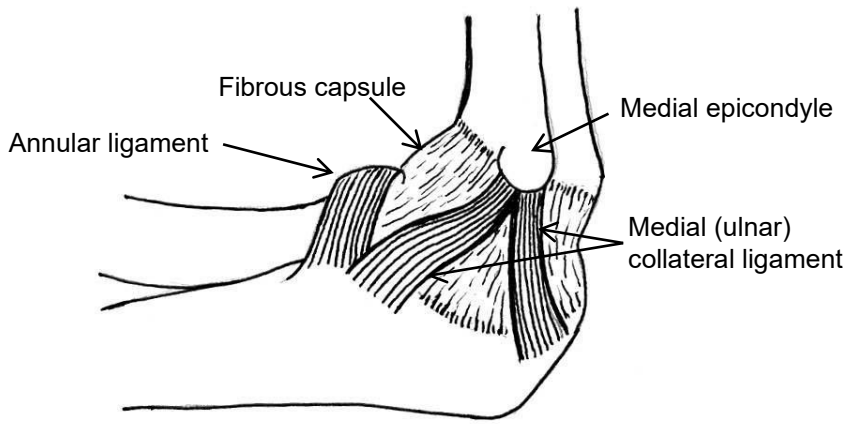
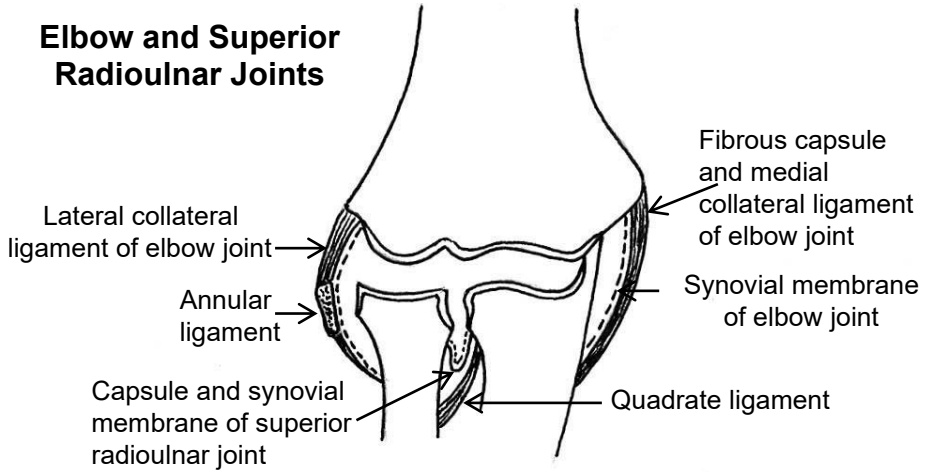


Movements:

1. **Extension:** Triceps (main extensor), anconeus and superficial extensors of the forearm.
2. **Flexion:** Brachialis (main flexor), biceps, brachio-radialis (in midprone position) and superficial flexors of the forearm.

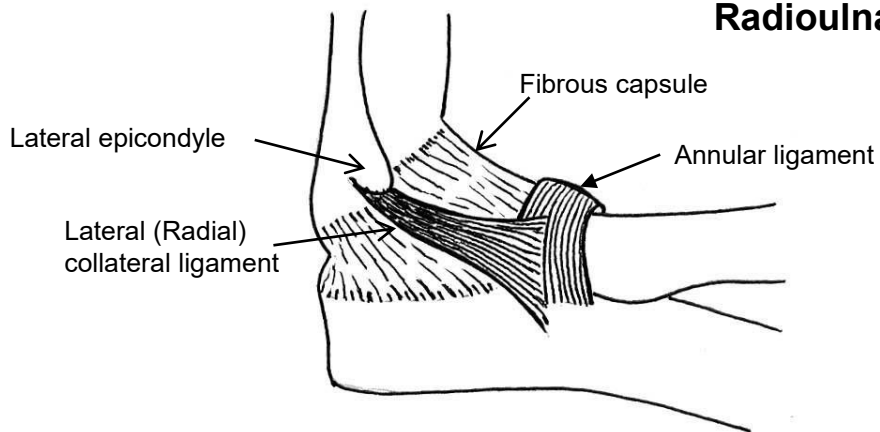


Elbow and Superior Radioulnar Joints



Medial View

Ligaments of Elbow and Superior Radioulnar Joints

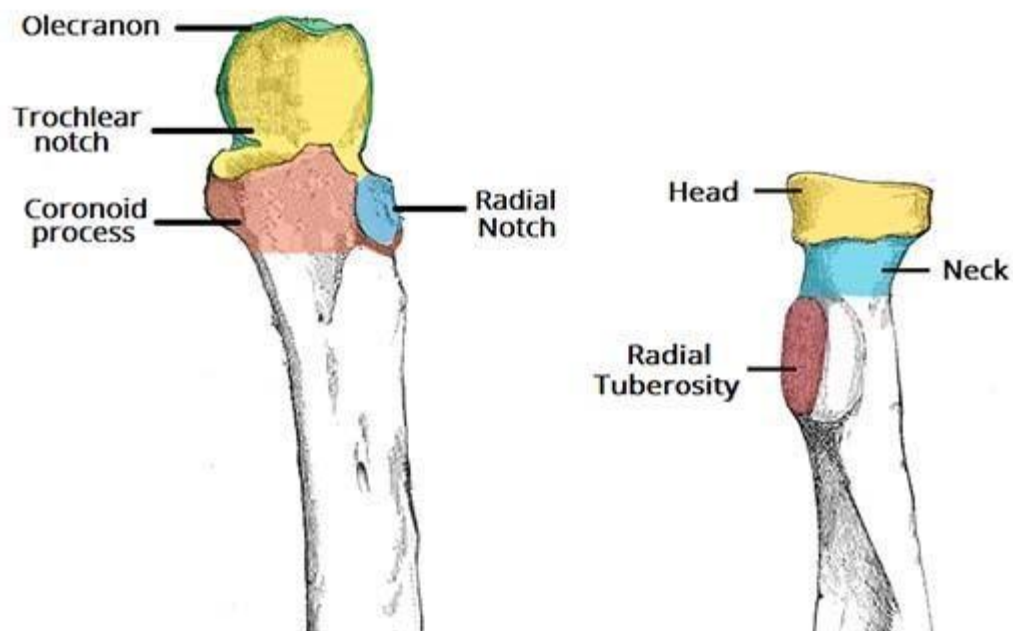


Lateral view

Superior radio-ulnar joint

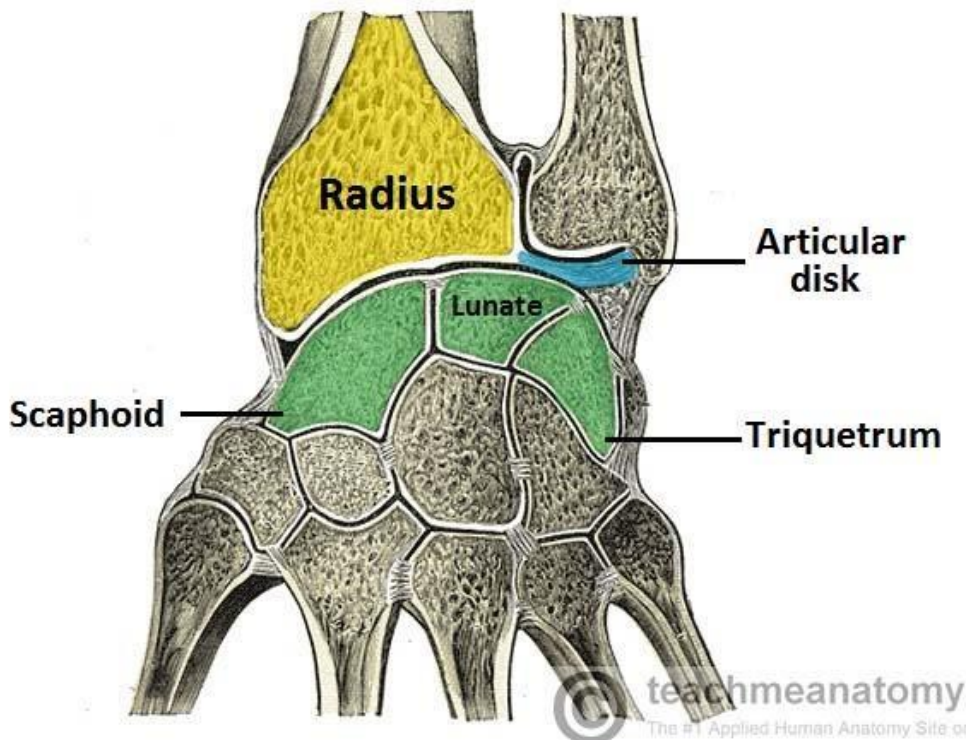
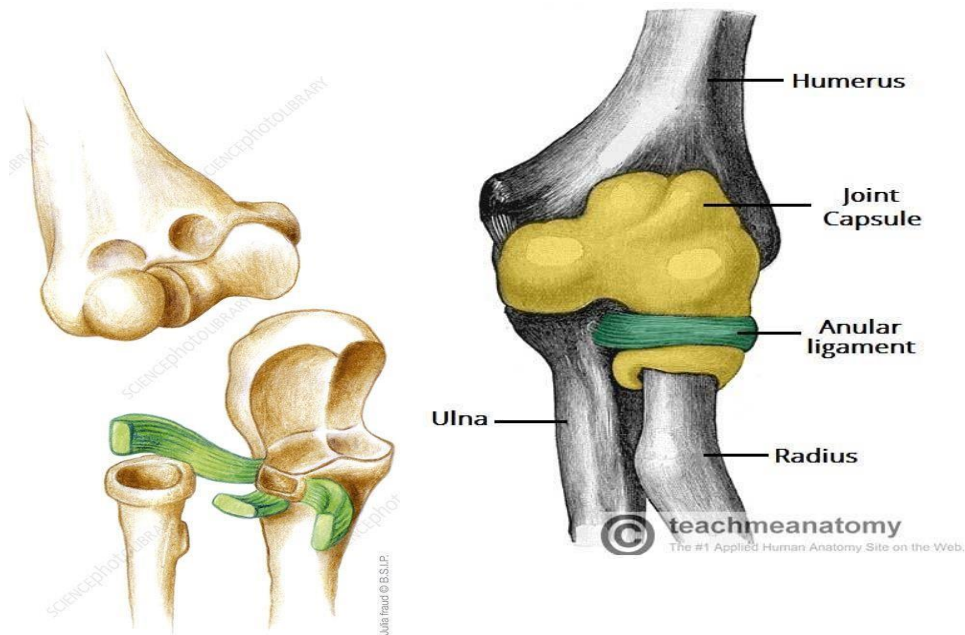
Type: Synovial, uniaxial (pivot) joint.

Articular surfaces : The circumference of the head of radius rotates against the radial notch of ulna. At any time in pronation or supination only one quarter of the circumference of the head of radius articulates with the radial notch of ulna. The remaining three quarters of the head articulates with the annular ligament.

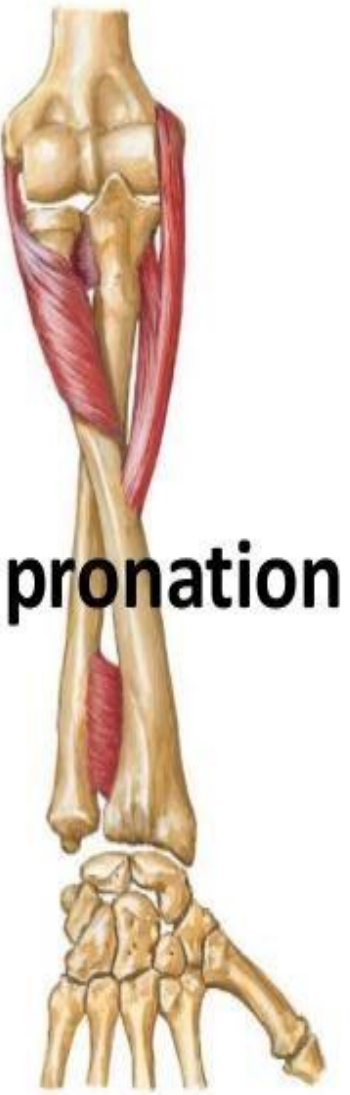
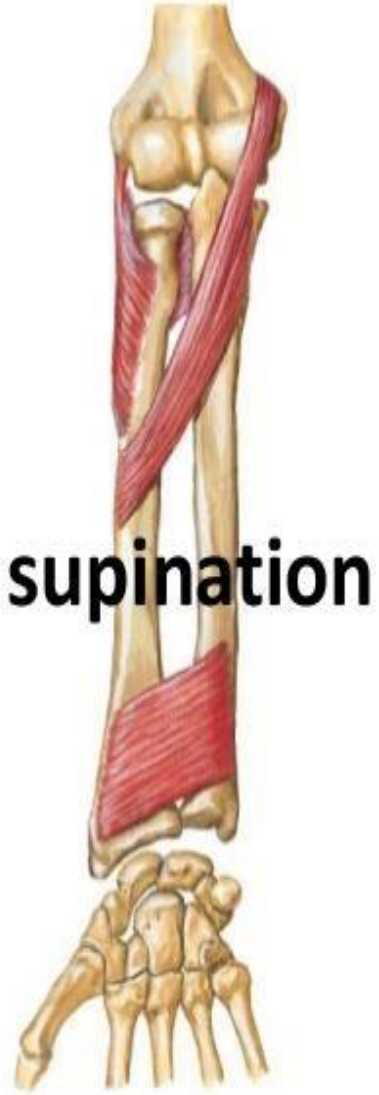
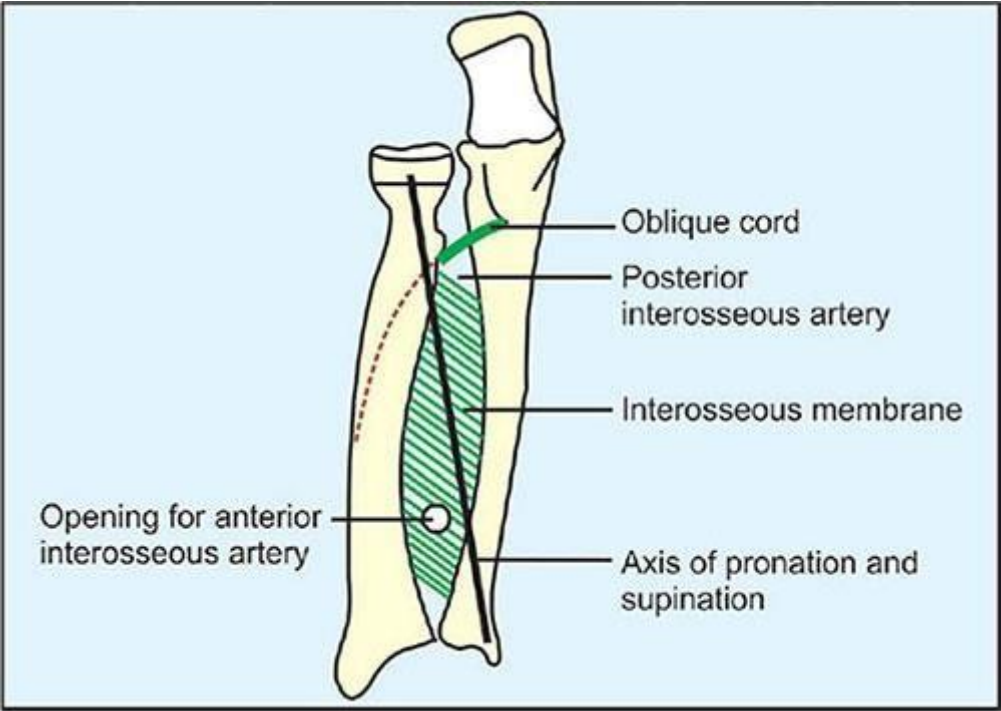


Capsule and Ligaments:

1. Continuous above with the capsule of the elbow joint. Their joint spaces are continuous together.
2. The synovial membrane is a downward prolongation of the synovial membrane of the elbow joint.
3. Annular ligament: Is about three quarters of a circle attached to the anterior and posterior margins of the radial notch of ulna and encircles the head of radius. It gives attachment to the capsule and lateral collateral ligament of the elbow joint. It is slightly narrower below than above and this prevents the head of radius from being dislocated downwards.
4. Quadrate ligament: Connects the lower margin of the radial notch of the ulna to the medial aspect of the neck of radius just above its tuberosity.

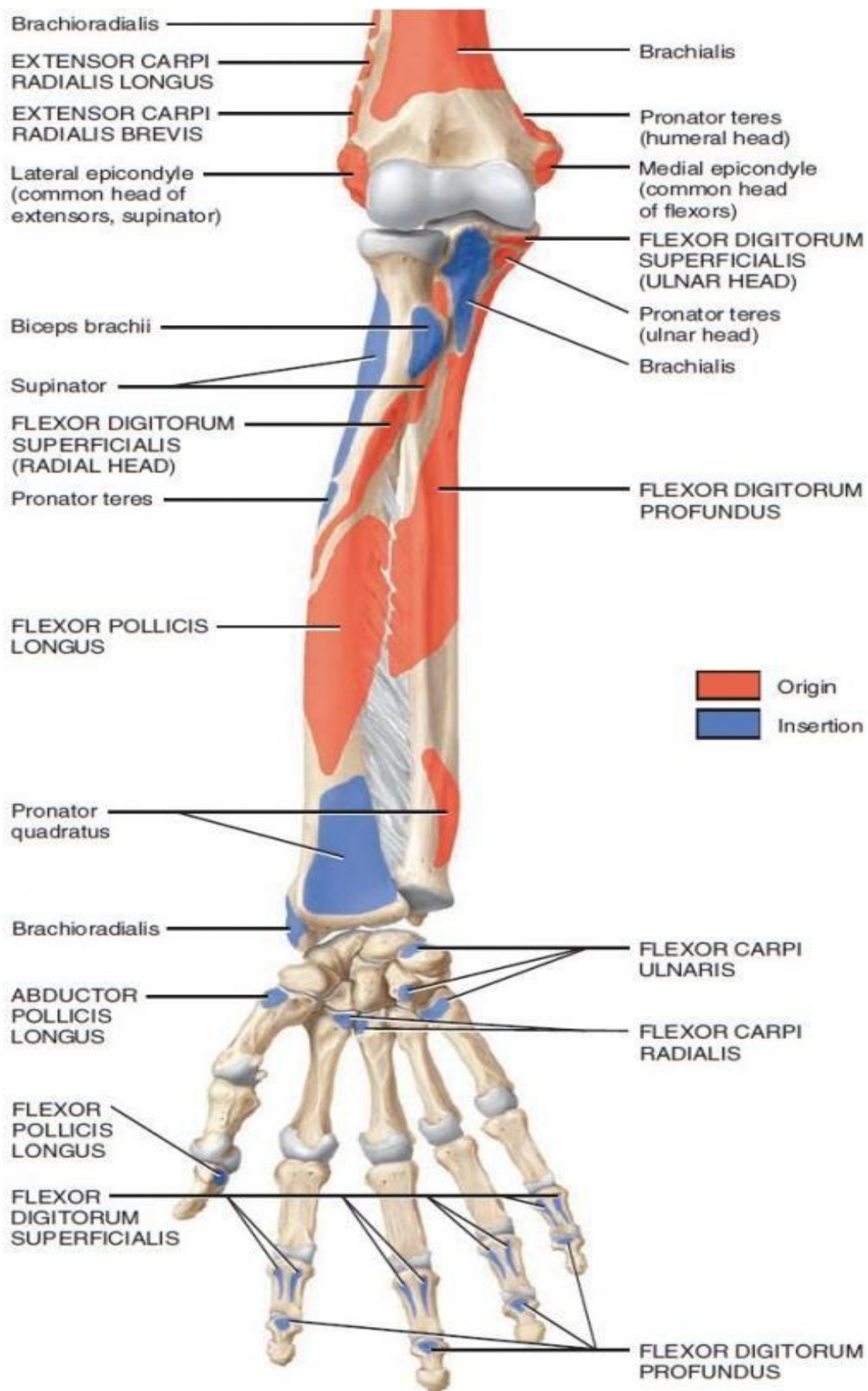


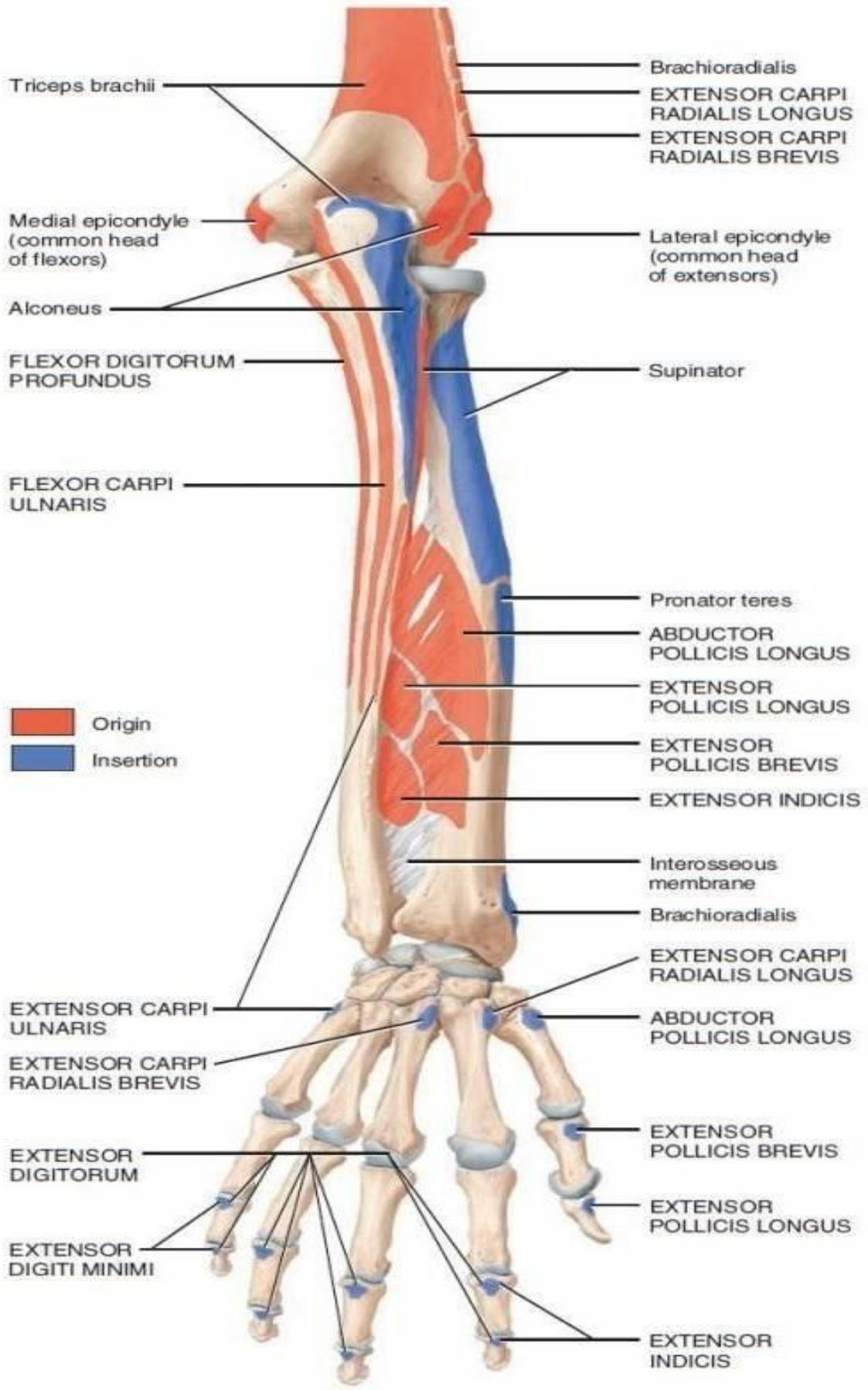
- **Supination:** The radius lies parallel to the ulna and the palm of the hand is directed forwards.
- Supination is produced by supinator (mainly, produce supination of extended elbow) and biceps (produce supination of flexed elbow).
- **Pronation:** The head of radius rotates within the annular ligament and its lower end rotates around the head of ulna → The radius carrying the hand crosses obliquely in front of ulna with the palm of the hand directed backwards.
- Pronation is produced by pronator teres , pronator quadrates and brachioradialis (bring forearm to midprone position).



The Interosseous Membrane

- ★ **Attachment:** In addition to superior and inferior radio-ulnar joints, the radius and ulna are also joined by a fibrous membrane called interosseous membrane.
 1. **Laterally:** It is attached to the interosseous border of radius.
 2. **Medially:** It is attached to the interosseous border of ulna.
 3. **Above:** It ends at a free border one inch below the radial tuberosity.
 4. **Below:** It blends with the capsule of inferior radio-ulnar joint.
- ★ **Direction of fibers:** The fibers of interosseous membrane run obliquely downwards and medially from radius to ulna.
- ★ **Functions:**
 1. Increases the area for attachment of muscles of the forearm.
 - Muscles which take origin from the anterior surface of interosseous membrane:
 - Flexor pollicis longus
 - Flexor digitorum profundus
 - Muscles which take origin from the posterior surface:
 - Abductor pollicis longus
 - Extensor pollicis longus
 - Extensor pollicis brevis
 - Extensor indices
 2. The radius receives forces from the hand. The interosseous membrane, due to the direction of its fibers, transmits forces from radius to ulna which in turn transmits forces upwards to the humerus.





Notes

Ligaments

Radial collateral

Ulna collateral

Anular

The humeroulnar joint is a hinge joint and the humeroradial joint is a limited ball-and-socket joint.

We get pronation and supination at the proximal radioulnar joint. This joint is a pivot joint.

Movements

Extension:

- 1- Triceps
- 2- Anconeus

Flexion:

- 1- Brachialis
- 2- Biceps
- 3- Brachio-radialis
- 4- Superficial flexors of the forearm.

The wrist and hand complex

The wrist joint (Radio-carpal joint)

Type: Synovial, biaxial, ellipsoid joint.

Articular surfaces:

- **Proximal articular surface:** elliptical concave surface formed by:
 1. The inferior surface of lower end of radius.
 2. Inferior surface of articular disc of inferior radio-ulnar joint which lies below the head of ulna.
- **Distal articular surface:** oval convex surface formed of three carpal bones:
 1. Scaphoid and lunate lie below the radius.
 2. Triquetrum lies below the articular disc below the head of ulna.

Note: The ulna does not come in direct contact with the carpal bones due to the presence of the articular disc of cartilage below the head of ulna. Therefore, the wrist joint is called radio-carpal joint.

Capsule and ligaments:

- The capsule is attached to the margins of the articular surfaces.
- The lateral and medial parts of the capsule are thickened to form radial (lateral) and ulnar (medial) collateral ligaments of the wrist. They descend from the styloid processes of both radius and ulna to become attached to the proximal carpal bones below.
- The capsule is strengthened in front and behind by anterior and posterior (palmar and dorsal) radio-carpal ligaments which pass obliquely downwards and medially from the lower end of the radius to the carpal bones. They are important as they force the carpus to move with the radius as one unit during pronation and supination.

Movements:

A. Flexion:

1. Flexor carpi radialis is a main flexor
2. Flexor carpi ulnaris is a main flexor

3. Palmaris longus
4. All the long muscles whose tendons cross in front of the wrist help in flexion.

B. Extension:

1. Extensor carpi radialis longus is a main extensor
2. Extensor carpi radialis brevis is a main extensor
3. Extensor carpi ulnaris is a main extensor
4. All the long muscles whose tendons cross behind the wrist help in extension.

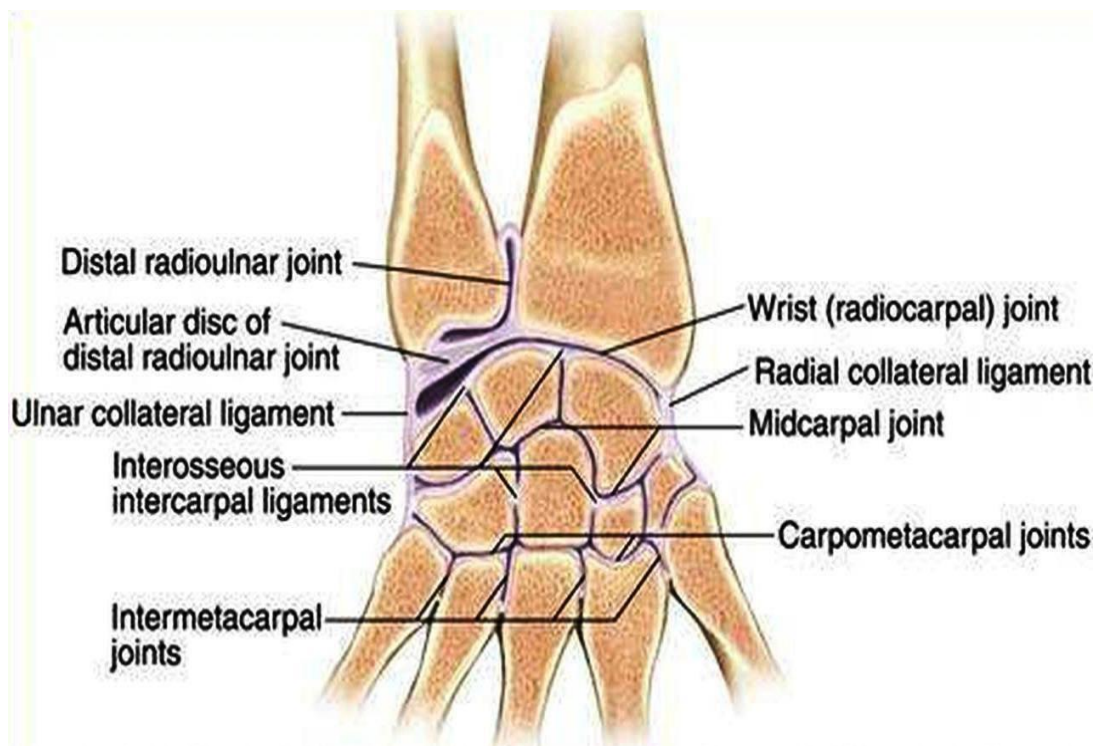
• **Adduction:**

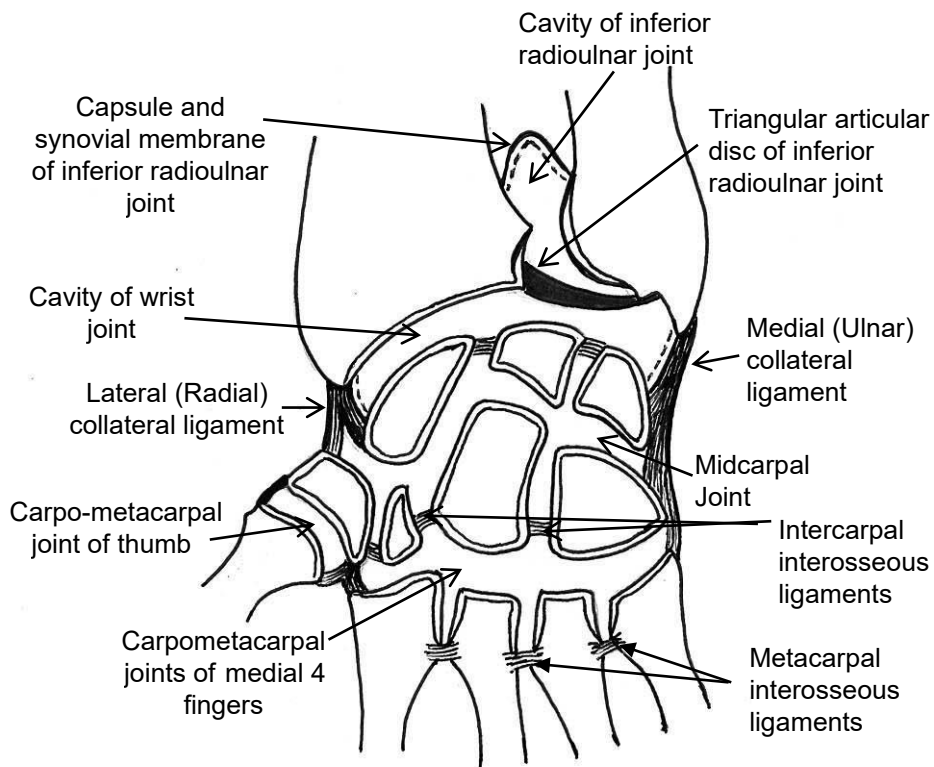
1. Flexor carpi ulnaris
2. Extensor carpi ulnaris

• **Abduction:**

1. Extensor carpi radialis longus
2. Extensor carpi radialis brevis
3. Flexor carpi radialis
4. Abductor pollicis longus

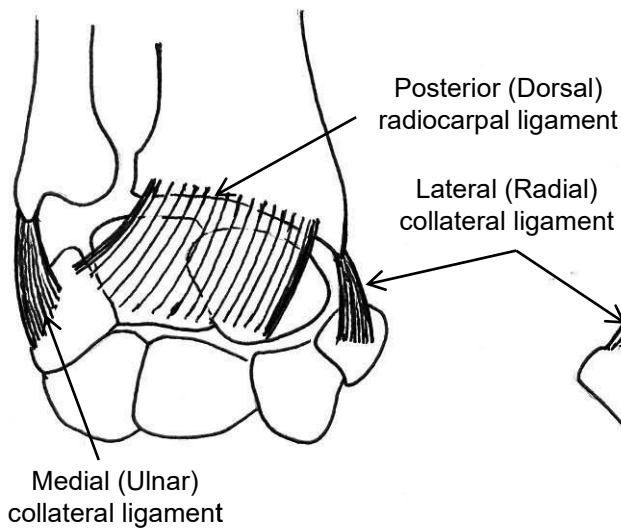
• **Circumduction:** Combination of the above mentioned four movements.



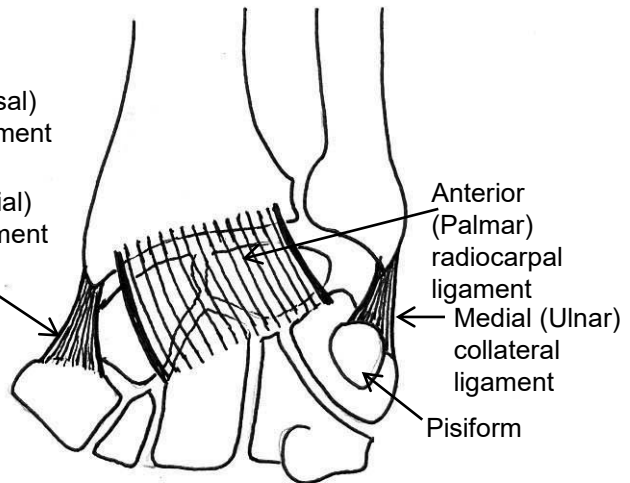


**Wrist Joint, Inferior Radioulnar Joint
Midcarpal and Carpometacarpal
Joints**

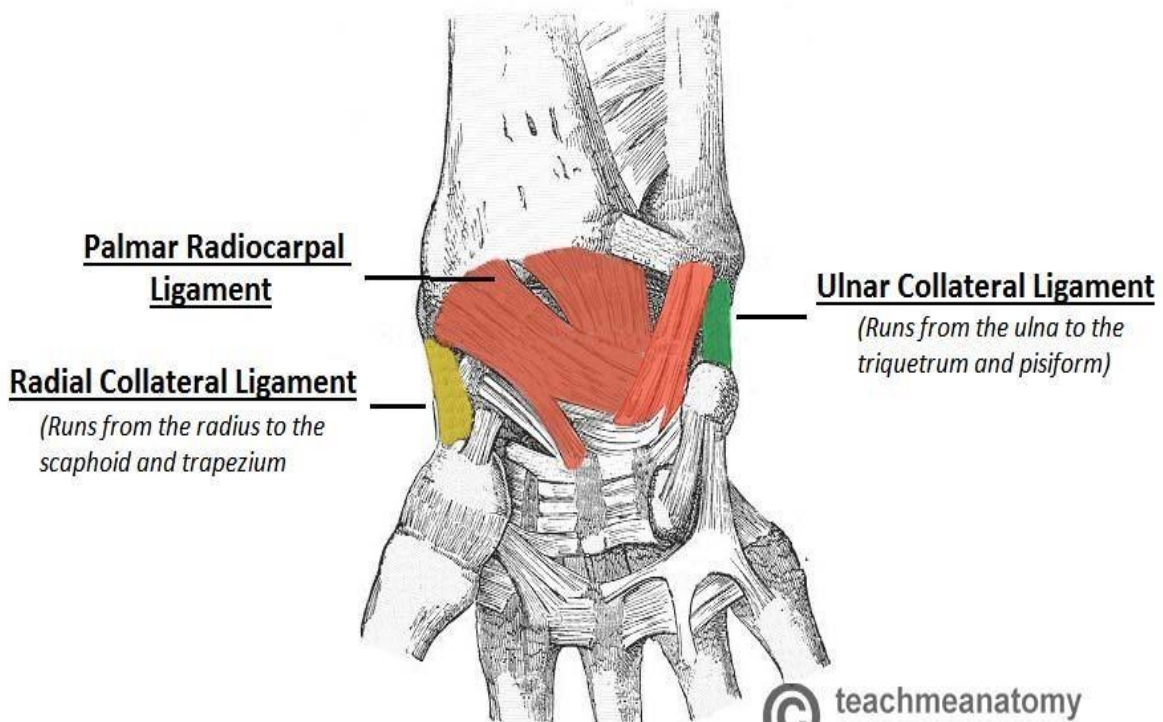
*** Posterior View**



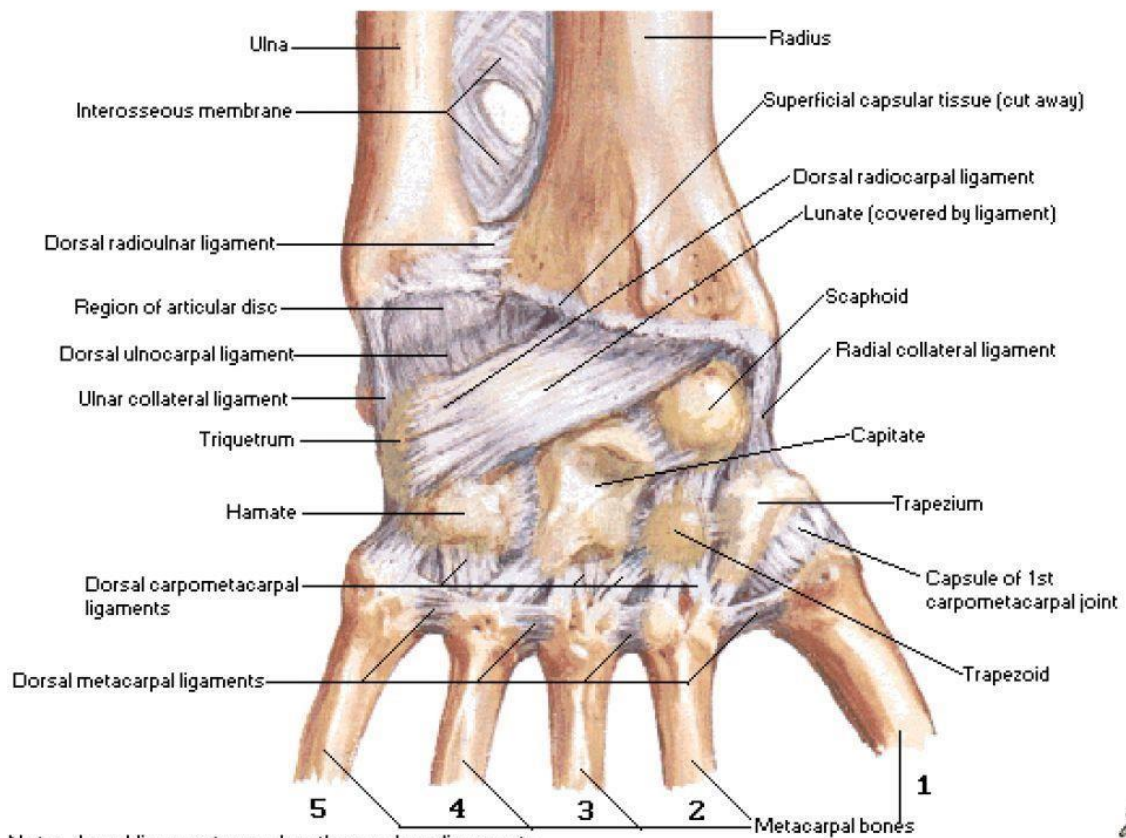
*** Anterior View**



Ligaments of Wrist Joint



Ligaments of Wrist
Posterior [Dorsal] View



Note: dorsal ligaments weaker than palmar ligaments

The mid-carpal joint

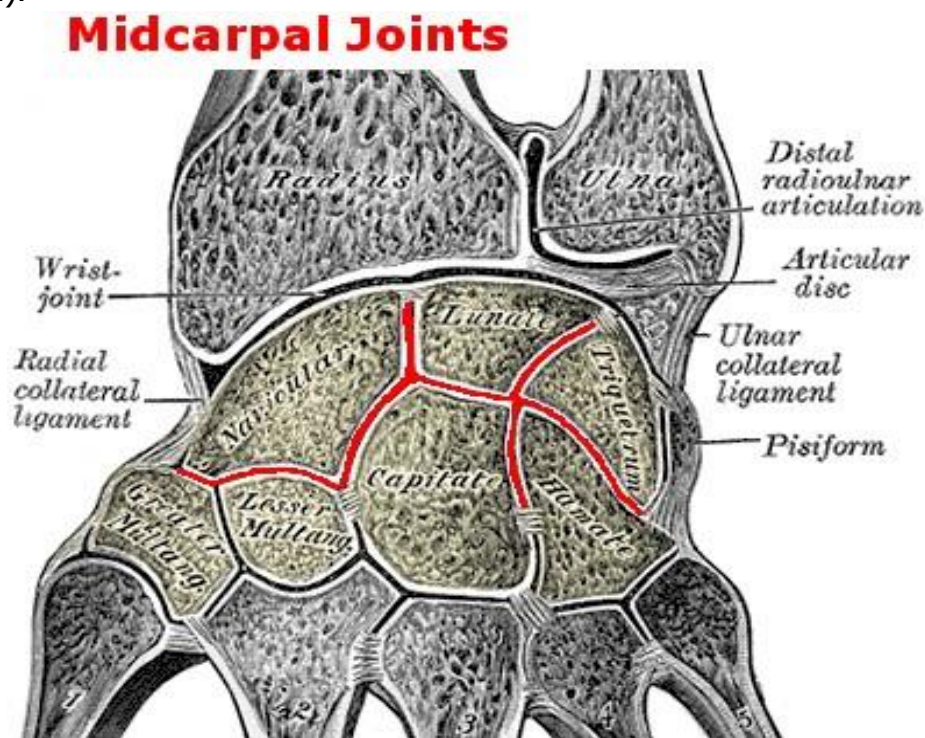
Type and Variety: Synovial; modified ellipsoid joint.

Articular surfaces: It is the joint between:

1. The proximal row of carpal bones (except pisiform), as one unit.
2. The distal row of carpal bones, as the second unit.

Capsule: It has a common capsule and a common joint cavity.

Movements: Its movements are complimentary to those of wrist joint but much more limited. It allows limited flexion, extension, abduction and adduction (the same muscles as the wrist are concerned).



The carpo-metacarpal joints

I) C/M joint of the thumb:

Type: Synovial, biaxial, saddle joint.

Articular surfaces:

- **2** concavo-convex surfaces between the base of 1st metacarpal bone and the trapezium.
- All the metacarpal bones, except that of the thumb, join the carpus in such a way that their palmar surfaces look forwards.
- The metacarpal bone of the thumb joins the trapezium in such a way that it is rotated 90 degrees so that its palmar surface looks medially.
- The plane of the thumb lies at right angle to that of the other fingers. This makes the thumb able to oppose the other fingers.

Movements: It is the next freely moveable joint after the ball and socket variety. It produces flexion, extension, adduction, abduction, opposition and circumduction.

Note: The thumb is the most important finger because of its ability to oppose the other four fingers, performing fine movements & responsible for grasping function of the hand.

II) C/M joints of medial 4 fingers:

Type: Synovial, plane joint.

Articular surfaces: The distal row of carpal bones articulate with the bases of the medial 4 metacarpal bones.

Movements: minimal gliding movements. The little finger has an opponens muscle which can move its metacarpal bone forwards and laterally toward the thumb and helps in cupping the hand.

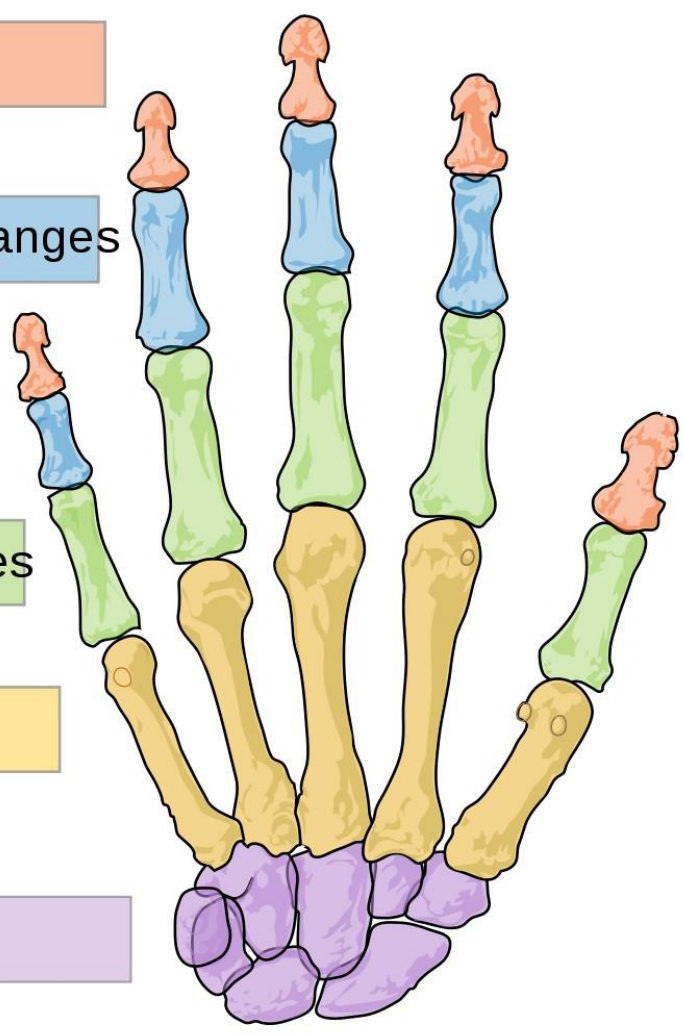
Distal phalanges

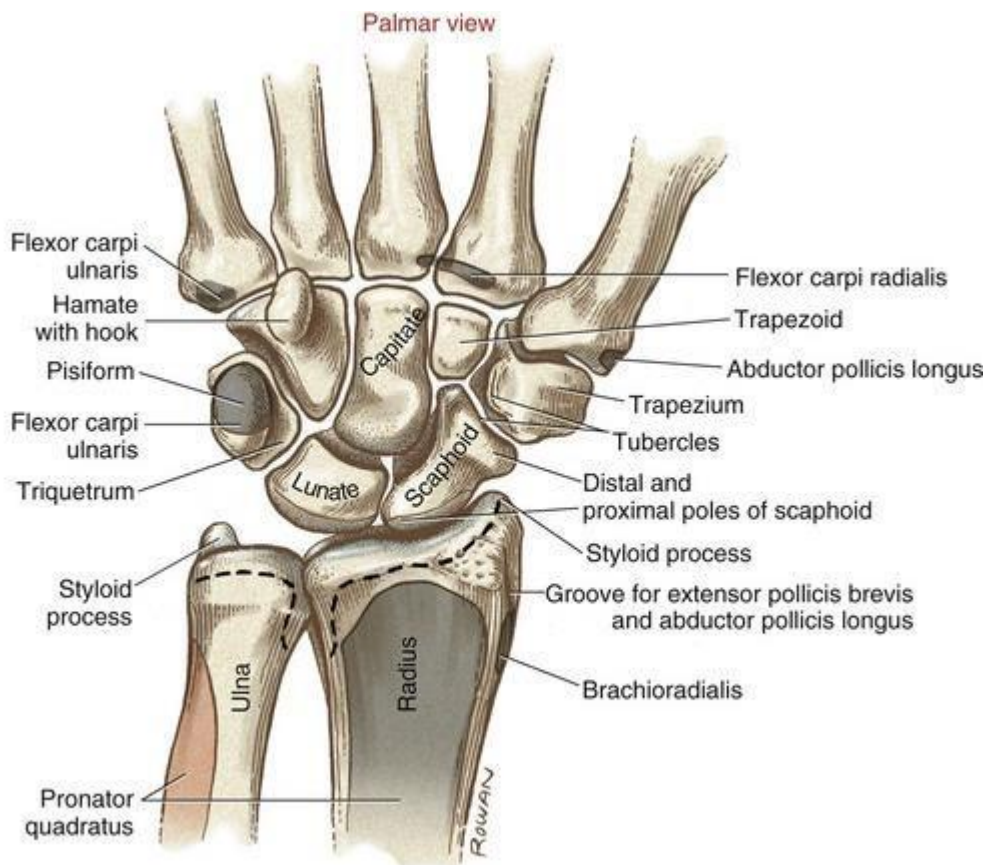
Intermediate phalanges

Proximal phalanges

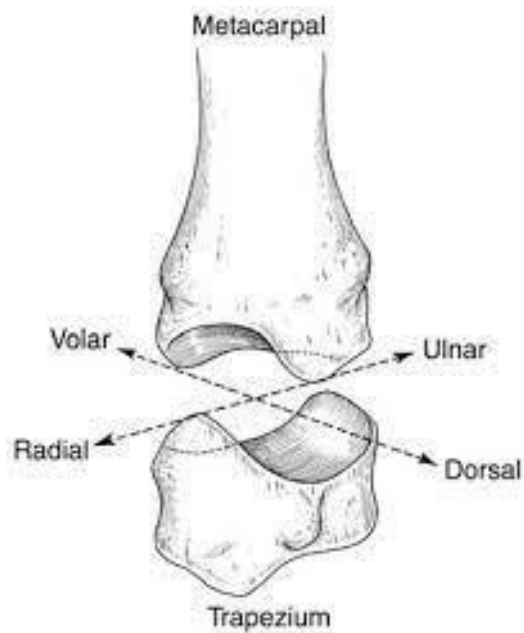
Metacarpals

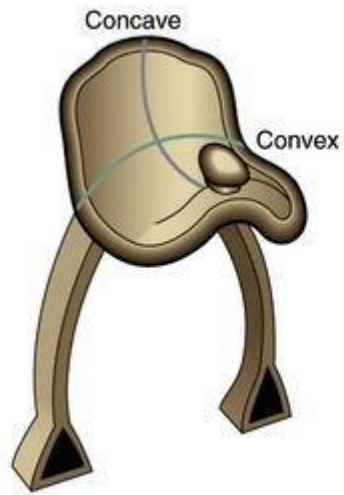
Carpals



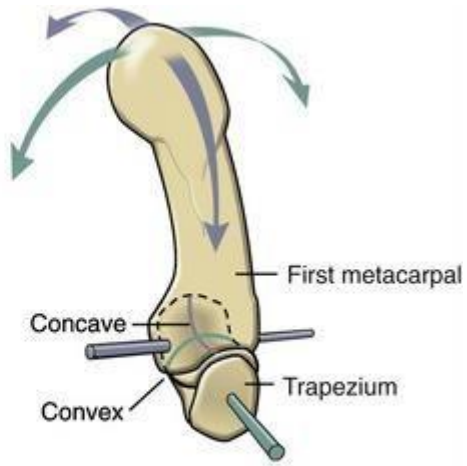


A

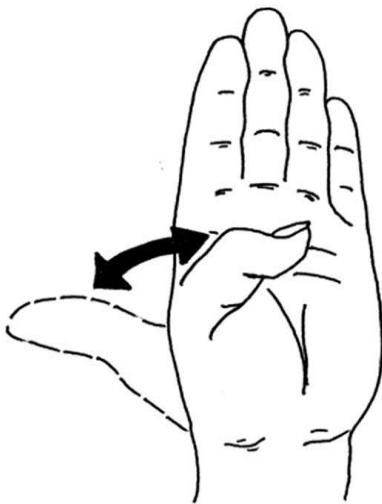




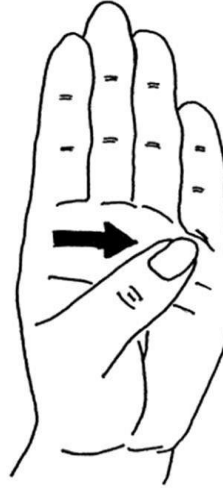
A



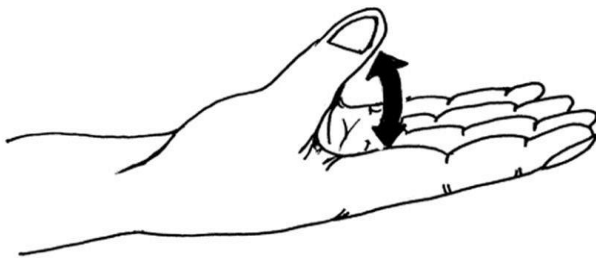B



Flexion →
Extension ←



Opposition
(Flexion+ Medial rotation)



Abduction ↑
Adduction ↓

MOVEMENTS OF THUMB

The metacarpo-phalangeal joints

Type: Synovial joints, ellipsoid variety except that of the thumb is hinge (adduction and abduction are restricted)

Articular surfaces:

- A. Heads of the metacarpal bones.
- B. Bases of the proximal phalanges.

Ligaments:

1. Medial and lateral collateral ligaments pass distally from the head of metacarpal to the base of proximal phalanges.
2. Palmar ligament forms the palmar aspect of the joint capsule.
3. The palmar ligaments of medial 4 metacarpo-phalangeal joints are attached together by deep transverse metacarpal ligaments that hold the heads of metacarpal bones together.

Movements:

- A. Metacarpo-phalangeal joints of the medial four fingers allow:
 - 1. Flexion:** By lumbricals, interossei, flexor digitorum superficialis and profundus.
 - 2. Extension:** By extensor digitorum, extensor indices and digiti minimi.
 - 3. Adduction:** Palmar interossei.
 - 4. Abduction:** Dorsal interossei.
- B. Metacarpo-phalangeal joint of the thumb: A hinge joint and allows:
 - 1. Flexion:** By flexor pollicis longus and brevis.
 - 2. Extension:** By extensor pollicis longus and brevis.

Interphalangeal joints

Type: Synovial, uniaxial (hinge) joints.

Ligaments: medial & lateral collateral ligaments and palmar ligaments (like metacarpophalangeal joints)

Movements: They allow flexion and extension only.

- In the medial four fingers:

1. Flexion:

- Flexor digitorum profundus (acting on both proximal and distal interphalangeal joints but it acts mainly on the distal one).
- Flexor digitorum superficialis (acting only on proximal interphalangeal joint).

2. Extension:

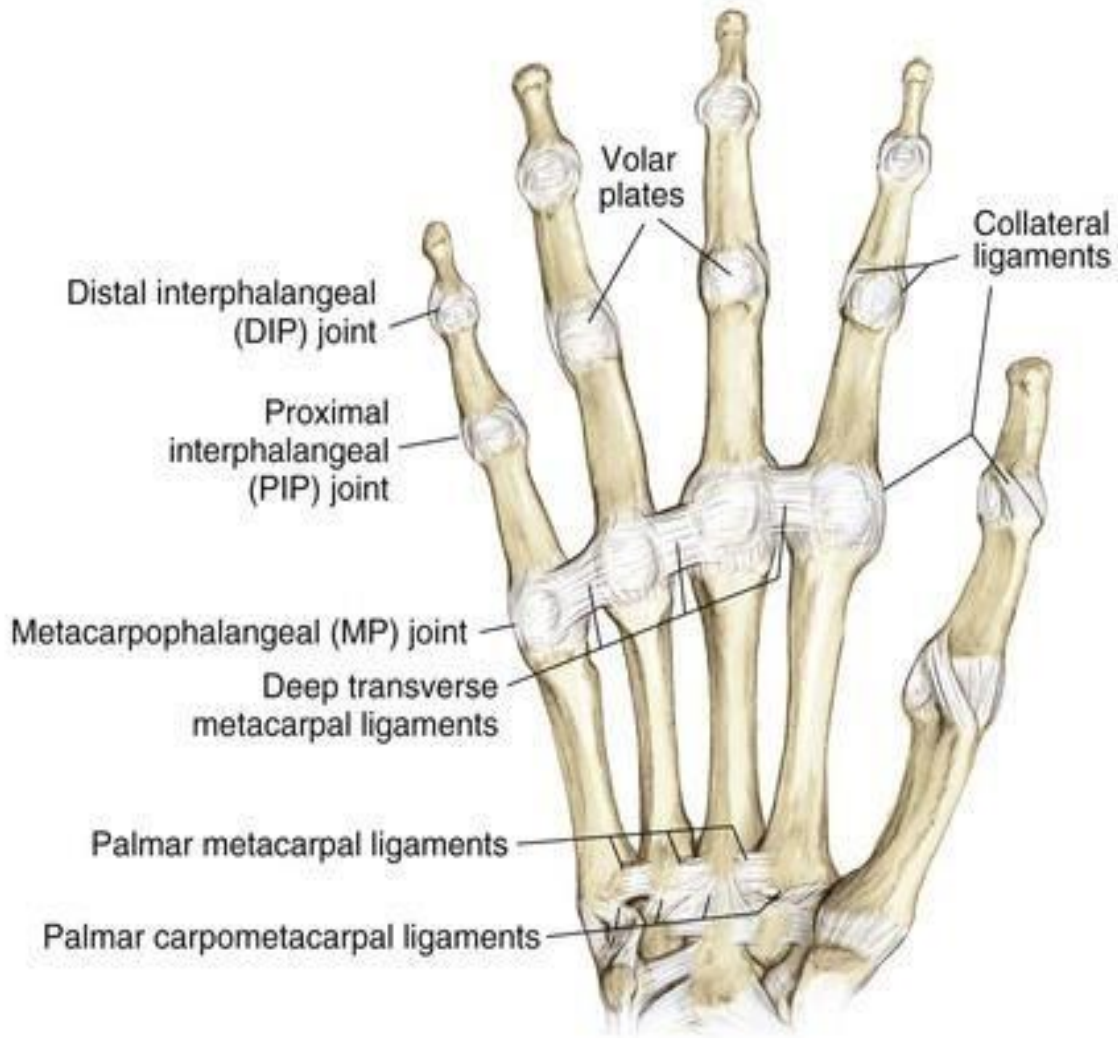
- Lumbricals
- Interossei

- In the **thumb**:

1. Flexion: Flexor pollicis longus

2. Extension: Extensor pollicis longus

VOLAR VIEW



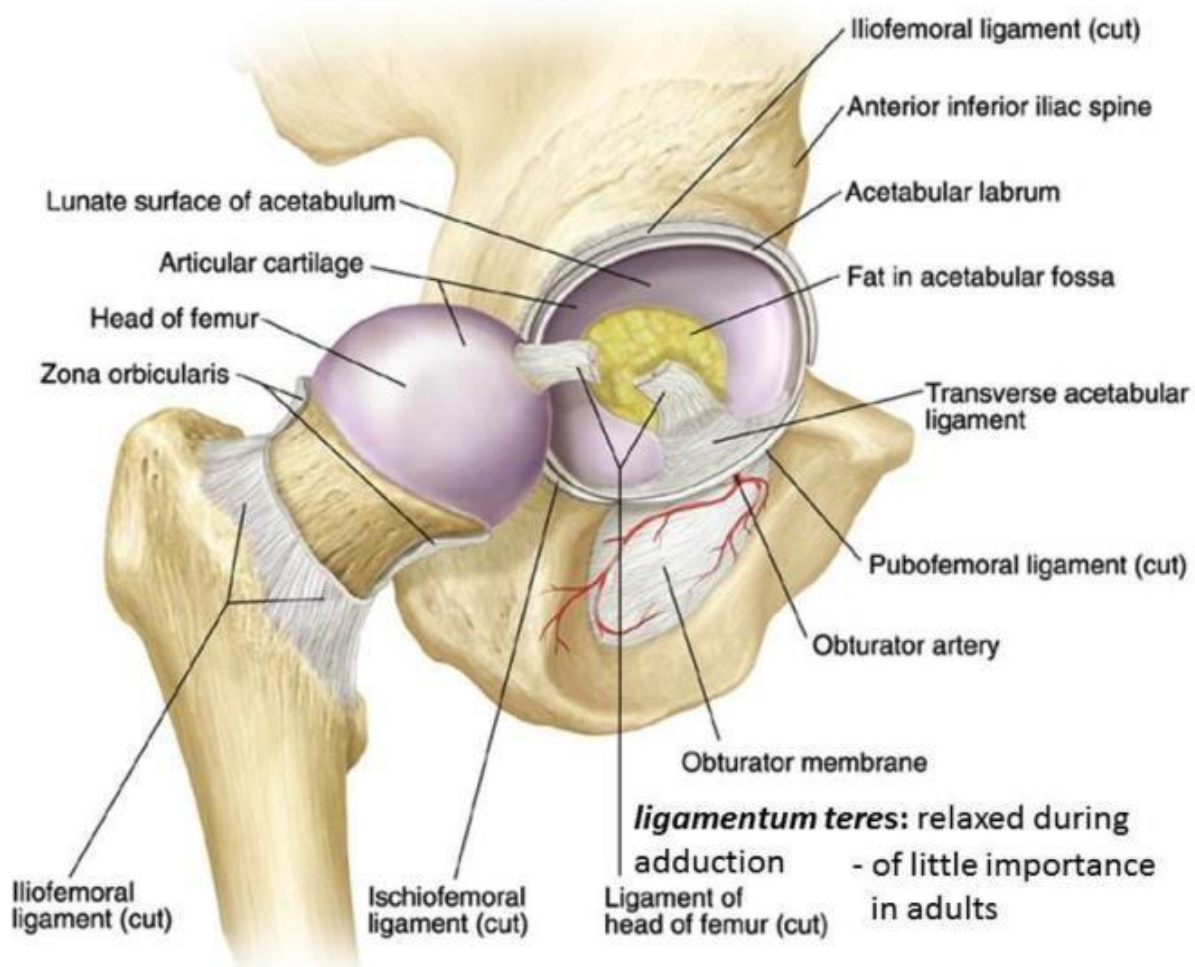
Hip joint

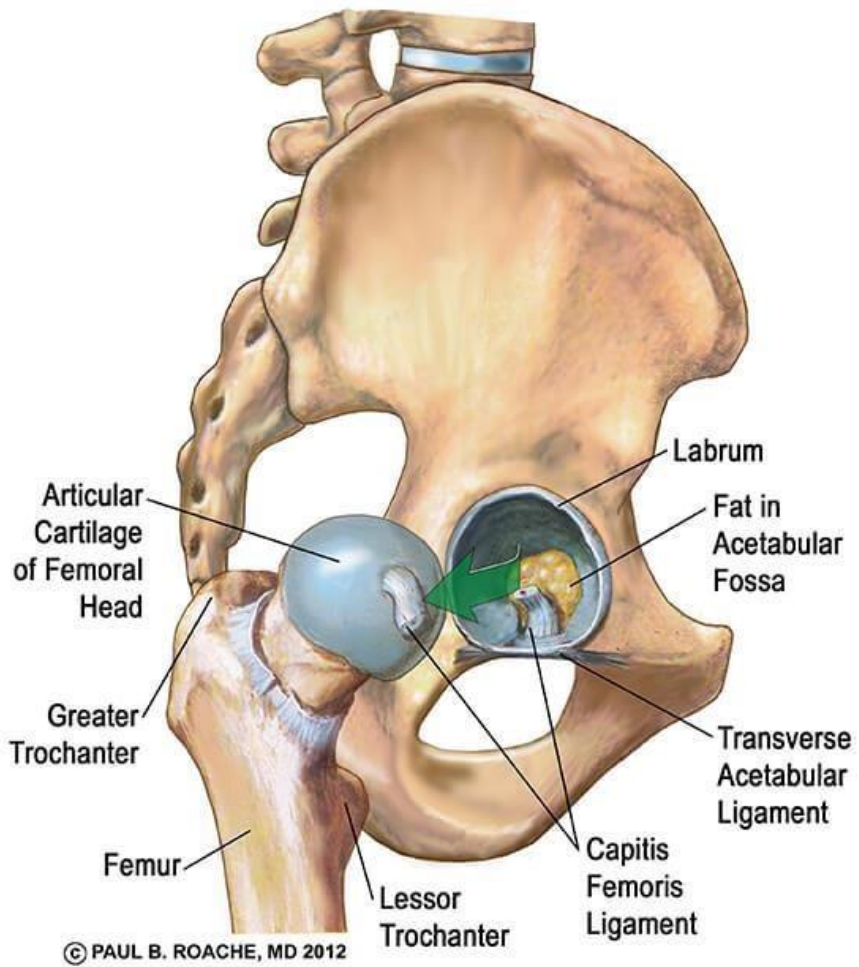
★ **Type:** synovial, polyaxial joint, **ball and socket variety.**

★ **Articulating bones:**

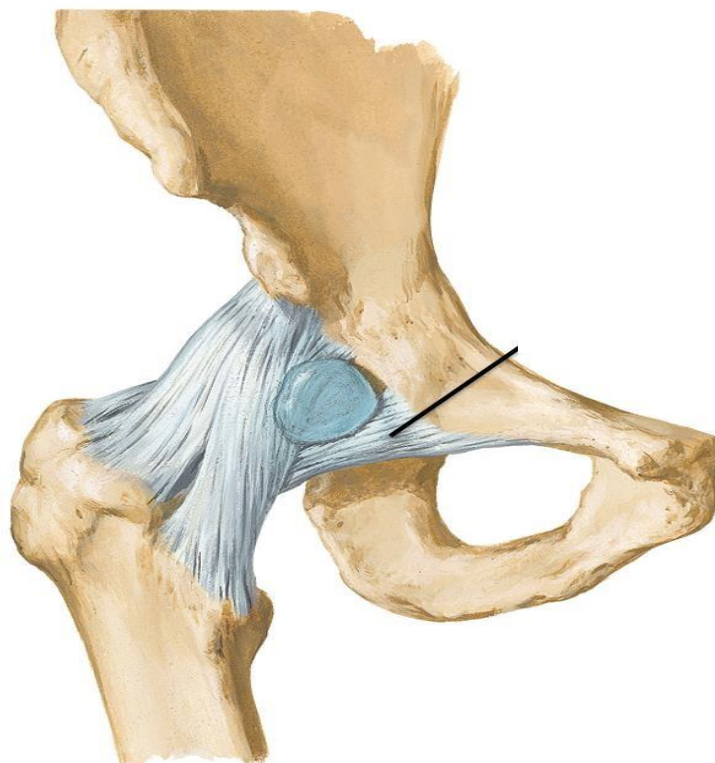
a- **Head of femur:** form 2/3 of a sphere (**ball**).

b- Horse-shoe **lunate articular surface** of the acetabulum of hip bone which becomes more deep by a fibrocartilaginous lip attached to the margin of the acetabulum called **labrum acetabular (socket).**



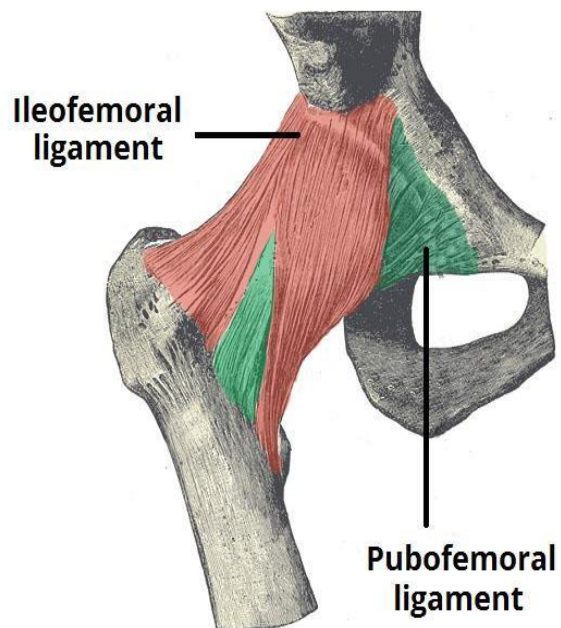


Anterior view

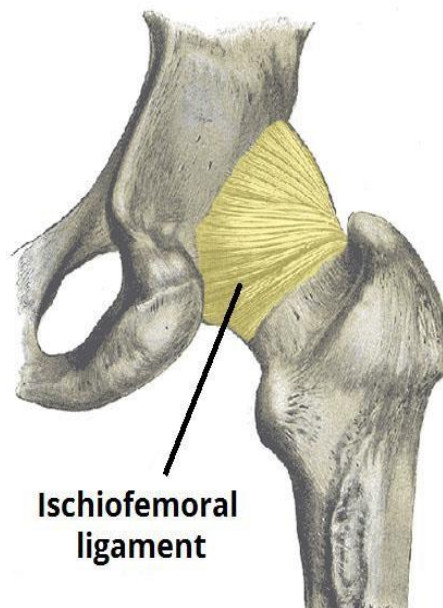


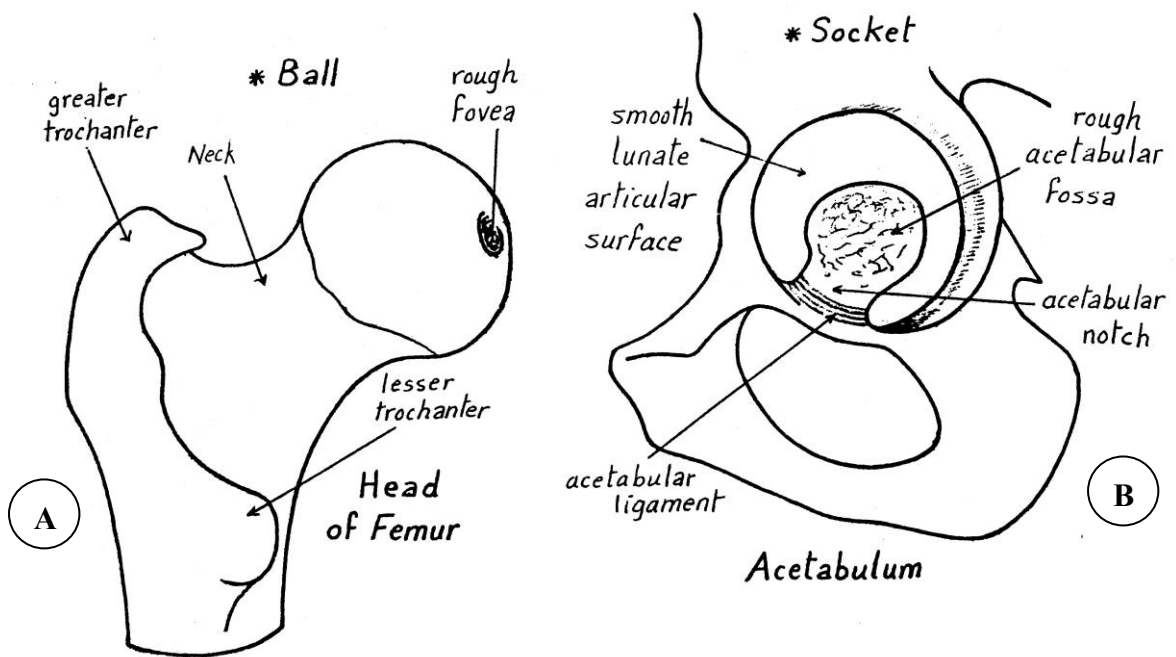
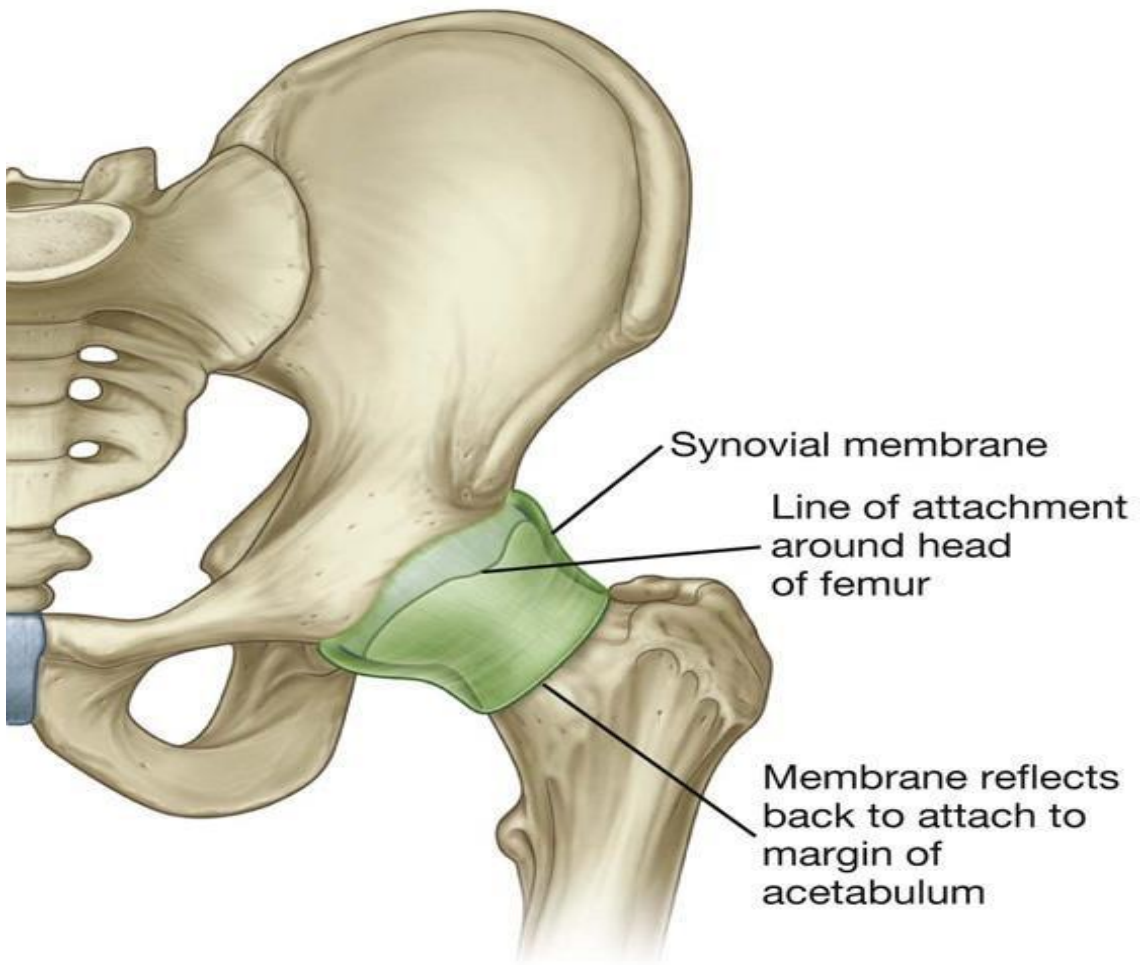
- ★ **Fibrous capsule:** a **strong** capsule surrounding the joint **completely**. The capsule is thick except at its lower medial part which is frequently the site of dislocation of the head of femur.
 - **Attachments:**
 - **To hip bone:**
 - ▢ To the margins of acetabulum (**beyond labrum acetabulare**).
 - ▢ To the **transverse acetabular ligament**.
 - **To femur:**
 - ▢ **Anteriorly:** To the intertrochanteric line and upper borders of greater and lesser trochanters.
 - ▢ **Posteriorly:** To the middle of the back of neck of femur.
 - ▢ Some fibers reflect from the capsule, called **retinacula** pass along the neck of femur towards its head. They carry blood supply to the head and neck of femur and also keep the segments of the fractured neck in position.
 - The anterior part of the capsule show opening between iliofemoral and pubofemoral ligaments through which the synovial membrane communicates with a bursa deep to psoas major.
- ★ **Synovial membrane:**
 - It **lines** the inner surface of the fibrous capsule.
 - It forms a **tubular sheath** for the ligamentum teres of the head of femur.
 - It **covers** the intracapsular part of the **neck** of femur and **labrum acetabular** but not cover the articular bony surfaces which are covered with hyaline cartilage instead.

Anterior

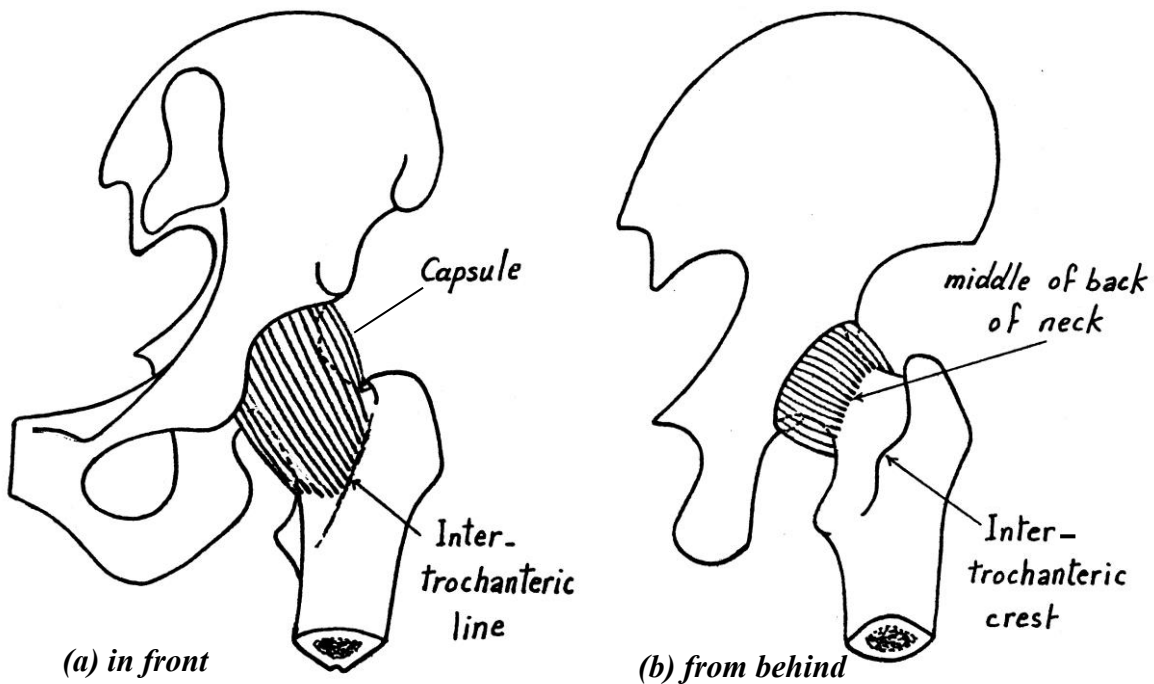


Posterior





Articulating bones of the hip joint



Attachments of the capsule of the hip joint

★ Ligaments of the hip joint:

- The capsule of the hip joint is strengthened by **three extracapsular ligaments.**

1) Ilio-femoral ligament:

○ **Attachments:** it is an inverted **Y**-shaped ligament.

- Its stem is attached to the **anterior inferior iliac spine**
- Its 2 limbs are attached to the upper & lower ends of the **intertrochanteric line.**

○ **Function:**

- It is the **strongest** ligament of the hip joint which in forces the **anterior** aspect of its capsule (it is the second strongest ligaments in the body after interosseus sacroiliac ligament) .

- It **limits over extension** of the joint and **prevents** the body from falling backwards (center of gravity of body weight lies behind hip joint).
- It helps in **transmission of body** weight.

2) Pubo-femoral ligament:

- **Attachments:** a **triangular** ligament, attached to the **iliopubic eminence** of the hip bone and blended to the **medial part** of the capsule and lower part of intertrochanteric line.
- **Function:** it supports the **infero-medial** part of the capsule, and limits over **abduction** of the joint.

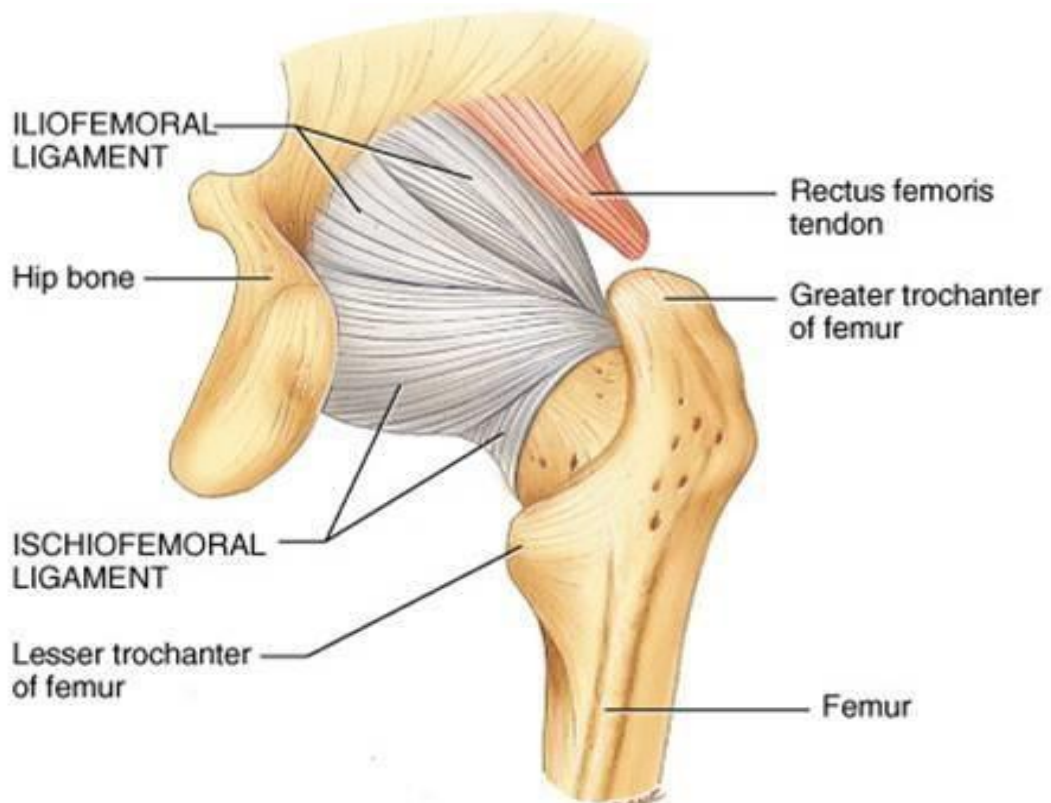
3) Ischio-femoral ligament: (weakest ligament of hip)

○ Attachments:

- It is attached to the **ischium below the acetabulum** and is blended to the **back of the capsule**.

○Function:

- It supports the **posterior part** of the capsule and limits excessive **medial rotation** & adduction of the hip joint which predispose to posterior dislocation of hip joint .



4) Transverse acetabular ligament :

- It is attached to the edge of the acetabular notch transforming it into a foramen which allows passage of nerves and vessels to the joint.

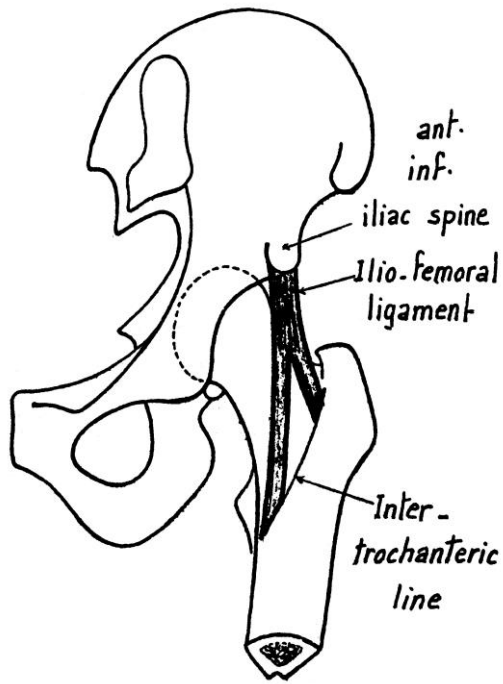
5) Ligament of the head of femur: (Ligamentum teres)

○ Attachments:

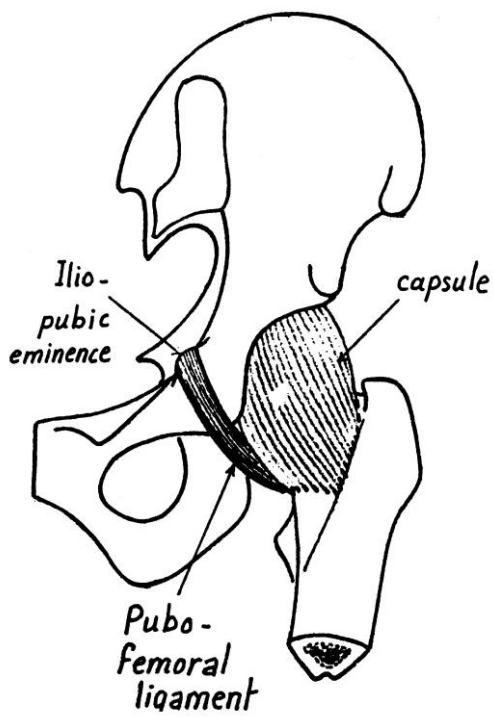
- * A **weak triangular** band lying inside the cavity of the hip joint **surrounded by** a synovial sheath (so it is **intracapsular but extrasynovial**).
- * Its **apex** is attached to a **fovea** on the head of femur.
- * Its **base** is attached to both sides of **acetabular notch** and to the **transverse acetabular** ligament. (which bridges the acetabular notch).

○ Function:

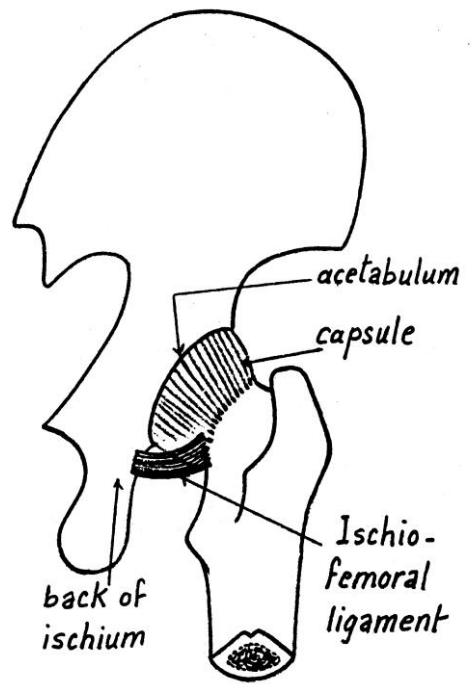
- * It allows the passage of **minor arterial** supply to the head of femur.



(a) Ilio-femoral ligament



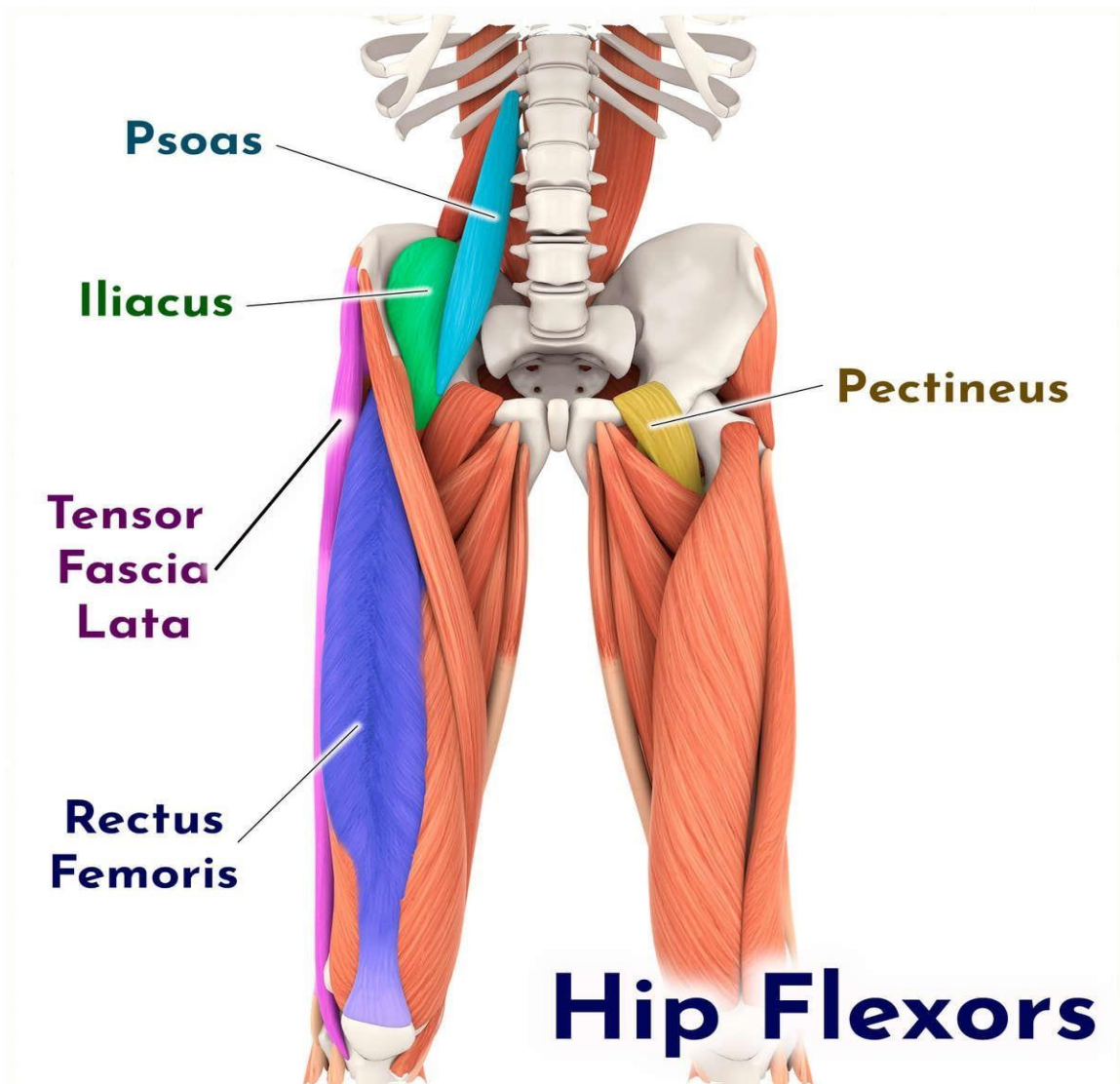
(b) Pubo-femoral ligament

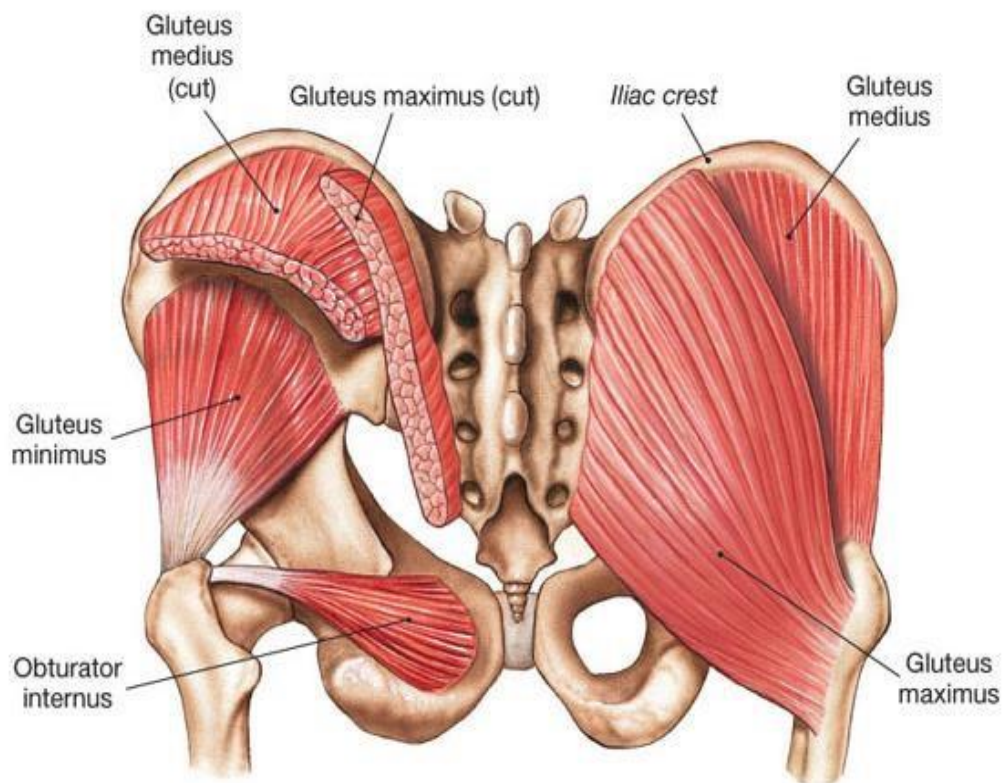
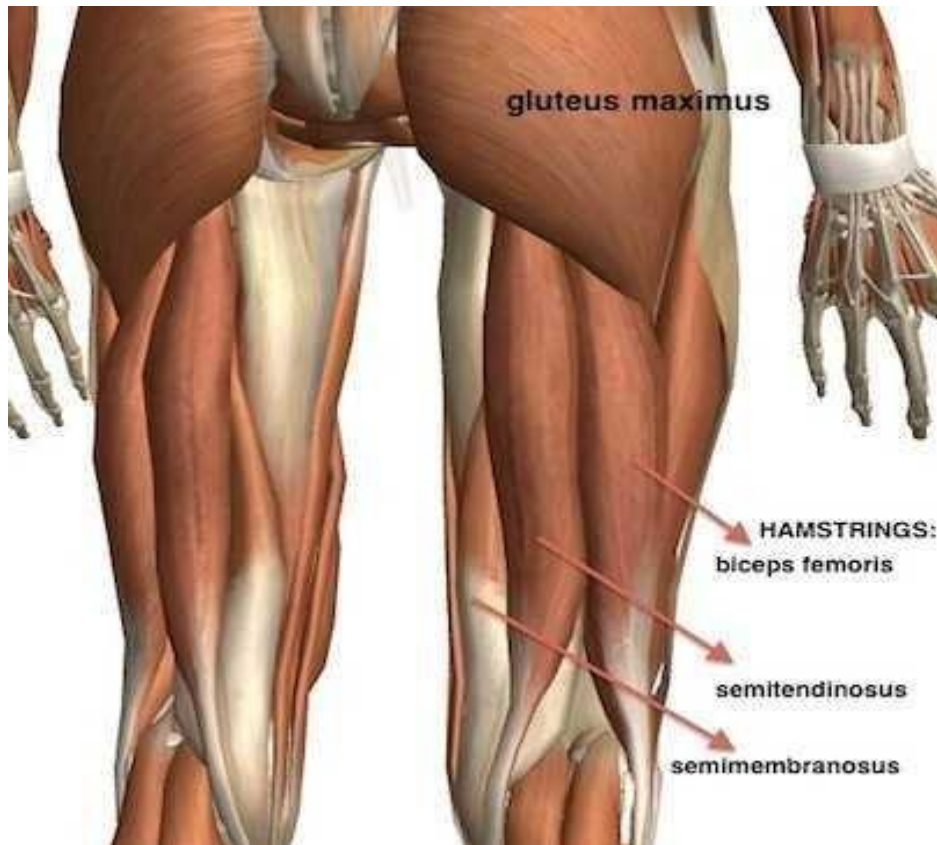


(c) Ischio-femoral ligament

Ligaments of the hip joint

- **Adduction:** done **mainly** by the 3 adductors (longus, brevis and pubic part of adductor magnus), **assisted** by gracilis and pectineus.
- **Abduction:** done **mainly** by gluteus medius and minimus, **assisted** by tensor fasciae latae.
- **Medial rotation:** done **mainly** by anterior fibers gluteus medius and minimus **assisted** by tensor fasciae latae.
- **Lateral rotation:** done **mainly** by the 6 lateral rotators of the thigh, **assisted** by gluteus maximus and sartorius.
- **Circumduction:** a combination of flexion, abduction, extension and finally adduction movements.





Types of Joints

Joint (articulation)— any point where two bones meet, whether or not the bones are movable at that interface.

Joints link the bones of the skeletal system, permit effective movement, and protect the softer organs.

Arthrology—science of joint structure, function, and dysfunction.

Joints classified according to the manner in which the bones are bound to each other.

Four major joint categories

- Bony joints
- Fibrous joints
- Cartilaginous joints
- Synovial joints

Bony joint

Bony joint—an immobile joint formed when the gap between two bones ossifies, and the bones become, in effect, a single bone.

- Examples:
 - Left and right mandibular bones in infants
 - Cranial sutures in elderly
 - Attachment of first rib and sternum with old age

Fibrous Joints

- Fibrous joint, synarthrosis, or synarthrodial joint

—adjacent bones are bound by collagen fibers that emerge from one bone and penetrate into the other.

Three kinds of fibrous joints

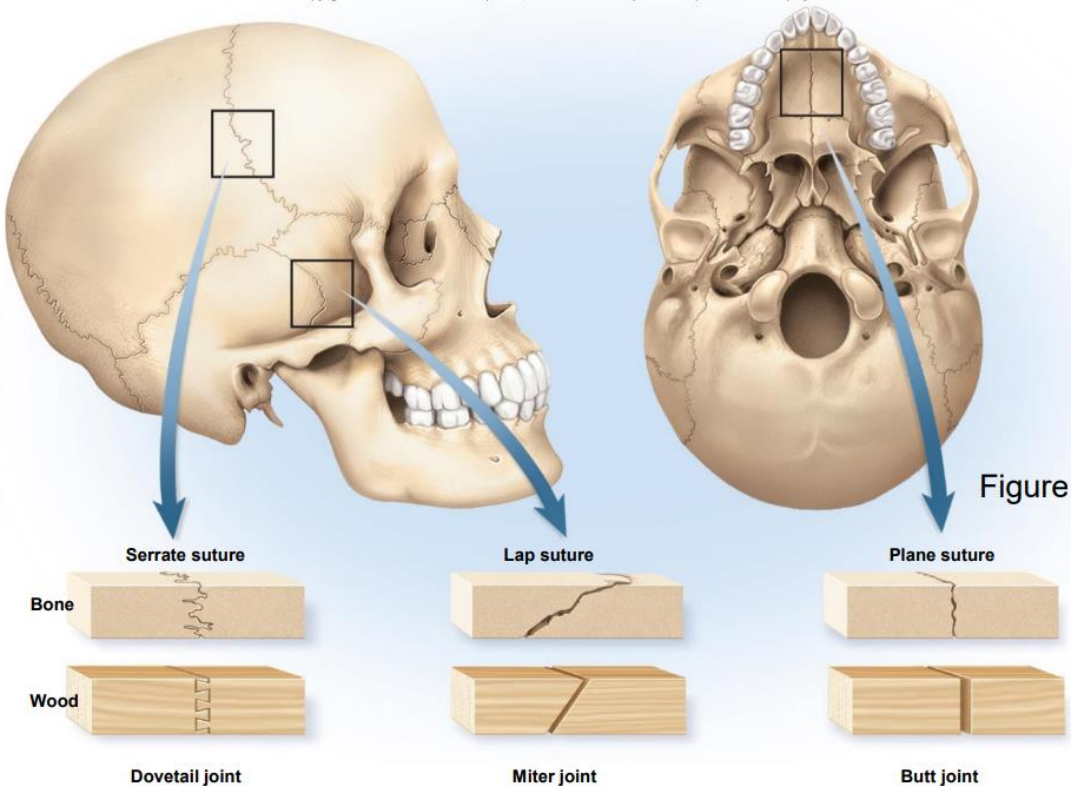
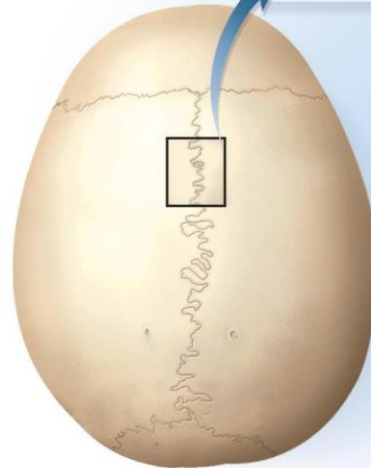
- Sutures
- Gomphoses
- Syndesmoses

Sutures—immobile or slightly mobile fibrous joints in which short collagen fibers bind the bones of the skull to each other •

Sutures can be classified as:

- **Serrate**: interlocking wavy lines • Coronal, sagittal, and lambdoid sutures.
- **Lap** (squamous): overlapping beveled edges • Temporal and parietal bones.
- **Plane** (butt): straight, nonoverlapping edges • Palatine processes of the maxillae.

Fibrous connective tissue



Gomphoses

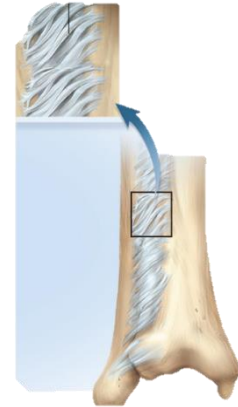
Gomphosis (fibrous joint)— attachment of a tooth to its socket.

Syndesmoses

—a fibrous joint at which two bones are bound by long collagen fibers.

Example of a very mobile syndesmosis: interosseus membrane joining radius to ulna allowing supination and pronation.

Example of a less mobile syndesmosis: joint between tibia to fibula.



Cartilaginous Joints

—two bones are linked by cartilage •

Two types of cartilaginous joints

– Synchrondroses

– Symphyses

Synchondroses

• Synchondrosis—bones joined by hyaline cartilage

– Temporary joints in the epiphyseal plates in children. Bind epiphysis to diaphysis.

– First rib attachment to sternum. Other costal cartilages joined to sternum by synovial joints.

Symphyses

• Symphysis—two bones joined by fibrocartilage

– Pubic symphysis joins right and left pubic bones with interpubic disc

– Bodies of vertebrae joined by intervertebral discs.

-Only slight movements between adjacent vertebrae.

-Collective effect of all 23 discs gives spine considerable flexibility.

