



**College of Health and Medical  
Technologies - Al-Dour  
Department of Physical Therapy  
The second stage**

# **Human anatomy**

**Ass.Lec .Muhanad Imad Majeed**

الجامعة التقنية الشمالية  
NORTHERN TECHNICAL UNIVERSITY



# Anatomy

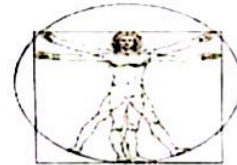
- **Definition** - anatome = up (ana) + cutting (tome)
- **Disciplines of anatomy**
  - Macroscopic
  - Microscopic
  - Developmental
  - Neuroanatomy
- **Approach to study of gross anatomy**

Upper extremity	Back
Head and neck	Thorax
Abdomen	Pelvis and perineum
Lower extremity	

## INTRODUCTION

### Anatomy

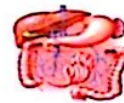- **Studies of the body parts and their relationships.**



### Macroscopic (Gross) Anatomy

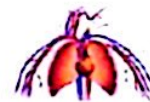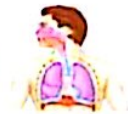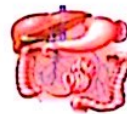- **Study of large body structure.**  
(e.g: heart, lungs, kidneys... etc.)
- can be further divided into:

1. **Regional Anatomy**  
- all structures in one particular region.

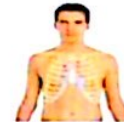

Cont..

2. **Systemic Anatomy**  
- system by system



3. **Surface Anatomy**  
- study of internal body structures



### Microscopic Anatomy

- **Very small structures that cannot be seen with naked eyes.**

1. **Cytology** \_\_\_\_\_  
- Study of body cells



2. **Histology** \_\_\_\_\_  
- Study of body tissues



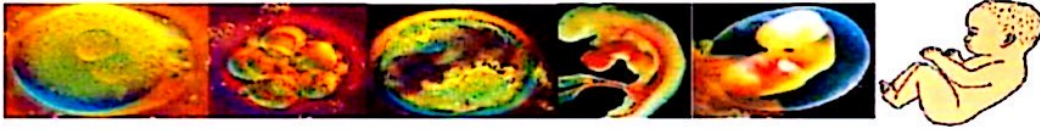


# Developmental Anatomy

- ◉ **Structural changes to the body throughout lifespan.**

## 1. Embryology

- Development which occur before birth



## SYSTEM OF THE BODY

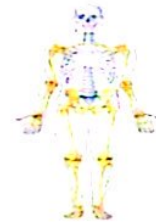
### ◉ Integumentary System

- External cover of the body (skin)
- Protects deeper tissues from injury
- Site of cutaneous, receptors, sweat and oil glands.



### ◉ Skeletal System

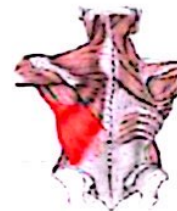- Bones
- Protects and supports body organs



## SYSTEM OF THE BODY

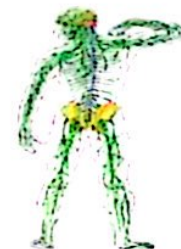### ◉ Muscular System

- muscles
- produce body movement



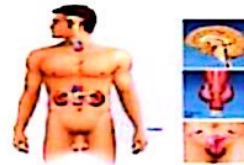### ◉ Nervous System

- consist of brain, sensory receptor, nerves, spinal cord
- control homeostasis by stimulating particular muscles contraction and glands secretion

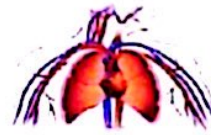

# SYSTEM OF THE BODY

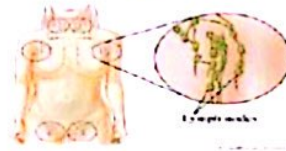- ⊙ **Endocrine System**
  - Hormones secretion to regulate body processes.



- ⊙ **Cardiovascular System**
  - Transport blood to the body

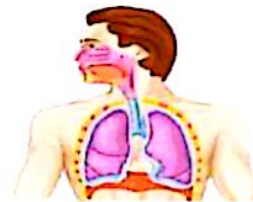

- ⊙ **Lymphatic/Immune System**
  - Protect the body by attacking foreign substances entering body system

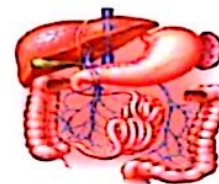


# SYSTEM OF THE BODY

- ⊙ **Respiratory System**
  - supply blood with oxygen and removing carbon dioxide.

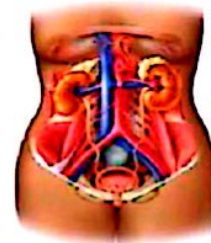

- ⊙ **Digestive System**
  - break down the food for absorption
  - indigestible food will be removed as feces

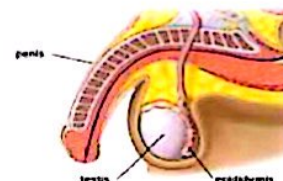
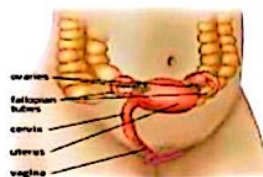


# SYSTEM OF THE BODY

- ⊙ **Urinary System**
  - regulation of water, electrolytes and acid-base balance in the body.



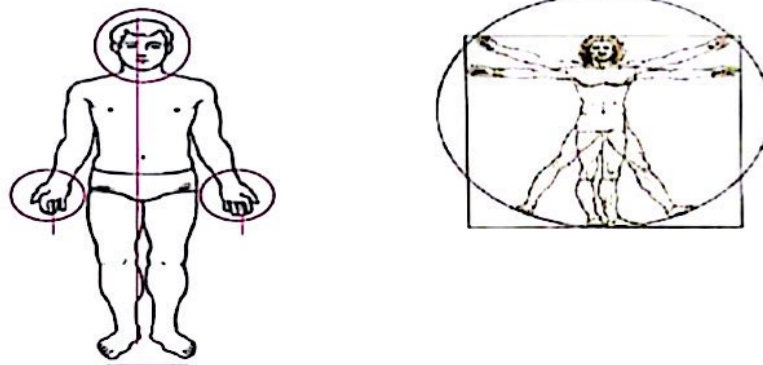
- ⊙ **Reproductive System**
  - production of babies





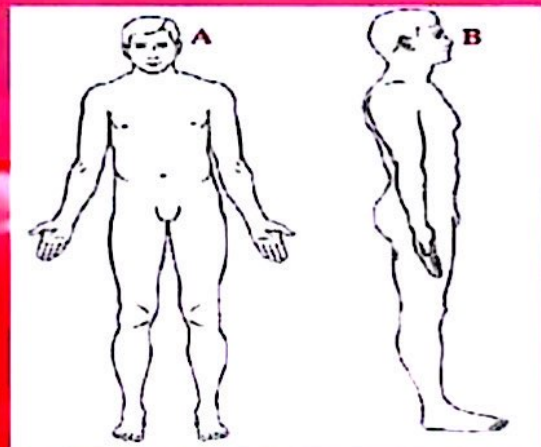
# ANATOMICAL POSITION

- ◉ Standing position with the body erect facing forward, feet slightly apart, arms hanging and palms also facing forward.



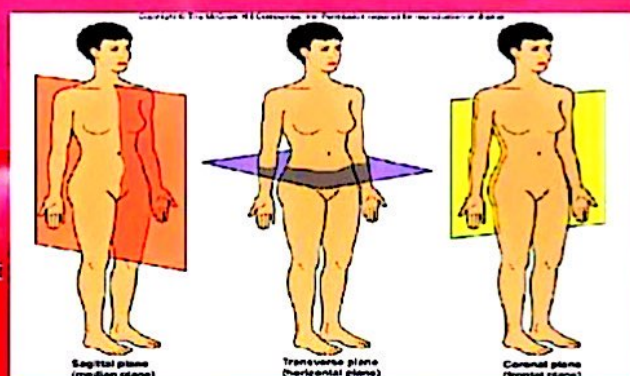
## Anatomical Position

- Body erect
- Head, eyes, toes directed forward
- Limbs at sides of body
- Palms directed forward



## Planes and Sections

- A plane is an imaginary flat surface that passes through the body.
- A section is one of the 2 surfaces (pieces) that results when the body is cut by a plane passing through it.



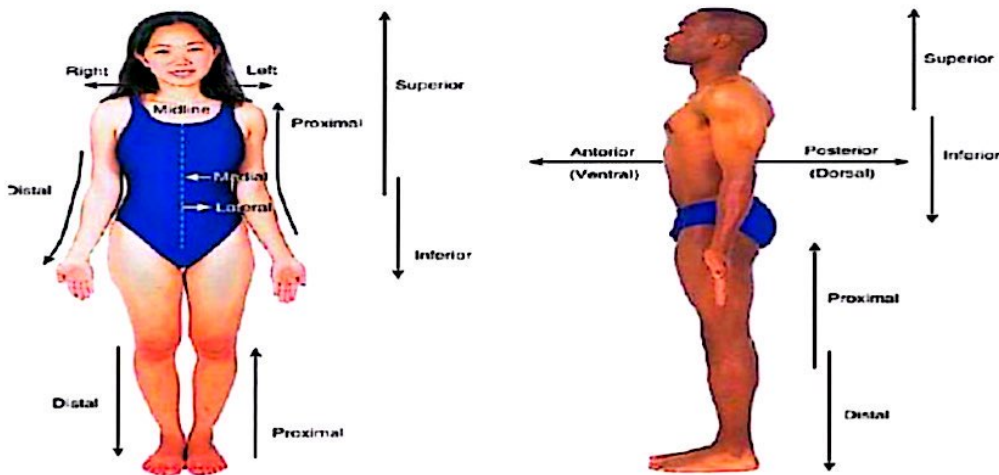


# DIRECTIONAL TERMS

- Explain and locate precisely where the body structure and it's relation to another.

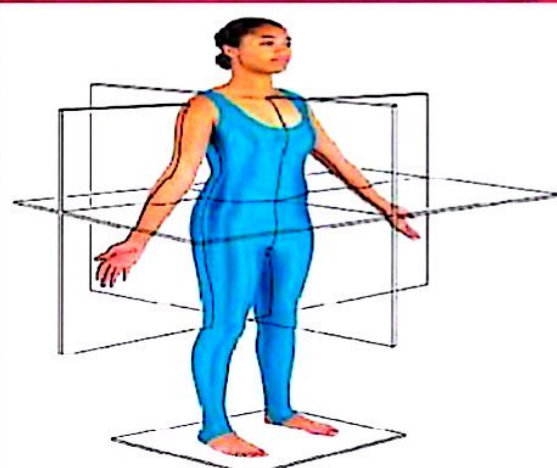
TERM	DEFINITION
Superior (cranial)	Toward head end, above
Inferior (caudal)	Away head end, below
Anterior (ventral)	Front of the body
Posterior (dorsal)	Behind the body
Medial	Midline of the body, inner
Lateral	Away from midline, outer
Intermediate	Between medial and lateral
Proximal	Close to body origin
Distal	Away from body origin
Superficial (external)	Toward body surface
Deep (internal)	Away body surface

# DIRECTIONAL TERMS



## Anatomical Planes

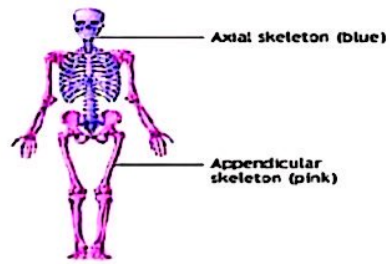
- Median = vertical, front to back in midline
- Frontal (coronal) = vertical, perpendicular to median
- Horizontal (transverse) - parallel to floor, perpendicular to median, coronal
- Sagittal = vertical, parallel to median
- Midsagittal (R-L)
- Parasagittal (unequal R-L)



## REGIONAL TERMS

### ⦿ Axial Region

- axis of our body
- comprise of three parts: head, neck and trunk



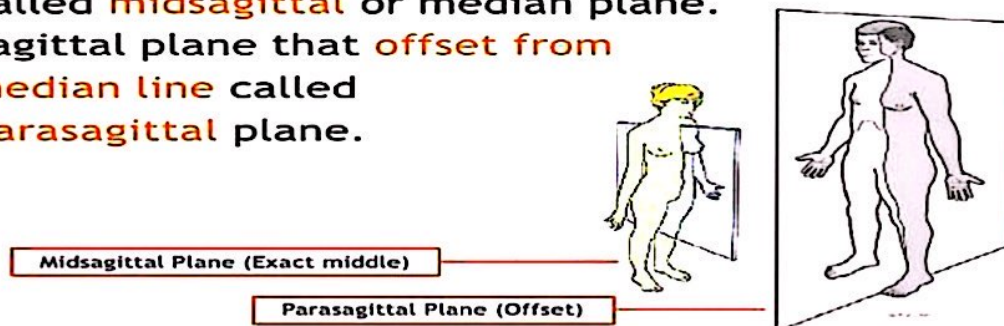
### ⦿ Perpendicular Region

- limbs, or appendages
- body parts that attached to the axis.

## BODY PLANES AND SECTIONS

### ⦿ Sagittal plane

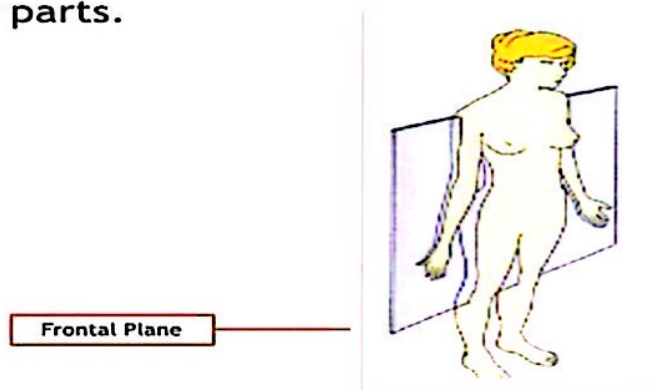
- Vertical plane divide body into **right and left**
- Sagittal plane that **exactly cut in the middle** called **midsagittal** or median plane.
- Sagittal plane that **offset from median line** called **parasagittal** plane.



## BODY PLANES AND SECTIONS

### ⦿ Frontal Plane

- vertical line that divide the body to **anterior** and **posterior** parts.



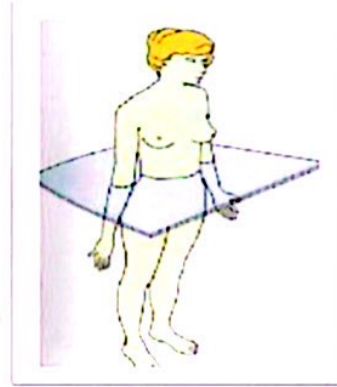


# BODY PLANES AND SECTIONS

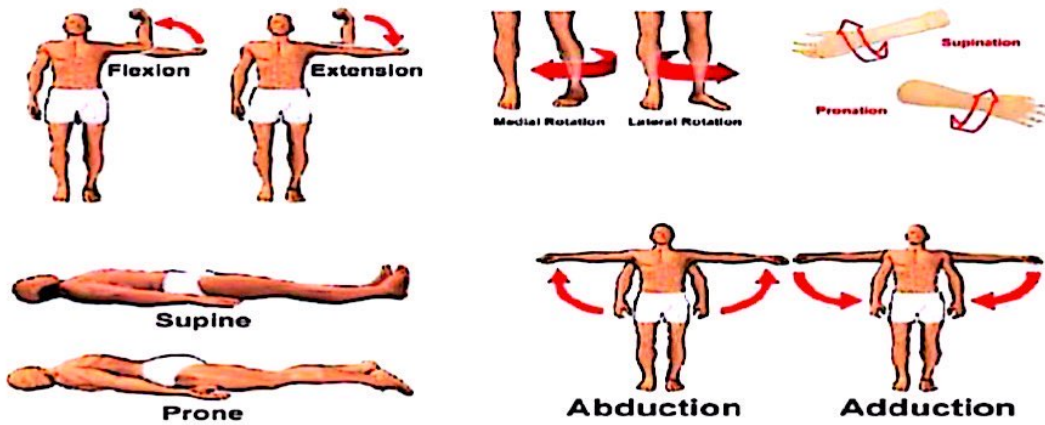
## ⊙ Transverse Plane

- horizontal plane which divide body into superior and inferior.

Transverse Plane

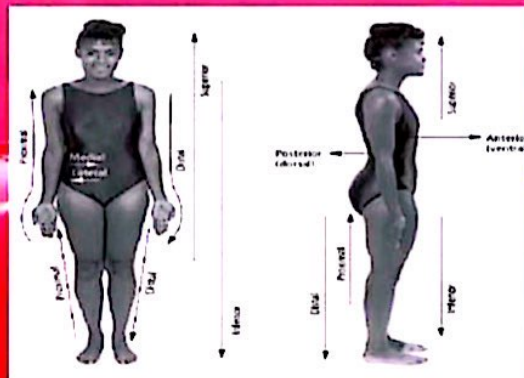


## TERMS OF MOTION



## Anatomical directional terminology

- Anterior
  - in front or in the front part
- Anteroinferior
  - in front & below
- Anterosuperior
  - in front & above
- Posterior
  - behind, in back, or in the rear
- Posteroinferior
  - behind & below; in back & below
- Posterolateral
  - behind & to one side, specifically to the outside



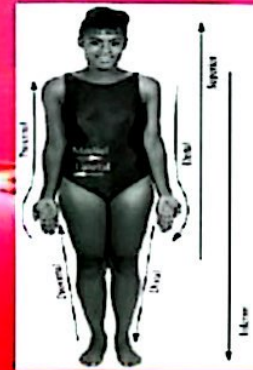


## Anatomical directional terminology

- **Contralateral**
  - pertaining or relating to the opposite side
- **Ipsilateral**
  - on the same side
- **Bilateral**
  - relating to the right and left sides of the body or of a body structure such as the right & left extremities

## Anatomical directional terminology

- **Inferior (infra)**
  - below in relation to another structure; caudal
- **Superior (supra)**
  - above in relation to another structure; higher, cephalic
- **Distal**
  - situated away from the center or midline of the body, or away from the point of origin
- **Proximal**
  - nearest the trunk or the point of origin
- **Lateral**
  - on or to the side; outside, farther from the median or midsagittal plane
- **Medial**
  - relating to the middle or center; nearer to the medial or midsagittal plane
- **Median**
  - Relating to the middle or center; nearer to the median or midsagittal plane



## Anatomical directional terminology

- **Caudal**
  - below in relation to another structure; inferior
- **Cephalic**
  - above in relation to another structure; higher, superior
- **Deep**
  - beneath or below the surface; used to describe relative depth or location of muscles or tissue
- **Superficial**
  - near the surface; used to describe relative depth or location of muscles or tissue



# Anatomical directional terminology

- Prone
  - the body lying face downward; stomach lying
- Supine
  - lying on the back; face upward position of the body
- Dorsal
  - relating to the back, being or located toward the back, posterior part, or upper surface of
- Ventral
  - relating to the belly or abdomen, on or toward the front, anterior part of
- Volar
  - relating to palm of the hand or sole of the foot
- Plantar
  - relating to the sole or undersurface of the foot

## Directional Terms

### • *Toward the upper part*

• *Superior Cephalic*

### • *Toward the lower part*

• *Inferior Caudal*

### • *Front*

• *Ventral Anterior*

### • *Back*

• *Dorsal Posterior*

## Directional Terms

### • *Front Down*

• *Prone*

### • *Toward Midline*

• *Medial*

### • *Away from Midline*

• *Lateral*

• *Same-Ipsilateral*

• *Opposite-Contralateral*

### • *Between*

• *Intermediate*

### • *Near*

• *Proximal*

# Directional Terms

- *Far*

  - *Distal*

- *On the Surface*

  - *Superficial*

- *On the Inside*

  - *Deep*

- *On the Wall of the Body Cavity*

  - *Parietal*

- *On an Organ*

  - *Visceral*

## BODY CAVITY

- ⊙ **Dorsal Cavity** - protects nervous system

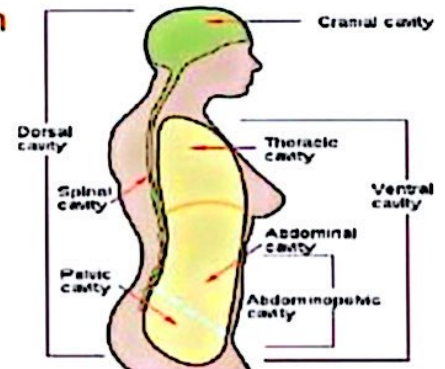
  - two subdivisions:-

1. **Cranial Cavity** - brain
2. **Spinal Cavity** - spinal cord

- ⊙ **Ventral Cavity** - houses visceral organs

  - two subdivisions:-

1. **Thoracic Cavity** - pleural (lungs), mediastinum (heart, esophagus, trachea, etc...)
2. **Abdominopelvic cavity** - abdominal (stomach, intestines, spleen, liver, etc...), pelvic (bladder, reproductive system, rectum)





# Functions

What are the major functions of the integumentary system?

- Protect
- Fluid balance
- Absorption
- Synthesis of Vitamin D
- Sensation/communication with external environment
- Thermoregulation
- Immunity
- Excretion

- 
- *Skin*
  - *Superficial fascia*
    - *Artery, Vein, Nerve*
  - *Deep fascia*
  - *Muscles*
  - *Bones*
  - *joints*

---

## Introduction to

➤ **Skin.**

➤ **Fascia.**

- **Superficial Fascia**
- **Deep Fascia**

# Structure of the skin

Superficial epithelial layer  
(epidermis)



Deep connective tissue layer  
(dermis)

Deep to the dermis is the Hypodermis :subcutaneous tissue  
(superficial fascia)

## Structure of the skin

### Epidermis

- Keratinized stratified squamous epithelium devoid of blood vessels

### Dermis

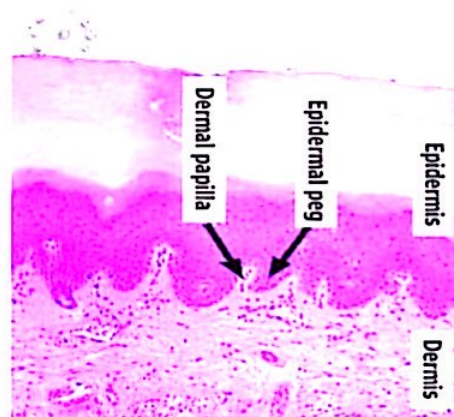
- Connective tissue containing (bl. v. lymph v., sensory nerve endings, smooth m, hair follicles, sweat and sebaceous glands)
- In its deep part the collagen bundles are arranged in parallel rows

## Skin

- Layers of skin
- Epidermis
- Five type of layers
- Dermis
- Two type of layers

### Junction

- Dermal papilla
- Epidermal peg (*rete pegs*)

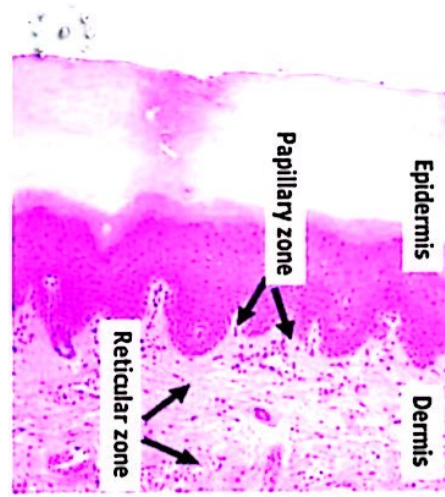


Scanned with CamScanner

## Skin.....

### Dermis

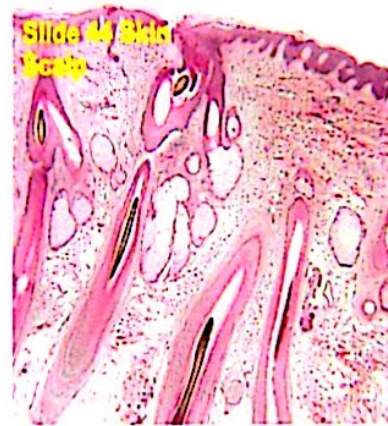- **Papillary layer**
- Tactile papilla
- Vascular papilla
- Collagen fibre
- **Reticular layer**  
Collagen fibre
- Sweat glands
- Sebaceous glands
- Hairs



---

## Skin.....

- **Thick skin**  
-No hairs
- **Thin skin**
- **Devoid of Stratum lucidum**



---

**Fascia**



# Fascia

Collection of connective tissue

**Superficial fascia**

**Deep fascia**

---

## Superficial fascia

### Superficial fascia:

- Loose, mixture of adipose and loose areolar tissues.
- It unites the skin to the underlying structures.
- It is dense in some places as scalp, palm of hand and sole of foot and contains collagen bundles
- It is thin in the eyelids, auricle, scrotum, penis and clitoris (devoid of adipose tissue).

### Functions:

- Facilitates movement of skin over underlying structures.
- Passage for cutaneous vessels, nerves...

Protects the body against heat loss.

---

## Superficial Fascia

- Site with Very less fat
  - Eyelids
  - Pinna
  - Penis
- Site with more fat
  - Breast
  - Abdomen
  - Gluteal region

# Deep fascia

- It is more dense than superficial fascia
- Collagenous bundles are more compact and more regularly arranged
- It is usually present in the form of membranes

---

## Examples of deep fascia

### A. Investing fascia

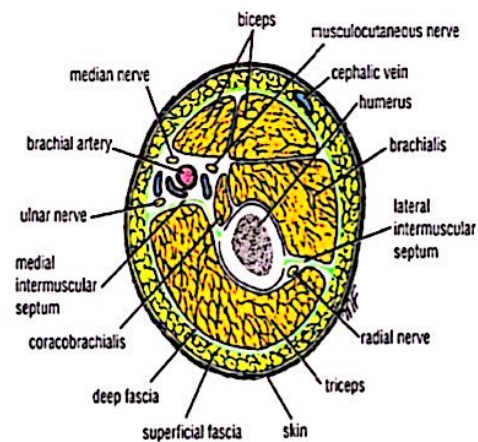
- Covers the surfaces of muscles
- In the neck: it forms well-defined layers, bounds fascial spaces so limits spread of infection or determine the path of infection
- In the abdomen: it is thin
- In the limbs: forms a definite sheath around the muscles

---

Examples of deep fascia.....

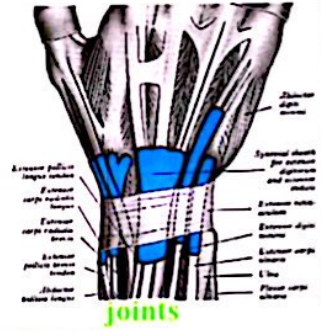
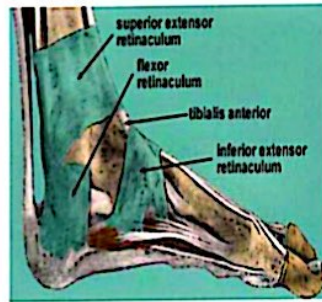
### B. Inter muscular septa

lie between muscles dividing the limb into compartments





## C. Retinacula



prevent bowstringing

---

Examples of deep fascia.....

- **Fibrous sheath**
  - eg. *Carotid sheath Axillary sheath*
- **Fibrous capsule**
  - eg Parotid capsule
- **Ligaments**

---

## Absence of deep fascia

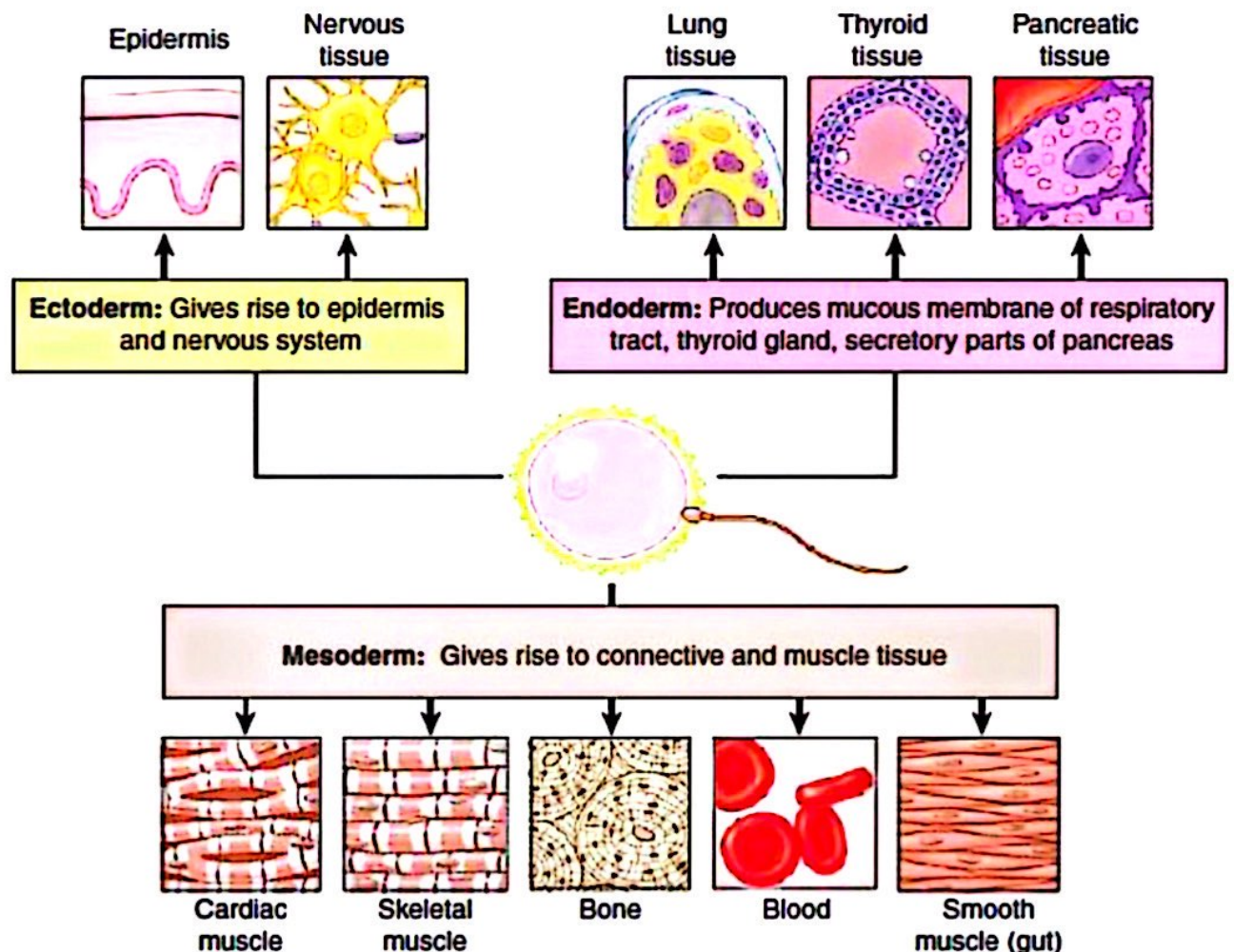
- **Face**
- **Breast**
- **Penis**
- **Anterior abdominal wall**

## TISSUES

Although the human body contains trillions of cells, all of those cells can be categorized as belonging to one of four distinct groups of tissue. Tissues are simply groups of similar cells that perform a common function. The four categories of tissue are **epithelial, connective, nervous, and muscular**.

Immediately after an egg and sperm unite to form a single cell, the cells begin to divide rapidly. At first, all the cells are identical.

Soon, the cells organize into three layers: the **ectoderm** (outer layer), the **mesoderm** (middle layer), and the **endoderm** (inner layer). The cells of each layer continue to divide, becoming increasingly distinct from the cells of the other layers. Eventually each layer gives rise to the different types of tissue, a process called **differentiation**.



## Epithelial Tissue

**epithelial tissue** is a continuous sheet of tightly packed cells; it covers the body's surface, lines the body cavities and many of the organs, and forms certain glands.

**The key functions of this tissue involve protection, absorption, filtration, and secretion.**

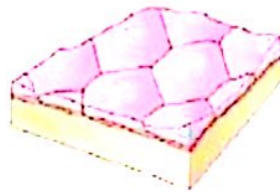
In a sense, the epithelium is a *surface* tissue: its top surface is usually exposed to the environment—such as occurs with the skin or the inside of the mouth—or to an internal body cavity; its bottom surface adheres to underlying connective tissue by means of a **basement membrane**. Epithelial tissue is too thin to contain blood vessels; therefore, it depends on the connective tissue beneath to supply its needs for oxygen and nutrients. Epithelial tissue is classified by the shape of the cells as well as by the number of layers.

### Cell Shape

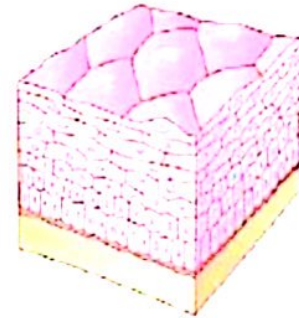
Epithelial cells may assume one of three basic shapes: **squamous, cuboidal, or columnar**

### Cell Layers

Epithelia may appear as single or multiple layers.



In simple epithelia, every cell touches the basement membrane.



In stratified epithelia, some cells stack on top of other cells and the upper layers of cells don't touch the basement membrane.

### Glandular Epithelium

There's another type of epithelium: **glandular epithelium**. A gland is a collection of epithelial cells that specializes in secretion of a particular substance.

- **Exocrine glands** secrete their products (such as tears, sweat, or gastric juices) into ducts. The ducts then empty onto a body surface or inside a body cavity. For example, sweat glands secrete sweat, which flows through ducts and onto the skin's surface.

- **Endocrine glands** are often called ductless glands. These glands secrete their products, called hormones, directly into the blood. For example, the adrenal glands secrete epinephrine and norepinephrine into the bloodstream.

**Goblet cells** are modified cells containing secretory vesicles that produce large quantities of mucus



## Connective Tissue

The most widespread, and the most varied, of all the tissues is **connective tissue**. Existing in a variety of forms—ranging from tough cords to elastic sheets to fluid—connective tissue performs a variety of tasks **INCLUDING connect the body together and to support, bind, or protect organs**.

The key component of connective tissue—called **extracellular matrix**—Extracellular matrix is the framework into which the cells of tissue are embedded. The matrix consists of varying kinds and amounts of protein fibers and fluid; it's the variation in composition that gives tissue its characteristics. For example, the matrix of blood is fluid; it contains many cells but no fibers. In contrast, the matrix of bone contains few cells and many fibers, making it hard and brittle. The matrix may also be gel-like, flexible, tough, or even fragile.

The fibers found in connective tissue may be one of three types:

- **Collagenous fibers:** These are strong and flexible but resist stretching; these are the most abundant fibers.
- **Reticular fibers:** These occur in networks and support small structures such as capillaries and nerve fibers.
- **Elastic fibers:** Made of a protein called *elastin*, these fibers can stretch and recoil like a rubber band.

### Types of Connective Tissue

Type	Location	Function
<b>1-Loose fibrous connective</b>		
• Areolar	Beneath the epithelia; between muscles; surrounding blood vessels and nerves	Connects tissues and organs together (such as skin to muscles)
• Adipose	Beneath the skin, breast, heart's surface; surrounding kidneys and eyes	Provides protective cushion, insulation; stores energy
• Reticular	Spleen; lymph nodes; bone marrow	Provides a supportive framework
<b>2-Dense fibrous connective</b>	Tendons; ligaments; fascia; dermis of the skin	Provides durable support
<b>3-Cartilag</b>		
• Hyaline	Ends of bones in joints; connecting point between ribs and sternum; rings in trachea and bronchi; larynx; fetal skeleton	Eases joint movement; firm but flexible support
• Elastic	External ear	Provides flexible support
• Fibrocartilage	Intervertebral discs; knee joint; pelvis	Resists compression and absorbs shock
<b>4-Bone</b>	Skeleton	Provides support, protection; serves as calcium reservoir
<b>5- Blood</b>	Inside blood vessels throughout the body	Transports oxygen, nutrients, hormones, wastes from one part of the body to another

## Nervous Tissue

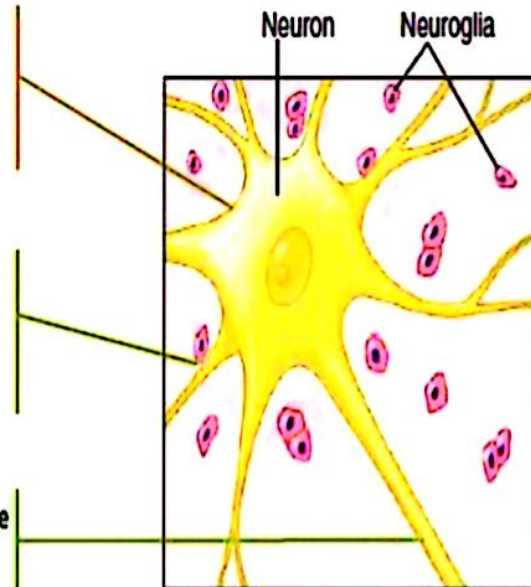
Nervous tissue has a high degree of excitability and conductivity—more so than other tissues. It's these characteristics that allow it to communicate rapidly with other parts of the body. Found in the brain, spinal cord, and nerves, nerve tissue consists of two types of cells:

- **Neurons**, the units that conduct nervous impulses
- **Neuroglia**, which protect and assist neurons.

Each neuron has a large cell body, called a **soma**. The soma contains the nucleus of the nerve cell as well as the organelles.

Extending from the soma are multiple, short processes called **dendrites**. The dendrites receive impulses from other cells, which they then transmit to the soma.

The neuron contains a single, long nerve fiber called the **axon**. The axon transmits signals to other cells.



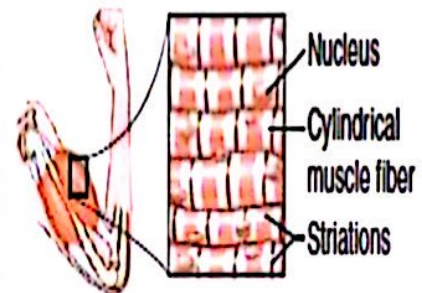
## Muscle Tissue

Muscle tissue consists of elongated cells that contract in response to stimulation. The body contains three types of muscle tissue: skeletal, cardiac, and smooth.

### Skeletal Muscle

consists of long, thin cells called **muscle fibers**. Skeletal muscle may also be called *striated* muscle (because its light and dark bands give it a striped, or striated, appearance) or *voluntary* muscle (because we can move it voluntarily).

Most skeletal muscle is attached to bone. This is the muscle that makes body movements possible. It is also the muscle responsible for breathing, speech, control of urination, and facial expression.



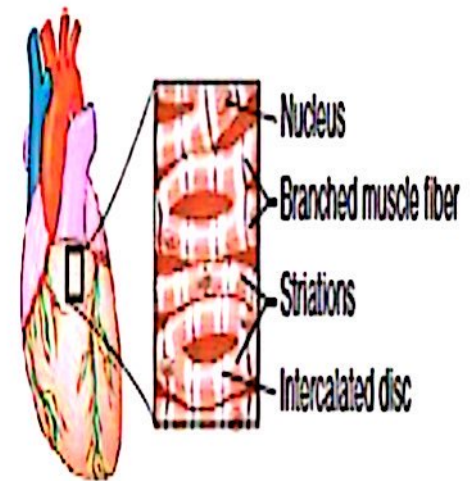


### Cardiac Muscle

found only in the heart. While cardiac muscle also appears striated, it is uniquely different from skeletal muscle. For one thing, cardiac muscle cells are shorter than those of skeletal muscle.

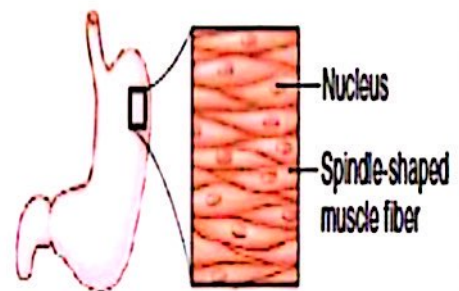
In addition, the cells are joined together with junctions called **intercalated discs**.

These junctions allow electrical impulses to spread rapidly from cell to cell; this rapid transmission permits almost simultaneous stimulation and contraction. Finally, cardiac muscle is *involuntary* muscle: its contraction is not under voluntary control.



### Smooth Muscle

consists of long, spindle-shaped cells—lacks the striped pattern of striated muscle. smooth muscle is not under voluntary control. This muscle lines the walls of many organs, including those of the digestive, respiratory, and urinary tracts. Smooth muscle controls the diameter of blood vessels, making it important in controlling blood pressure and flow.



## Membranes

Thin sheets of tissue, called **membranes**, fulfill many crucial functions in the body. In general, membranes line body cavities, cover body surfaces, and separate organs (or parts of organs) from each other. Some membranes secrete lubricating fluids to reduce friction during movement, such as when the heart beats or a joint bends. The two categories of membranes are **epithelial membranes** and **connective tissue membranes**.

### Epithelial Membranes

The body contains three types of epithelial membranes: mucous membranes, cutaneous membranes, and serous membranes.

#### 1. Mucous membranes

Mucous membranes line body surfaces that open directly to the body's exterior, such as the respiratory, digestive, urinary, and reproductive tracts. True to the name, mucous membranes secrete **mucus**, a watery secretion that coats and protects the cells of the membrane. Mucus also acts as a lubricant to help propel food through the digestive tract; in the respiratory tract, it traps dust and bacteria.

#### 2 Cutaneous membrane

Known as the skin, this is the body's largest membrane. It consists of a layer of epithelium resting on a layer of connective tissue.

#### 3 Serous membranes

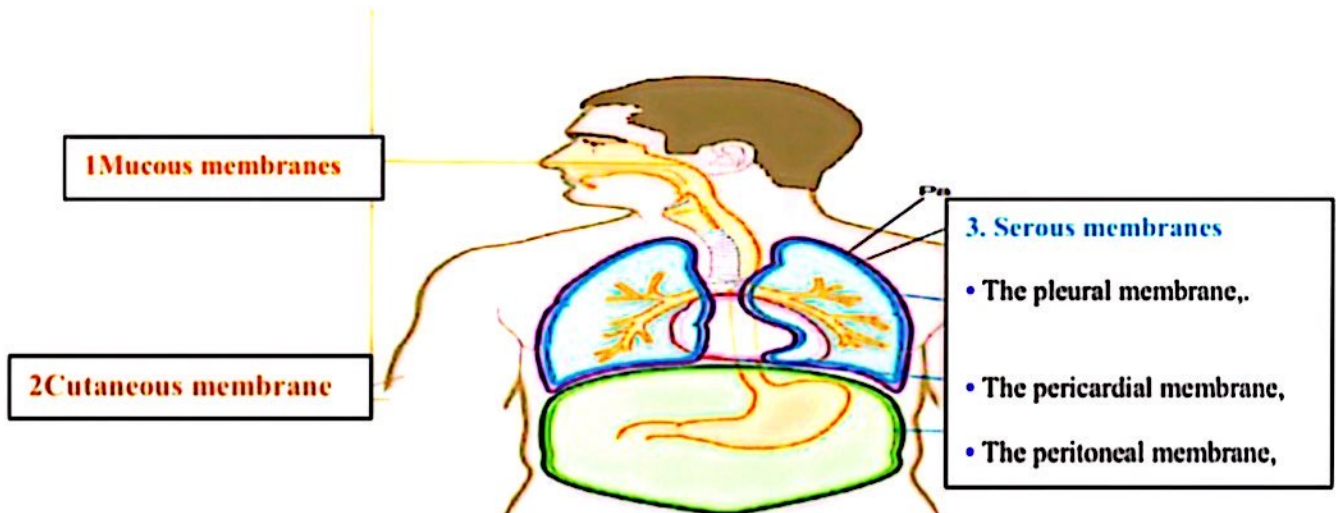serous membranes line some of the closed body cavities and also cover many of the organs in those cavities. The serous membrane that lines the body cavities is



actually one continuous sheet: part of the membrane (called the *parietal membrane*) lines the wall of the cavity; it then folds back and covers the organs. The part of the membrane that covers the organs is called the *visceral membrane*. There are three serous membranes:

- The , or pleural membrane, surrounds each lung and lines the thoracic cavity.
- The , or pericardial membrane, surrounds the heart.
- The , or peritoneal membrane, lines the abdominal cavity and covers the abdominal organs.

Serous membranes secrete serous fluid, which helps prevent friction as the heart beats and the lungs expand.



### Connective Tissue Membranes

Some joints are lined by membranes made of connective tissue. For example, **synovial membranes** line the spaces between bones, where they secrete synovial fluid

# Human anatomy

**Human anatomy:** including histology and gross human anatomy, is the study of the structures of the human body.

Most health care related studies require some or extensive training in gross anatomy and histology. Examples include people preparing to become paramedics, physical therapists (UK: physiotherapists), occupational therapists, medical doctors, orthoptists, prosthetics, and biological scientists. Medical students will be required to do practical anatomical work, which involves dissection and inspecting cadavers.

## Digestive system

**Digestive system:** is made up of a group of organs working together. The digestive tract is made up of the mouth, esophagus, stomach, small intestine, and the large intestine. There are also associated organs that support the digestive tract.

### Parts of the human digestive system:

**1- Mouth:** the first of the digestive tract the entry point of the food, the smell and sight of food, stimulates salivary glands to secrete fluid called saliva (consisting of water and enzymes).

**Salivary glands:** are glands in the mouth that produces saliva to begin the chemical digestion of food.

**The purpose of the saliva** is to lubricate the food for swallowing, dissolve water soluble food particles, and start chemical digestion of carbohydrates (starch) into smaller molecules.

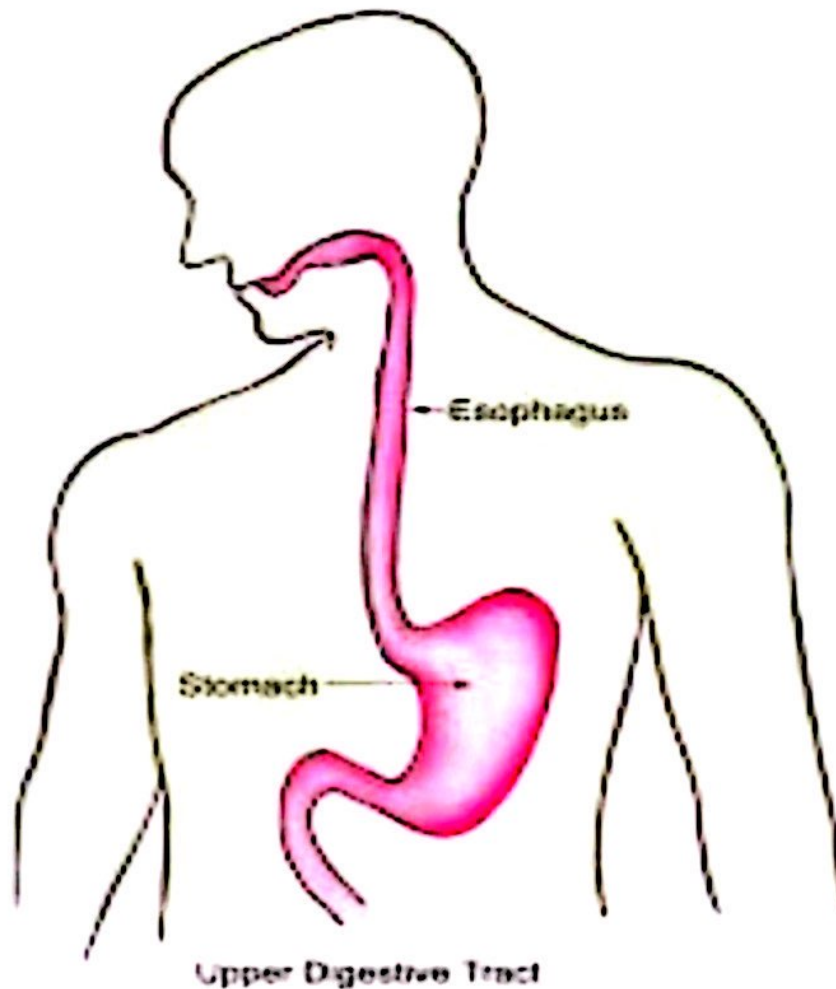
**2- Esophagus:** muscular tube that connecting the mouth to the stomach running through the **thoracic cavity**. the site of esophagus lies behind trachea.

**The trachea:** has an epiglottis which prevents food from entering the trachea, moving the food to the esophagus while swallowing.

**Food** travels down the esophagus, through a series of rhythmic contractions (wave-like ) called **peristalsis**.

The lining of the esophagus secretes mucus, lubricating to support the movement of food.

The end of esophagus linked with the upper part of stomach by cardiac sphincter, its muscular ringed valve, the role of sphincter is to prevent stomach acids from back flowing in to the esophagus creating a burning feeling known as heart burn.



Section of esophagus

iv

**3- The Stomach:** the stomach is a muscular J- shaped organ found in the **abdominal cavity** . food is temporary stored in the stomach.

The Stomach is consists of **three layers of muscle fibers** which performs mechanical digestion by churning the food and **mixing it with the gastric juices,**( Hcl , salts, enzymes ,water and mucus ) secreted by the **lining** of the stomach .



## **The stomach does not digest itself because of three protective mechanisms:**

**First mechanisms** / the stomach only secretes small amounts of gastric juices until food is present .

**Second mechanisms** / the secretion of mucus coats the lining of the stomach protecting it from the gastric juices.

**Third mechanisms** / the digestive enzyme pepsin is secreted in an inactive protein called pepsinogen.

\***Pepsinogen** is converted to **pepsin** in the increased presence of hydrochloric acid (pH 1).

\***Chyme**- is a thick liquid produced in the stomach and made of digested food combined with gastric juice.

The lower part of stomach linked with **small intestine** by muscular ringed sphincter called the **pyloric sphincter**.

## **4- Small intestine :**

The small intestine is responsible for the complete digestion of all macromolecules and the absorption of their component molecules (glucose, fatty acids, amino acids).

### **The small intestine up of three parts:**

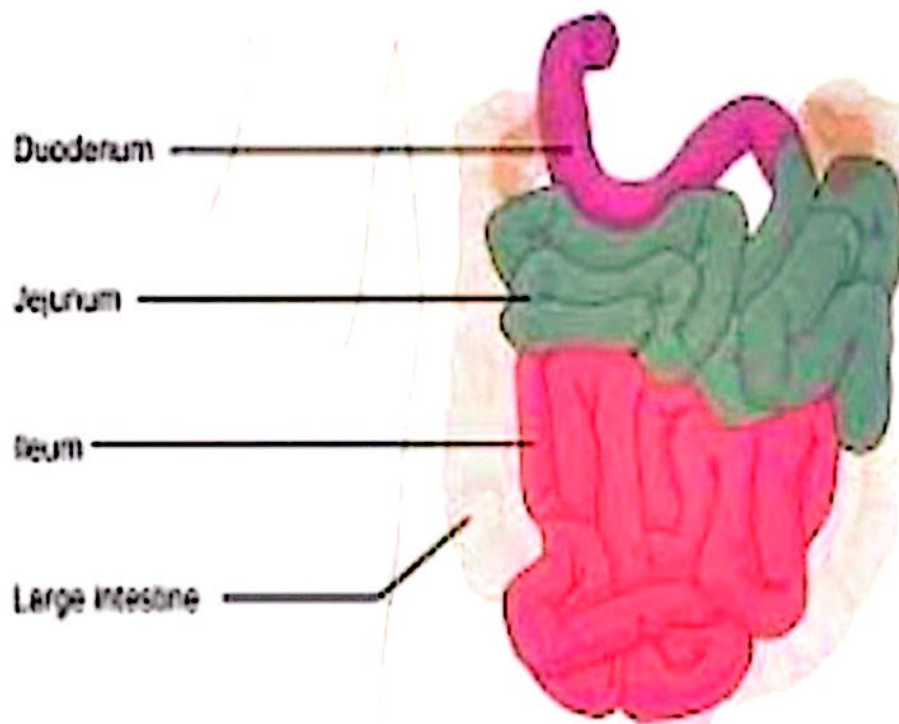
1. **Duodenum** : it's a first part, U shaped organ, length 30cm approximately, the area completes most of the digestion process.

**Enzymes** are secreted into the duodenum from the pancreas and gall bladder.

**The duodenum** lined by folds of villi, the villi are covered by microvilli its increase the surface area of the small intestine **increase the rate of absorption**.

2. **The jejunum** : the long 2.5m approximately. although some digestion is completed here it has more villi and microvilli, its role is absorption for nutrients.

3. **The ileum** : the long 3m approximately and has fewer villi and microvilli, its responsible for pushing the waste materials in to the large intestine .

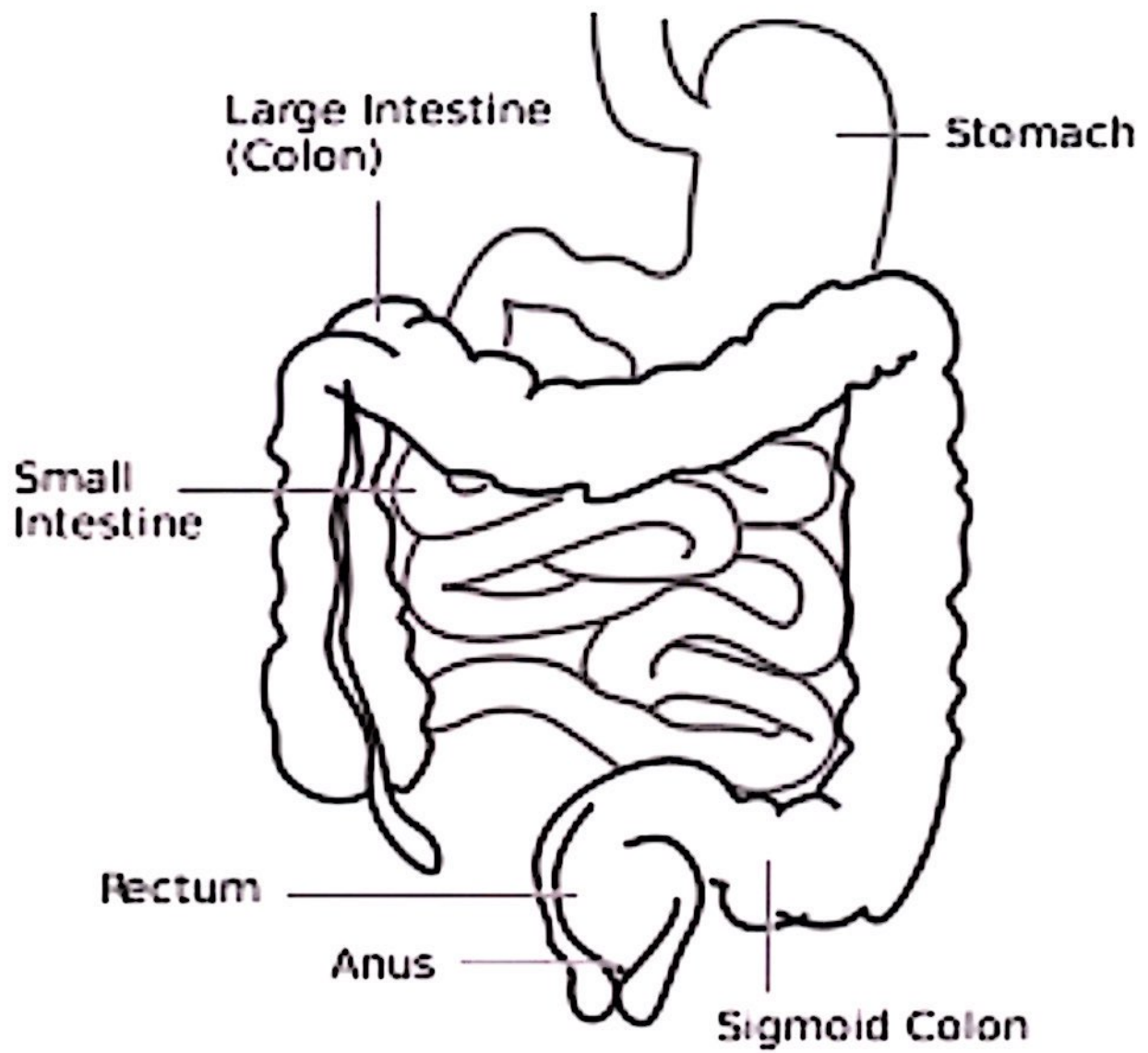


### **Small intestine section**

- 5- **Large Intestine/** the waste material move from the small intestine and moves in to large intestine it consist of:
- a- **Ascending colon.**
  - b- **Transverse colon.**
  - c- **Descending colon.**

**The large intestine** is approximately 1.5m, in length. the 90% of water is reabsorbed back in to the blood stream. The anaerobic bacteria in the colon breaks down the waste material producing **vitamins, folic acid, B vitamins and vitamin k**, which is transported to the blood stream.

**The rectum** stores the fecal matter until eliminated by the anus.



**Section of Large Intestine**

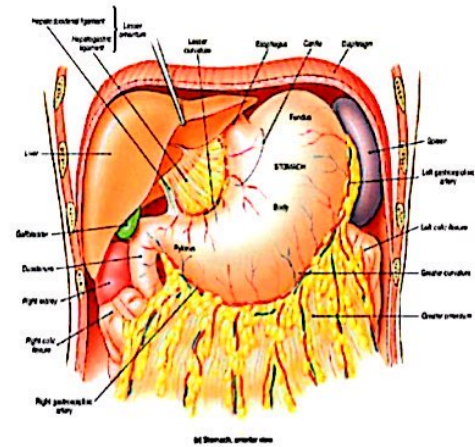


# Liver

- It stores some nutrients, and releases them into the blood according to the activities and needs of the body.
- Situated in the right side of the abdomen

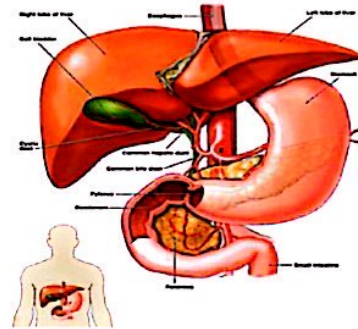
## Basic Structure:

- Capsule – thin connective tissue (Glisson's capsule)
- Stroma – reticular tissue & collagen
- Parenchyma – hepatocytes



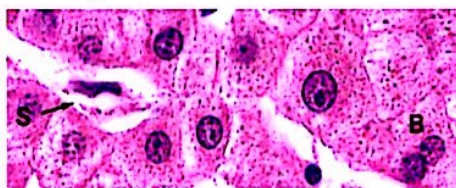
## Functions of Liver

- Storage & filtration of blood
- Metabolism of carbohydrates, fats & proteins
- Breakdown of toxins, drugs
- Synthesis & secretion of bile
- Synthesis of plasma proteins, clotting factors.



## Liver cells, organelles & their function

- **SER** – bile formation, drug detoxification, Glucose metabolism.
- **RER** – protein synthesis.
- **Mitochondria** – drug detoxification.
- **Hepatocytes**: Polyhedral cells with 1-2 rounded nuclei with eosinophilic cytoplasm. Have numerous cell organelles: Mitochondria, SER, RER & Lysosomes.



# Bile

- Exocrine secretion of the liver, which flows from the gall bladder along the bile duct into the intestine to aid in chemical digestion.

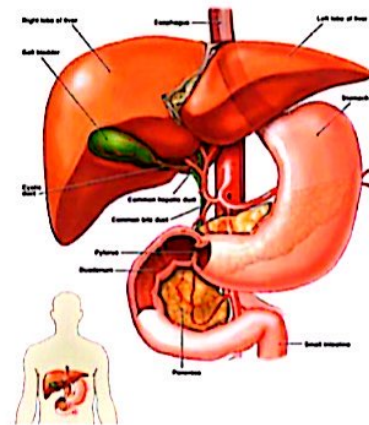
## Consists of:

- Water & electrolytes.
- Cholesterol & phospholipids.
- Bile salts
- Bile pigments

---

## Gall Bladder

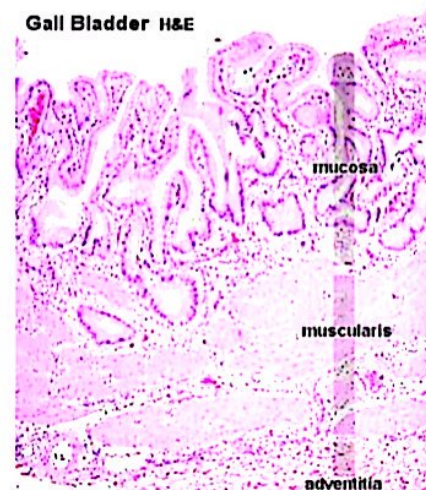
- ✓ Muscular sac that stores & concentrates bile.
- ✓ **Mucosa** – lined by simple columnar epithelium with microvilli.
- ✓ **Typical lamina propria** which secrete mucus.
- ✓ **NO goblet cells** seen.



---

## Gall Bladder

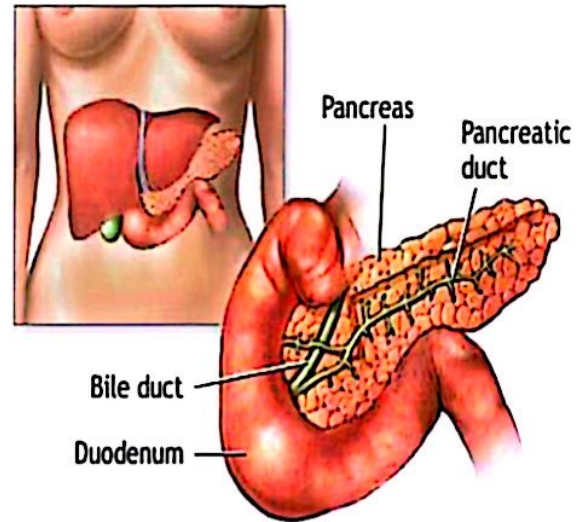
- ✓ **NO muscularis mucosa & submucosa.**
- ✓ Muscular layer has smooth muscle cells.
- ✓ Adventitia attaches it to the liver & serosa covers the free peritoneal surface.
- ✓ Cholecystokinin stimulate GB contraction.
- ✓ CCK secretion increased by fatty meals.





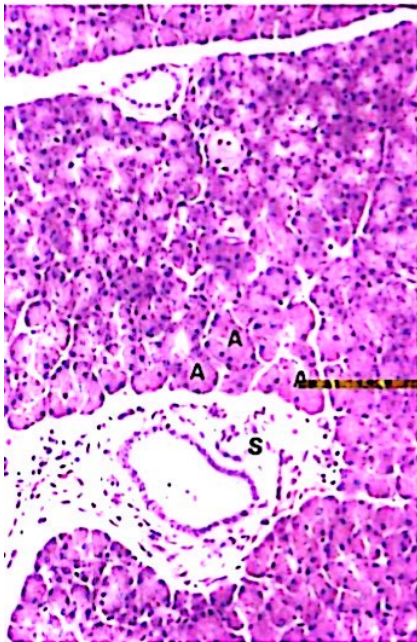
# Pancreas

- Fleshy retroperitoneal organ.
- **Exocrine part** – secretes digestive enzymes.
- **Endocrine part** secretes different hormones like glucagon & insulin.
- Gland has a thin **capsule** that sends septa penetrating the gland forming lobules.

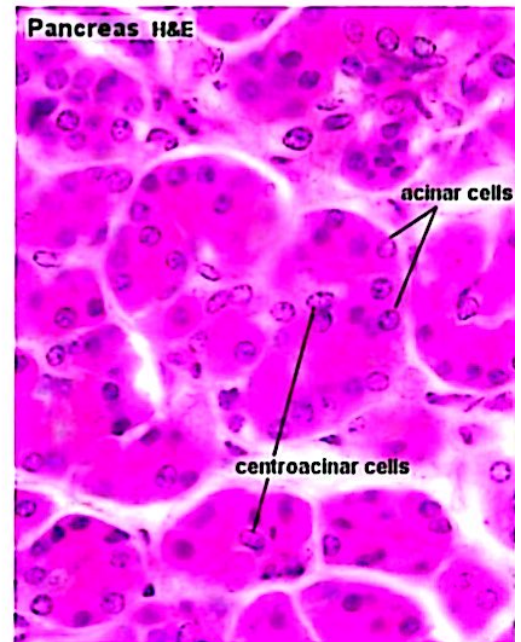


ADAM

# Pancreas



- ✓ Pancreatic juice is a clear alkaline fluid that contains precursors of digestive enzymes.
- ✓ These enzymes are activated in the small intestinal lumen such as : Proteases, trypsinogen, elastase, carboxypeptidase, Amylase (breaks down starch), Lipases (break down triglycerides), Ribonuclease & deoxyribonuclease.



Scanned with CamScanner

## **Nervous System**

The nervous system can be divided into the central and peripheral nervous system.

The nervous system is involved in most body functions, such as:

1- Sensory input

2- Integration

3- Motor output

### **Central Nervous System**

The central nervous system (CNS) consists of the brain and the spinal cord.

The brain is located within the skull. It is one of the largest organs in the body, that coordinates most body activities.

Cerebrum is the largest section of the brain, it is located in the upper portion of the brain and is the area that processes thoughts, judgment, memory, problem solving, and language. The outer layer of the cerebrum is the cerebral cortex, which is composed of folds of gray matter.

The cerebrum is subdivided into the left and right halves called cerebral hemispheres. Each hemisphere has 4 lobes.

#### **Frontal lobe, Parietal lobe, Occipital lobe, and Temporal lobe.**

Cerebellum is the second largest portion of the brain, located beneath the posterior part of the cerebrum. The cerebellum aids in coordinating voluntary body movements and maintaining balance and equilibrium.



## **Brain stem**

- Midbrain—acts as a pathway for impulses to be conducted between the brain and the spinal cord.
- Pons — means bridge—connects the cerebellum to the rest of the brain.
- Medulla oblongata—most inferior positioned portion of the brain; it connects the brain to the spinal cord.

**Spinal Cord:** The spinal cord is located within the vertebral canal, it connects to the brain at the level of foramen magnum and extend inferiorly in the vertebral canal to level L1-L2 of the vertebral column. It is considerably shorter than the vertebral column because it doesn't grow as rapidly as the vertebral column during development.

The spinal cord gives rise to 31 pairs of spinal nerves, which exit the vertebral column through intervertebral and sacral foramina.

The spinal cord is not uniform in diameter throughout its length. The cervical enlargement, in the inferior cervical region is where spinal nerves supplying the upper limbs arise. The lumbosacral enlargement in the inferior thoracic, lumbar, and superior sacral regions is the site where spinal nerves supplying the lower limbs arise.

Immediately inferior to the lumbar enlargement, the spinal cord tapers to form a conelike region called the **conus medullaris**. Its tip is the inferior end of the spinal cord and extends to the level of the second lumbar vertebra.

The conus medullaris and the numerous nerves extending inferiorly from it, within the vertebral canal, resemble a horse's tail and are therefore called the **cauda equina**.

## **Meninges of the spinal cord**

- Dura mater: outermost layer; continuous with epineurium of the spinal nerves
- Arachnoid mater: thin and wispy
- Pia mater: bound tightly to surface



## **Peripheral Nervous System**

The peripheral nervous system (PNS) is external to the CNS. It consists of sensory receptors and nerves.

Sensory receptors are the endings of nerve cells or specialized cells that detect temperature, pain, touch, pressure, light, sound, odors, and other stimuli.

Sensory receptors are located in the skin, muscles, joints, internal organs, and specialized sensory organs such as the eyes and ears.

The PNS is divided into two divisions:

**1- The sensory (afferent) division** transmits signals to the CNS from sensory receptors.

**2- The motor (efferent) division** transmits signals from the CNS to effector organs, such as muscles and glands.

## **Neurons**

Neurons are specific type of the cells of nervous system which receiving and transmit signals to other neurons or to effector organs.

Each neuron consists of a cell body, and two types of processes dendrites, and axons.

### **Types of neurons:**

Neurons are classified according to their function or structure. The structural classification is based on the number of processes that extend from the neuron cell body.

The three major categories of neurons are:

**1- Multipolar neurons:** have many dendrites and a single axon. Most of the neurons within CNS and motor neurons are multipolar.

**2- Bipolar neurons:** have two processes one dendrite and one axon. Bipolar neurons are located in some sensory organs such as in the retina of the eye and in the nasal cavity.

**3- Unipolar neurons:** have a single process extending from the cell body.

### **Nerves:**

A nerve is a bundle of axons and their sheathes. Twelve pairs of cranial nerves originate from the brain, and 31 pairs of spinal nerves originate from the spinal cord. Nerves transmit electrical signals

### **Cranial Nerves**

- **I Olfactory nerve** – sensory for smell
- **II Optic nerve** – sensory for vision
- **III Oculomotor nerve** – motor fibers to eye muscles
- **IV Trochlear** – motor fiber to eye muscles
- **V Trigeminal nerve** – sensory for the face; motor fibers to chewing muscles
- **VI Abducens nerve** – motor fibers to eye muscles
- **VII Facial nerve** – sensory for taste; motor fibers to the face
- **VIII Vestibulocochlear nerve** – sensory for balance and hearing
- **IX Glossopharyngeal nerve** – sensory for taste; motor fibers to the pharynx
- **X Vagus nerves** – sensory and motor fibers for pharynx, larynx, and viscera
- **XI Accessory nerve** – motor fibers to neck and upper back
- **XII Hypoglossal nerve** – motor fibers to tongue

### **Spinal Nerves**

**Cervical spinal nerves, Thoracic spinal nerves, Lumbar spinal nerves, Sacral spinal cords.**



# Central Nervous System (CNS)

- It is a soft organ and it consists of the brain and the spinal cord.
- In sectioning, shows region of gray (**gray matter**) and region of white (**white matter**).
- **Gray matter** contains **neuronal cell bodies, dendrites, and glial cells**. While **white matter** contains mainly **myelinated axons**.
- In cross section of the brain, **gray matter** forms the brain cortex and **White matter** forms the more central region.
- In cross section of spinal cord, **white matter** is peripheral and **gray matter** is central.

## Cross Section of the Brain

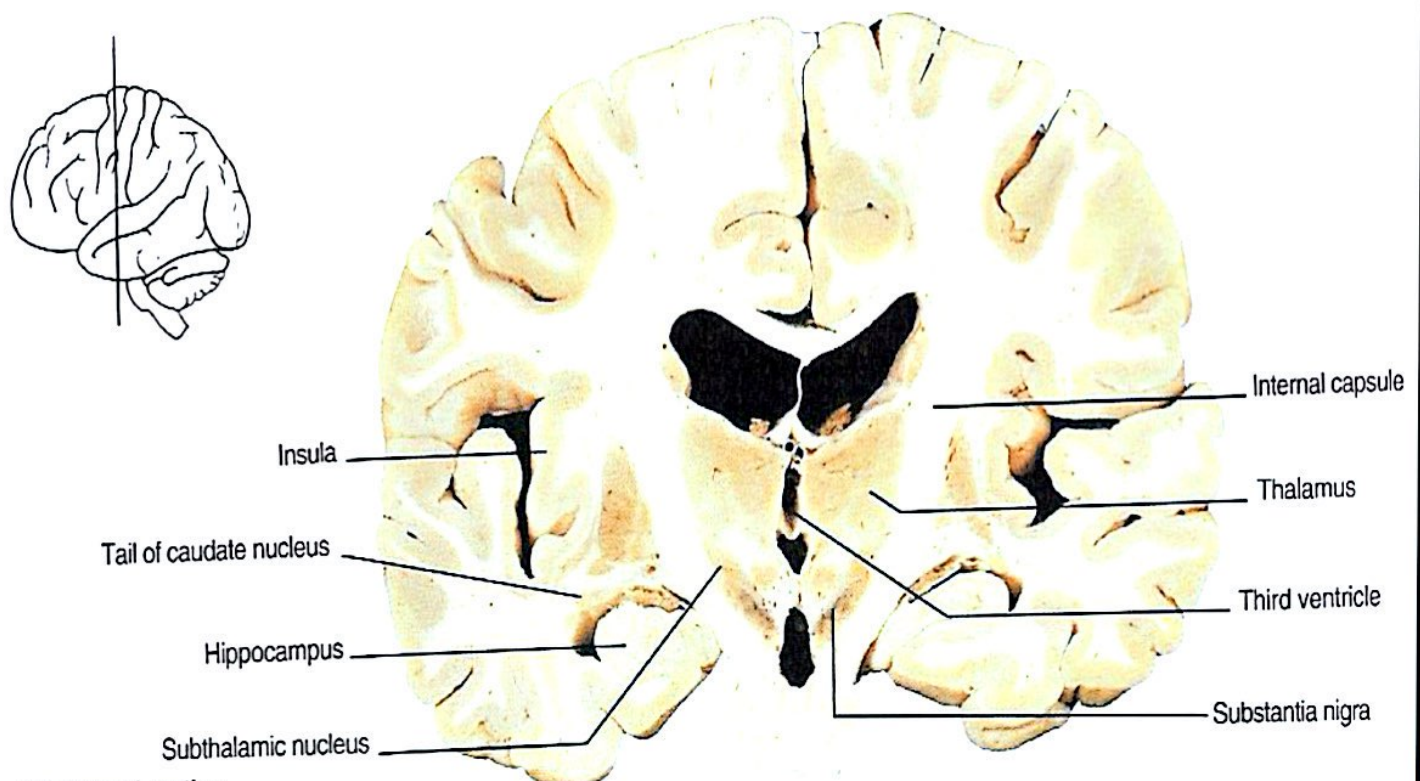
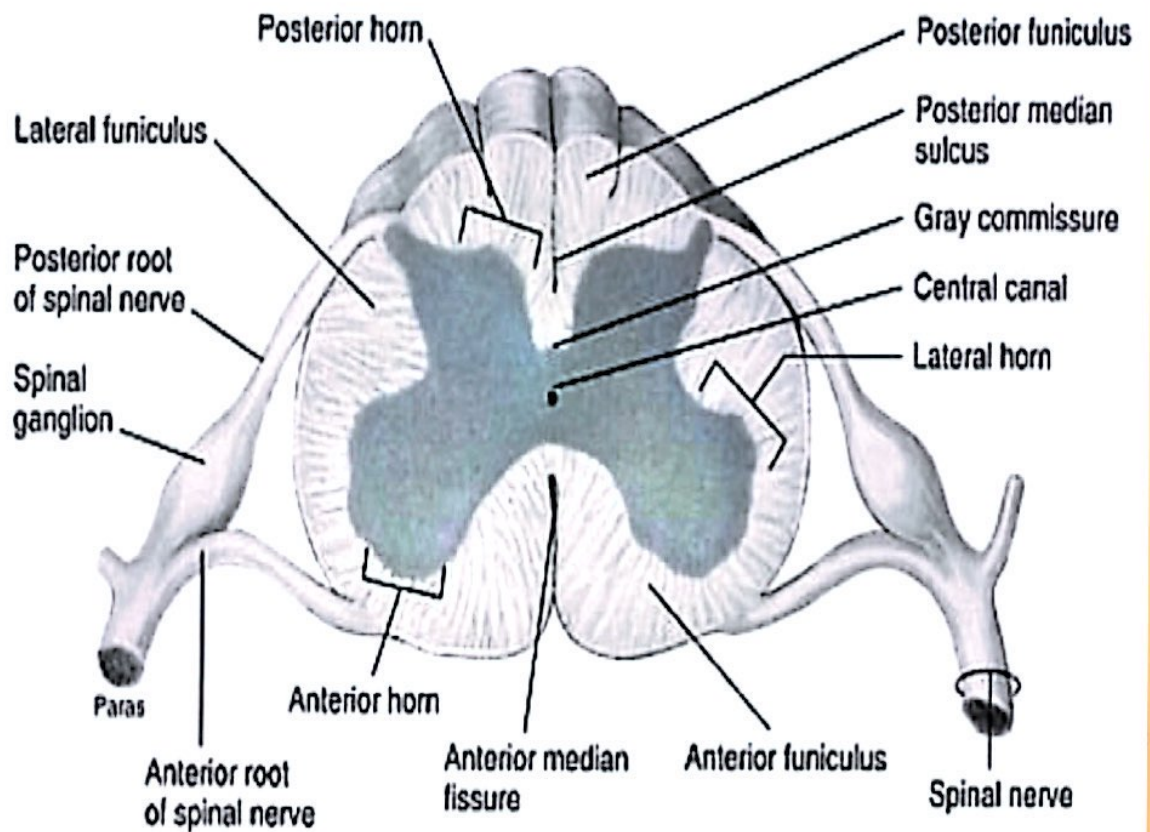


Fig. 10.9 Coronal section.



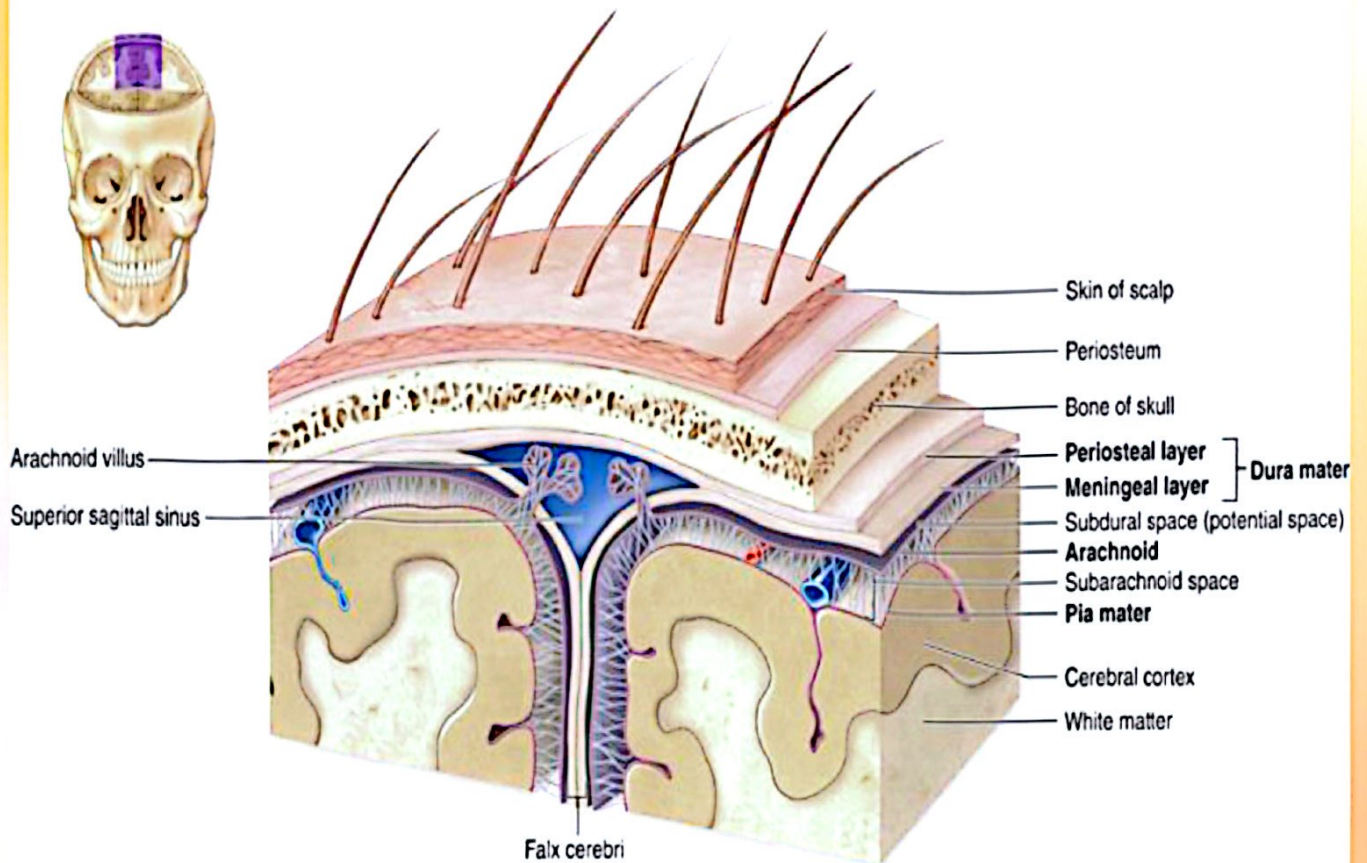
# Cross Section of the Spinal Cord

**White matter is peripheral and gray matter is central.**



- CNS is covered with membranes which is called **meninges** [three membranous layers these are (dura mater, arachnoid and pia mater)].
- Dura mater is the external layer, and the arachnoid is the middle while the pia mater is the inner layer which contains a large number of blood vessels.
- The **cerebral spinal fluid (CSF)** is founded in the space between arachnoid and pia mater.
- The CSF **protects the brain from injury**. And also helps to **carry nutrition and remove waste products**.





## Brain ventricales

- These are cavities within brain.
- The ventricles are continuous with one another as well as with the central canal of the spinal cord.
- There are 4 ventricles in the brain.

# Blood brain barrier

- The blood brain barrier is the functional barrier that prevents the passage of some substances, such as antibiotics and chemicals and bacterial toxic matter, from blood to nerve tissue.

## The Brain

- **Parts of the brain are:**

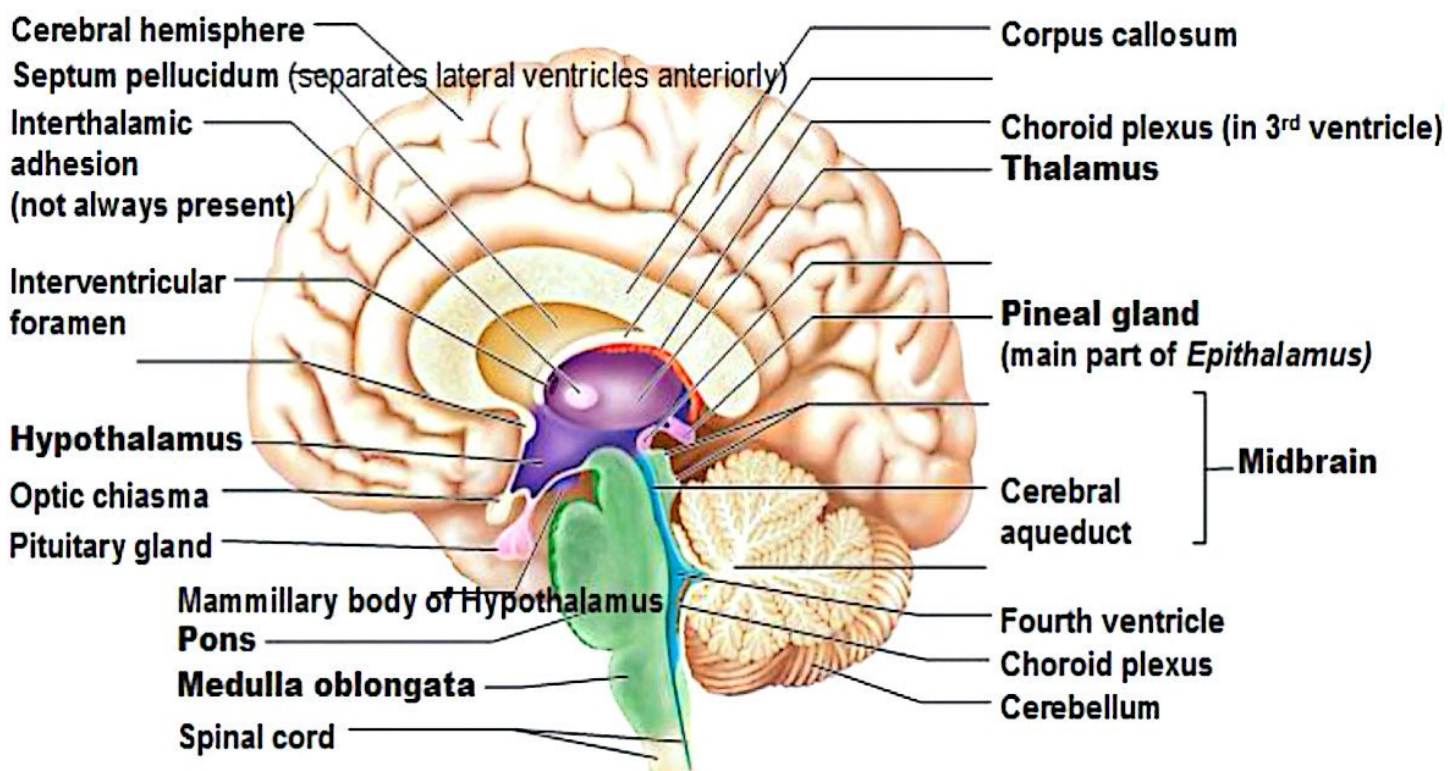
1. Cerebrum
2. Cerebellum
3. Brainstem



# Cerebrum

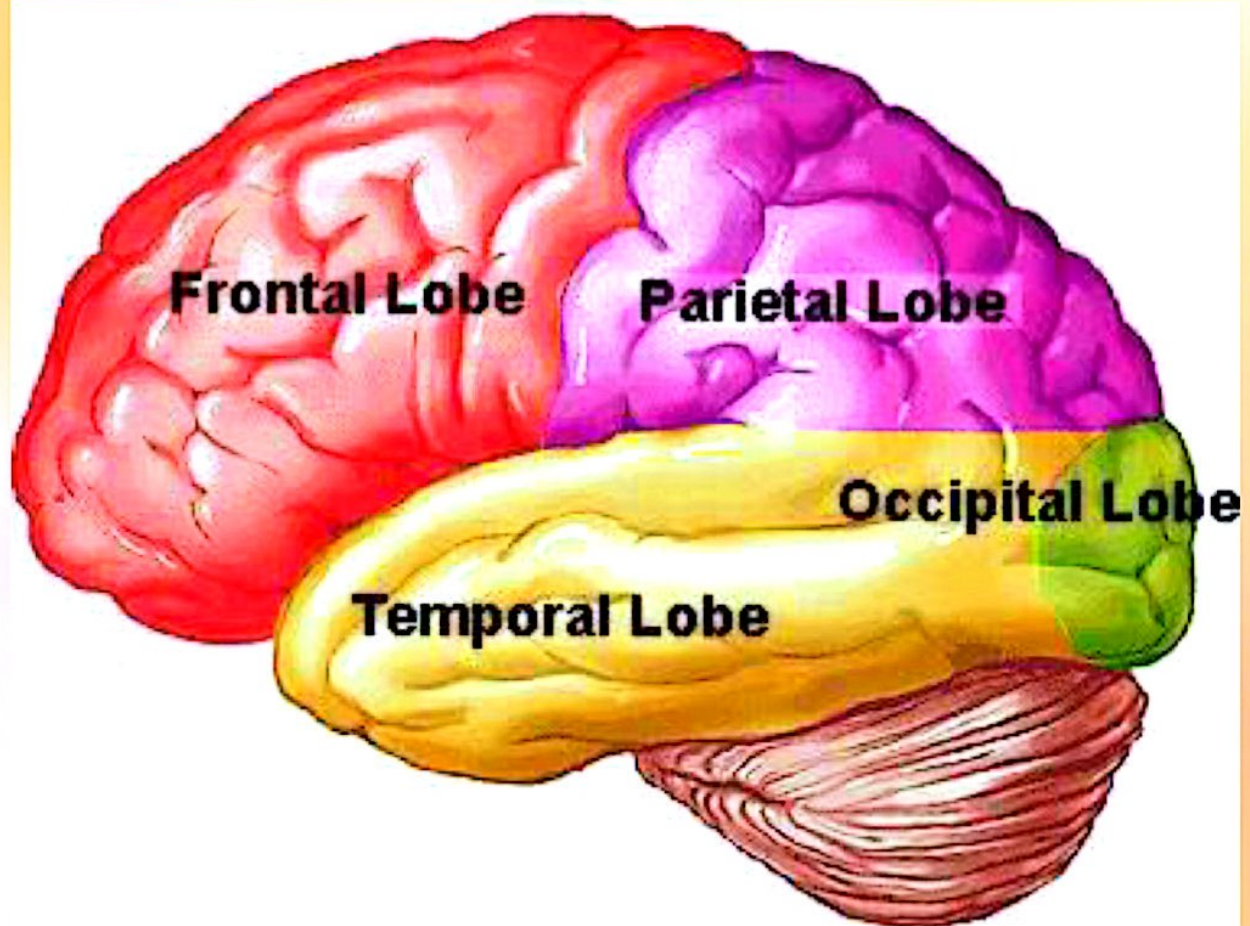
- The cerebrum is the largest and most developing portion of the brain.
- The cerebrum is divided into:
  - Telencephalon**
  - Diencephalon (consists thalamus, hypothalamus, and pineal body)**
- The **telencephalon** is divided into two hemisphere. The left hemisphere control the majority of functions on the right side of the body, while the right hemisphere controls most of functions on the left side of the body.
- The cerebrum contains grooves and folds.
- The grooves are called sulci while the folds are called gyri. The large grooves divide the cerebrum into lobes, so there are six lobes in the cerebrum.
- The lobes of cerebrum are: **frontal, parietal, temporal, occipital, insular, and limbic lobes.**

## The Diencephalon (and Brainstem)





# Lobes of cerebellum



- **The frontal** is involved in planning organizing, problem solving, and selective attention. The portion known as the pre frontal cortex control personality and various higher cognitive functions such as behavior and emotions. The back of the frontal lobe consists of the premotor and motor areas which produce and modify movements.
- **The Parietal lobe** process the sensory informations (touch, pressure) and integrate somato-sensory informations. Damage to the right parietal lobe can cause special visuo-special defect. Damage to the left parietal lobe may disrupt a patient ability to understand spoken and/or writing language.
- **The Temporal lobe:** are center of memory in learning, audition and required for recognize different things like faces, signs, environment).
- **The Occipital lobe:** is important for vision and visual processing.
- **The Insular lobe** is important for pain, bladder control and Gustation (taste).
- **limbic lobe** is important for emotion.



# The thalamus

- : refers to paired oval masses of gray matter that lie on the either side of the third ventricle.
- **Thalamus** consists of many **thalamic nuclei** (synapses among neurons inside the CNS). Thalamus is usually considered as a functional gateway of cerebral cortex.

# Hypothalamus

- **Functions of the hypothalamus:**
- master control of the autonomic nervous system
- regulation of body temperature
- control emotional behavior
- control food intake
- control water intake
- regulation of sleep-wake (circadian) rhythm



# Cerebellum

The cerebellum is also called little brain. And it lies behind the pons and the medulla.

## Functions of the cerebellum

It responsible for motion, balance, learning new things.

# Brainstem

- The brainstem consists of
  1. **Midbrain:** is continuous above with cerebral hemispheres.
  2. **Pons**
  3. **Medulla oblongata:** it is continuous below with the spinal cord.

## Functions of the brainstem

- Autonomic activities in the body, like breathing, digestion, heart beat,-----ect

## Spinal Cord

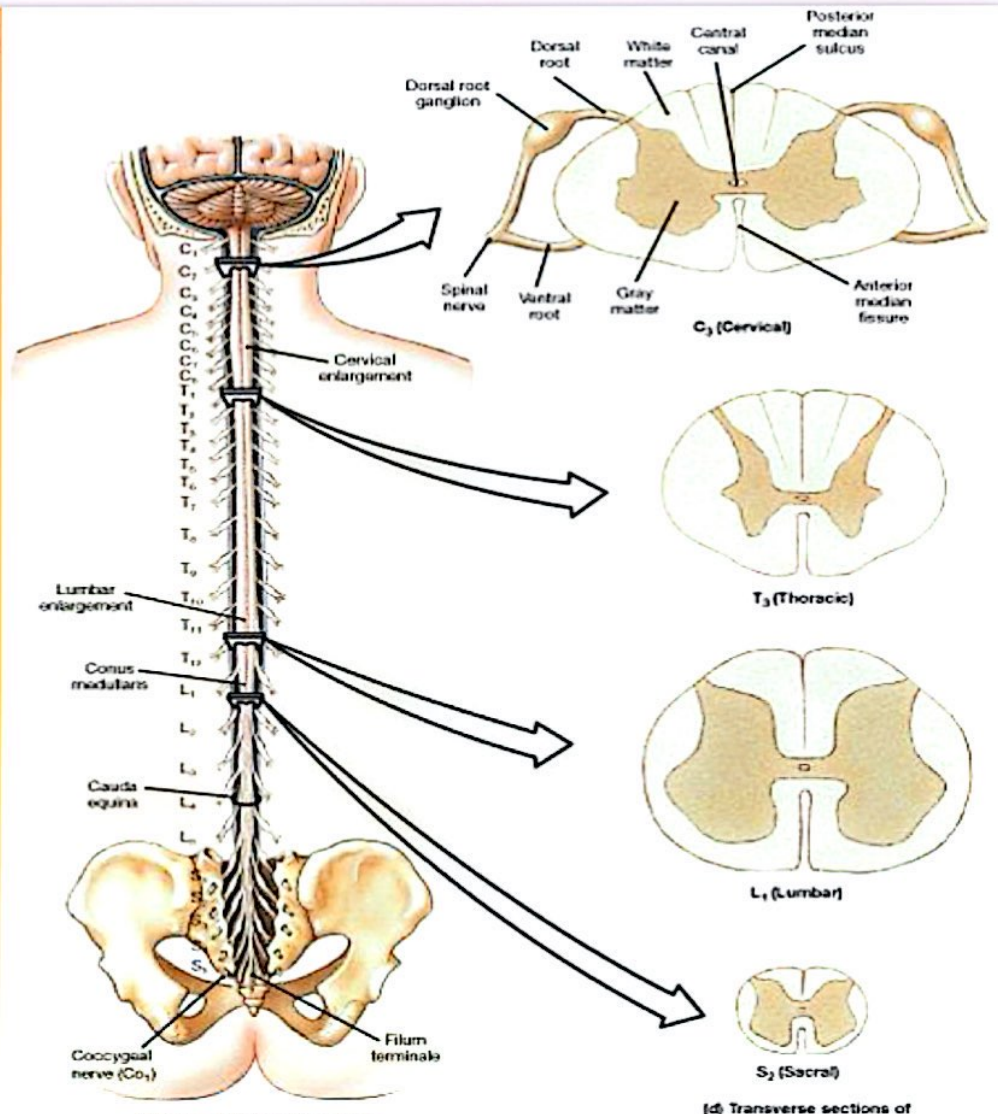
- The spinal cord is encased (located) in the bony vertebral column.
- It attached to the brainstem.
- It carry information from joint, muscle, skin, and other organs to the brain and vas versa.
- The nerve exit the spinal cord through the spinal notches between vertebrae.



# Spinal Cord Segments

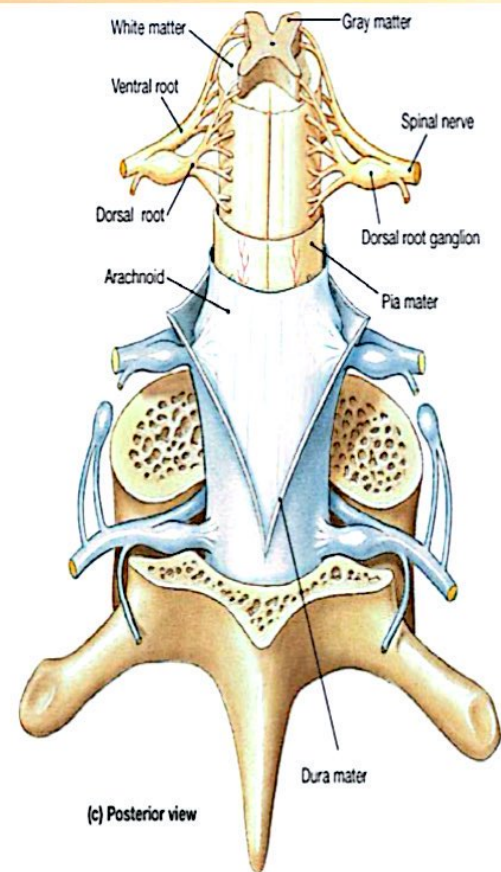
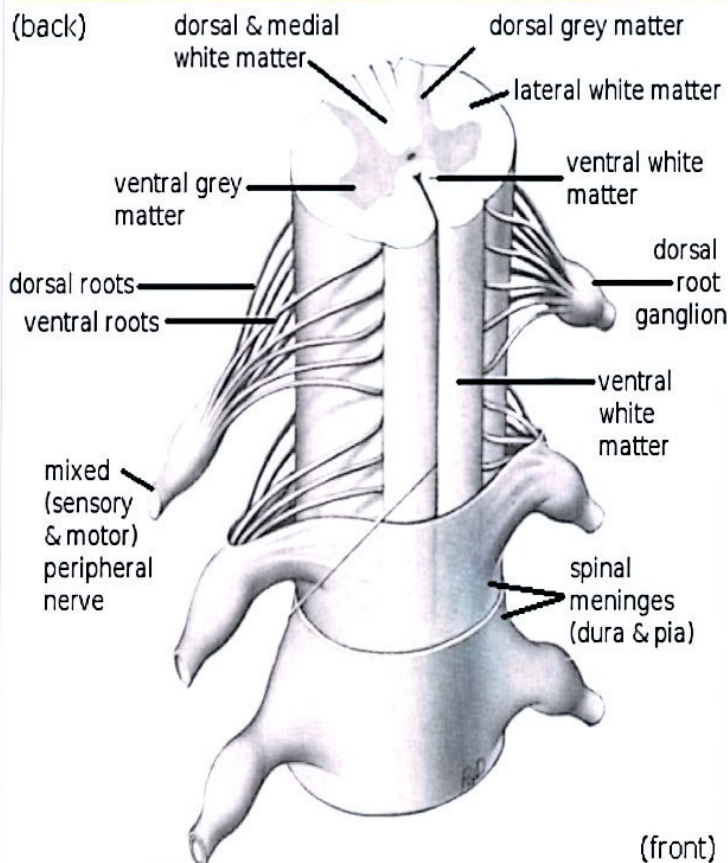
- The spinal cord is a long, thin collection of nerves from the brain that extends to approximately the 2<sup>nd</sup> lumbar vertebra.
- It is divided into 4 main regions:
  1. Cervical spinal cord
  2. Thoracic spinal cord
  3. Lumbar spinal cord
  4. Sacral spinal cord
- There are 30 segments in the spinal cord. Each segment has one pair of nerve on each side.

## Spinal cord segments





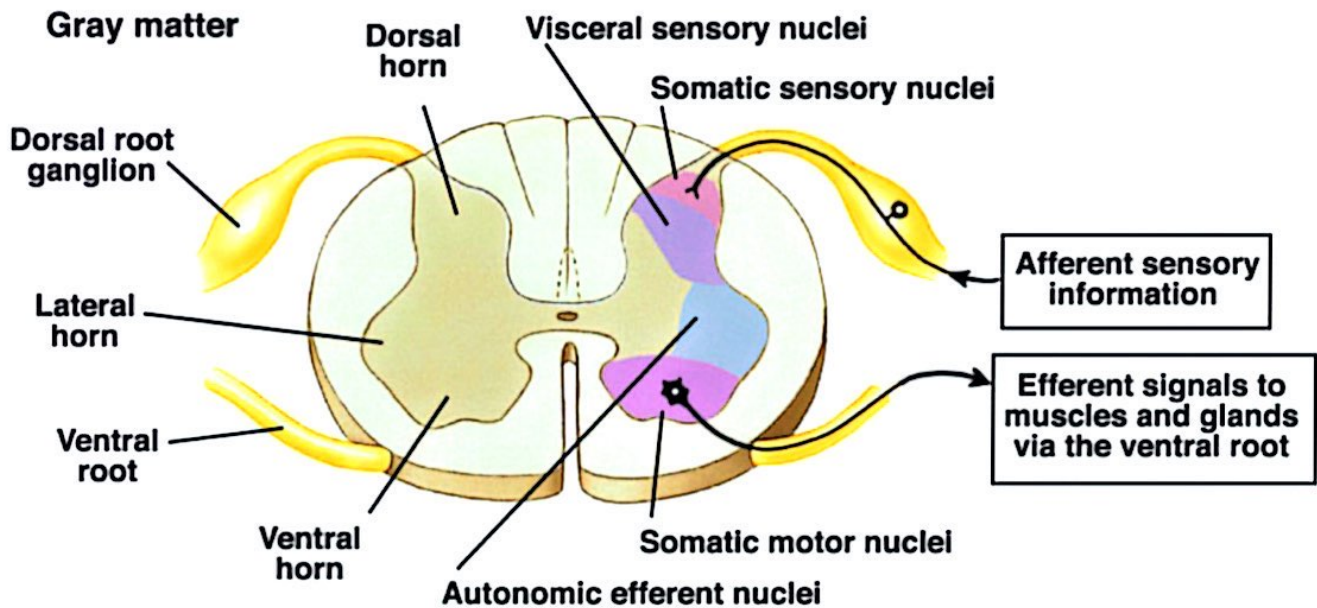
# The spinal cord communicates via the spinal nerves



## Cross Section of the Spinal Cord

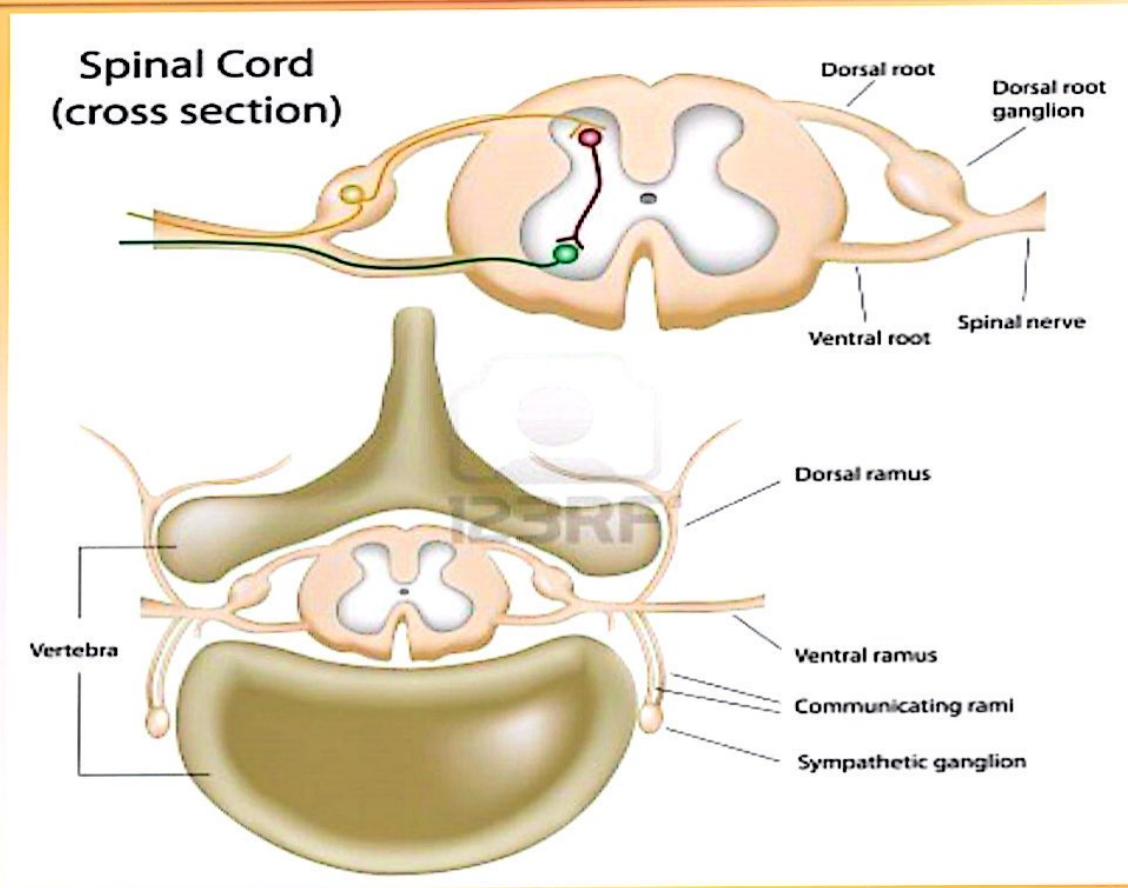
- The gray matter of the spinal cord forms an **H-shaped mass**.
- **Central canal** is an opening located in the horizontal bar of the this H and the central canal contains CSF.
- the gray matter of the legs of the H forms the **anterior horns**.
- the gray matter of the arms of the H forms the **posterior horns**.
- The **anterior horns** contain **motor neurons** whose axons make up the **ventral roots** of the spinal nerves.
- The **posterior horns** receive sensory fibers from neurons in the **dorsal roots**



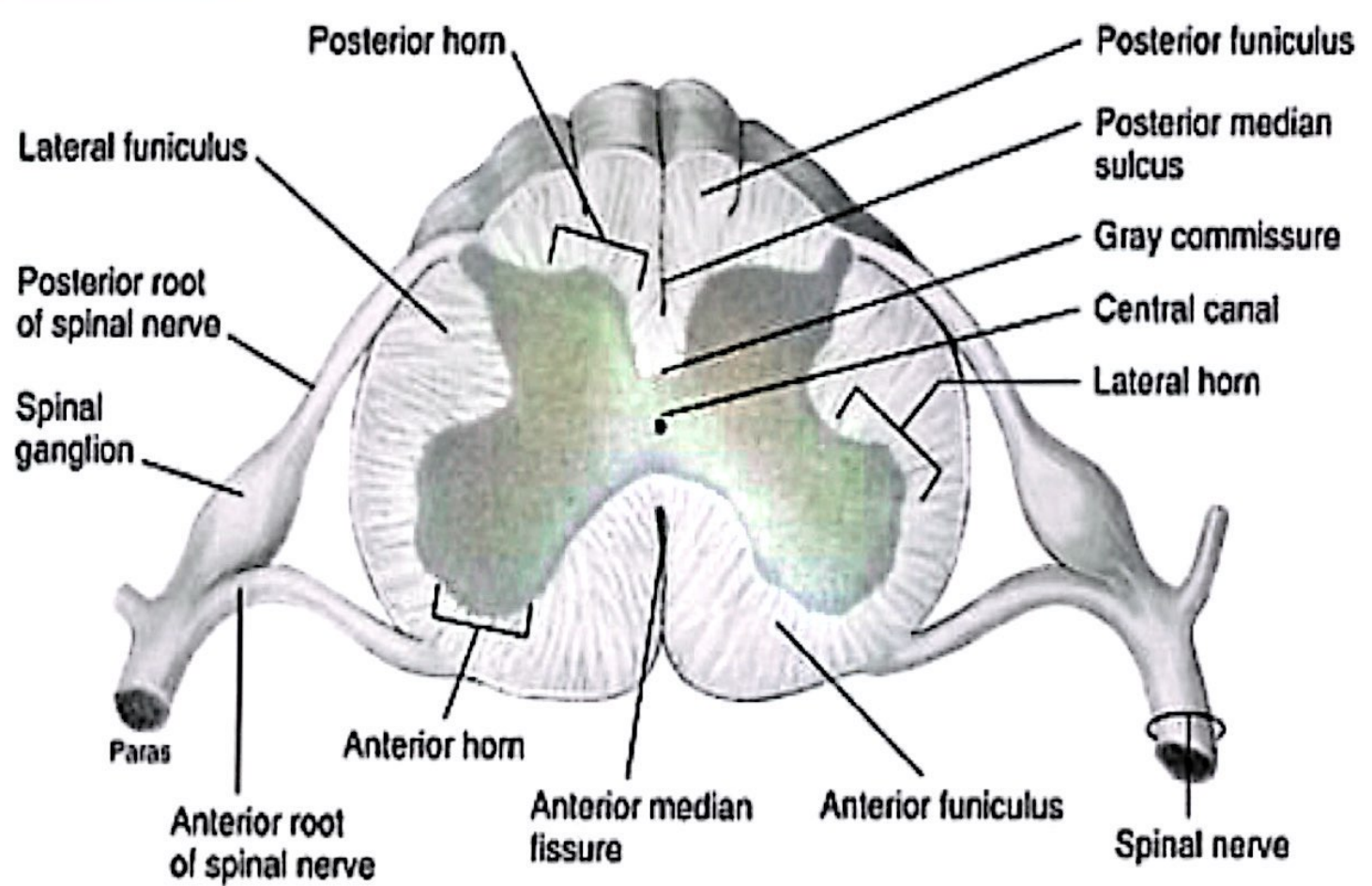


- **Dorsal root ganglia** are present at each spinal segment.
- Each pair of **dorsal root ganglia** contains sensory neuron cell bodies.
- Adjacent to the dorsal root there is a ventral root.
- **Ventral root** contains the axons of motor neurons, also exit the spinal cord.
- **Together the dorsal root and the ventral root form the spinal nerve.**
- So the spinal nerve are the mixed nerve because they contain both sensory and motor nerve fibers.

# Cross Section of the Spinal Cord



## Cross Section of the Spinal Cord





# ***LYMPHATIC SYSTEM***

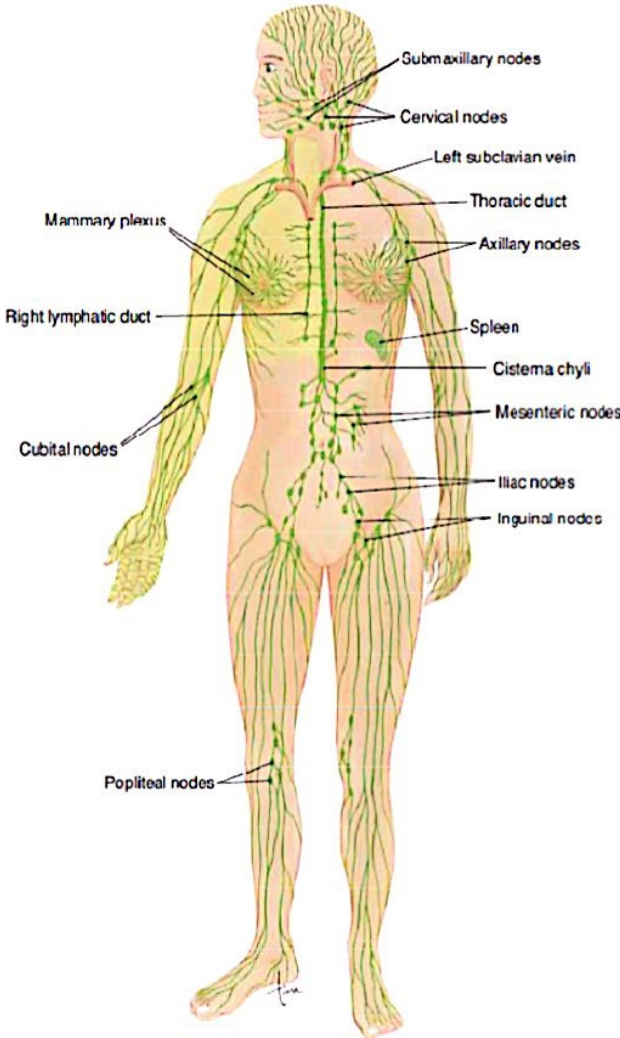
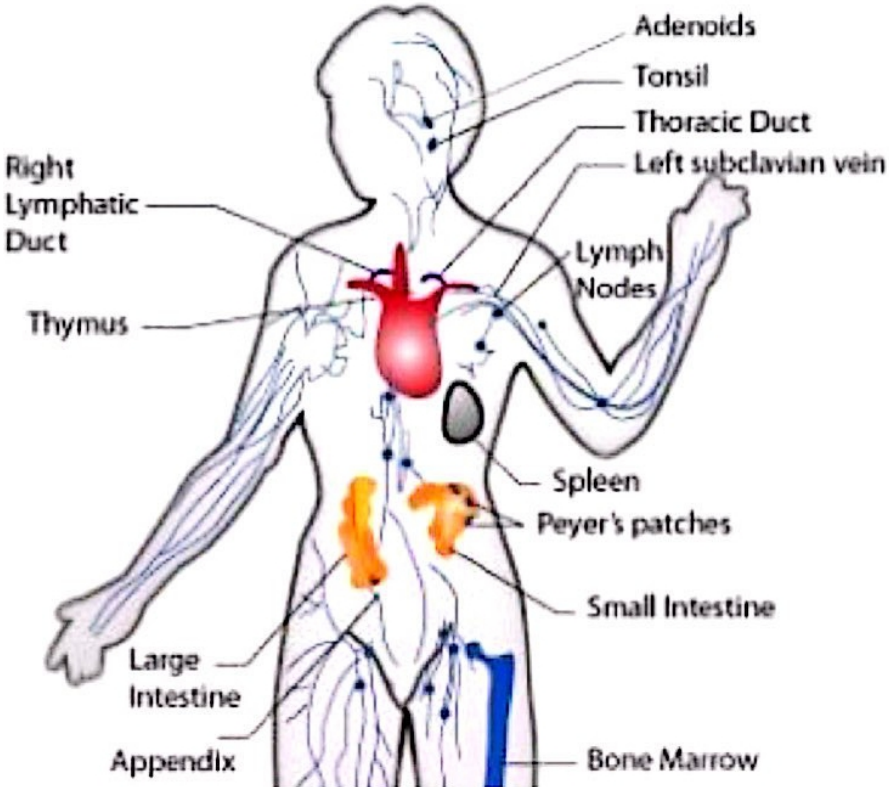
---

## ***LYMPHATIC SYSTEM***

### ***Contents:***

- 1. Anatomy of Lymphatic System**
- 2. Physiology of Lymphatic System**

# Lymphatic System (Immune System)

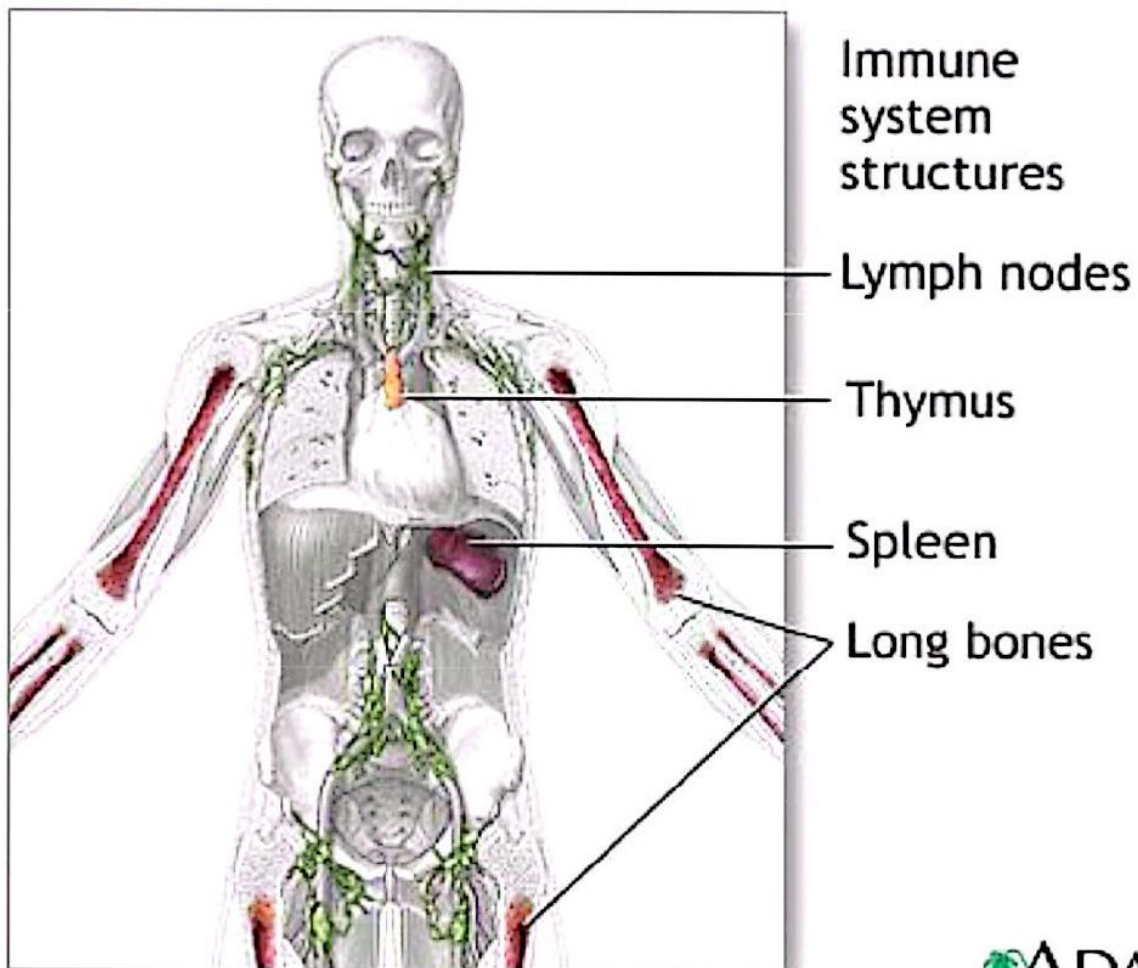




## **7th LECTURE**

### **Anatomy of Lymphatic System**

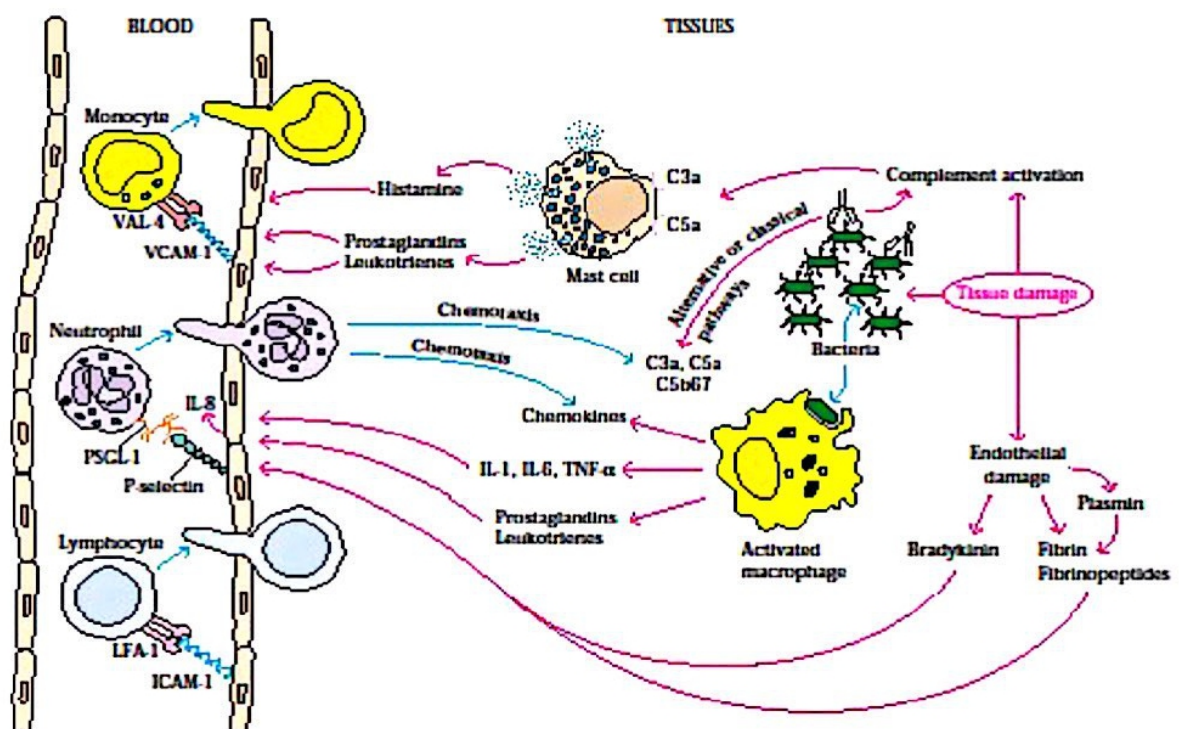
- I- Lymph
- II- Lymphatic vessels
- III- Lymphocytes
- IV- Lymphoid Organs
- V- Lymphoid tissues



contents:

# I- LYMPH

## Overview of the cells and mediators involved in a local acute inflammatory response



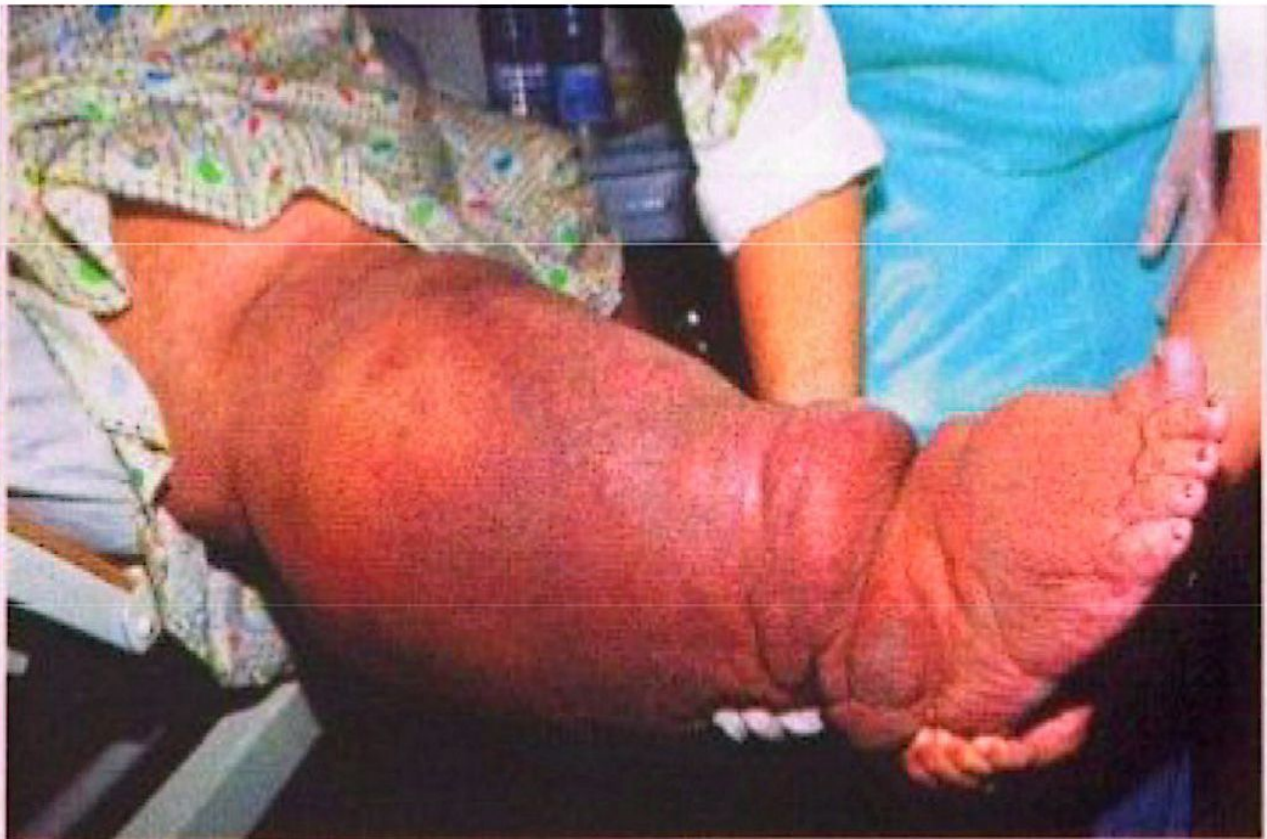

# LYMPH

It is the (ECF) that enters lymphatic capillaries from tissues in all parts of the body and returned to the blood by lymphatic system.

## Composition of Lymph:

- 1- Water 95%.
- 2- Plasma proteins and other chemicals contained in blood plasma, but in less percentage, except WBCs are in more percentage than blood.
- 3- Lymphocytes: the **chief** cellular component of lymph.
- 4- The amount of liquid that leaves the blood and passes through the system daily, moves through the tissues and returning to the bloodstream is about 6 gallons (24 liters).



---

Continue: **LYMPH**

**LYMPH must be returned to the blood :**

**A- to maintain blood volume**

**B- blood pressure**

**C- to avoid edema.**

---

**contents:**

**II- LYMPHATIC**

**VESSELS**



# **LYMPH (LYMPHATIC)VESSELS**

## **TYPES OF LYMPHATIC VESSELS 572**

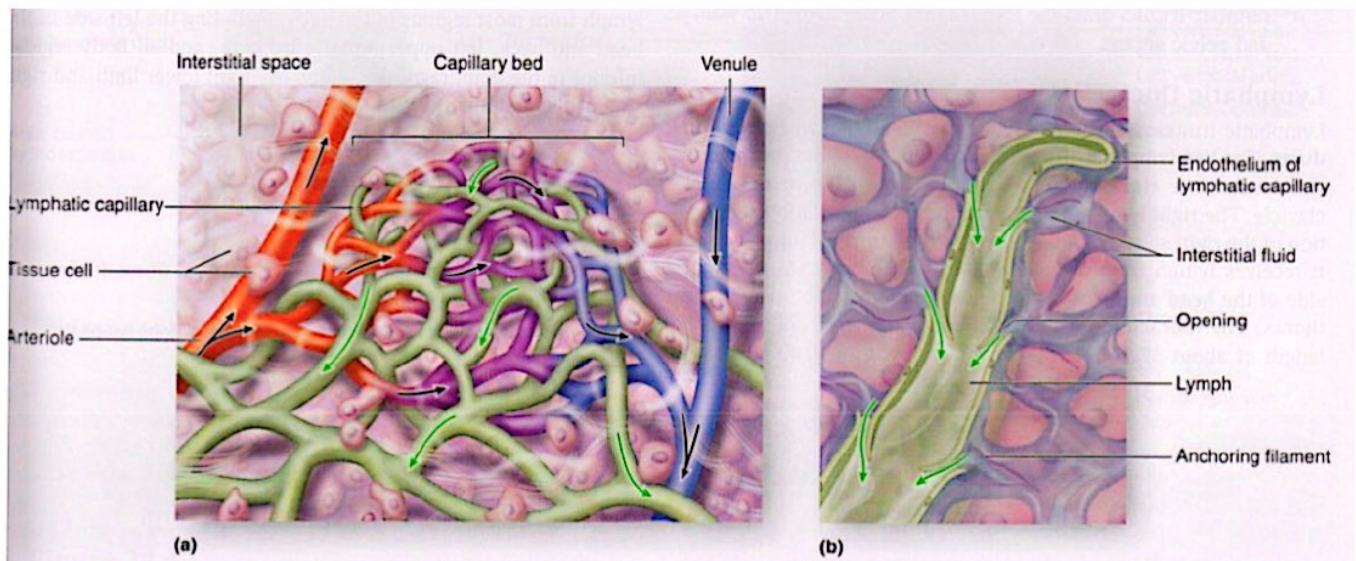
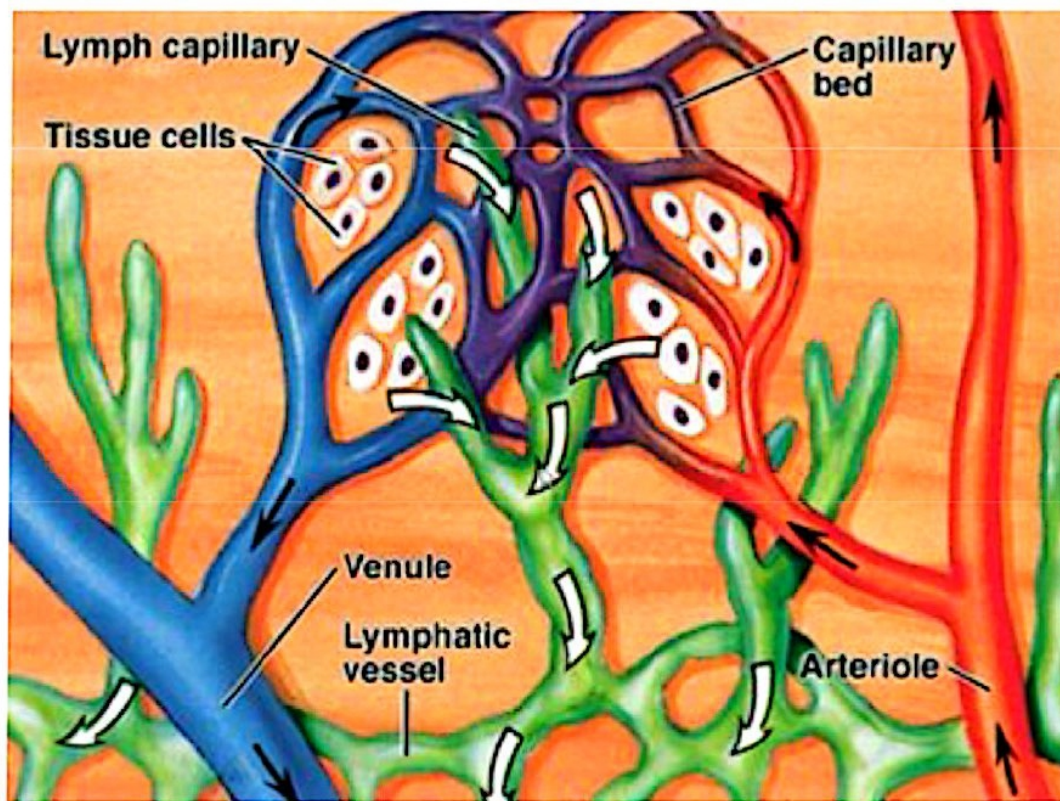
- 1- Lymphatic capillaries or terminal lymphatic
- 2- Small lymphatic vessels
- 3- Major lymphatic – Collecting vessels
- 4- Thoracic duct and cisterna chyli
- 5- Right lymphatic duct

---

### **Lymphatic capillaries or terminal lymphatic**

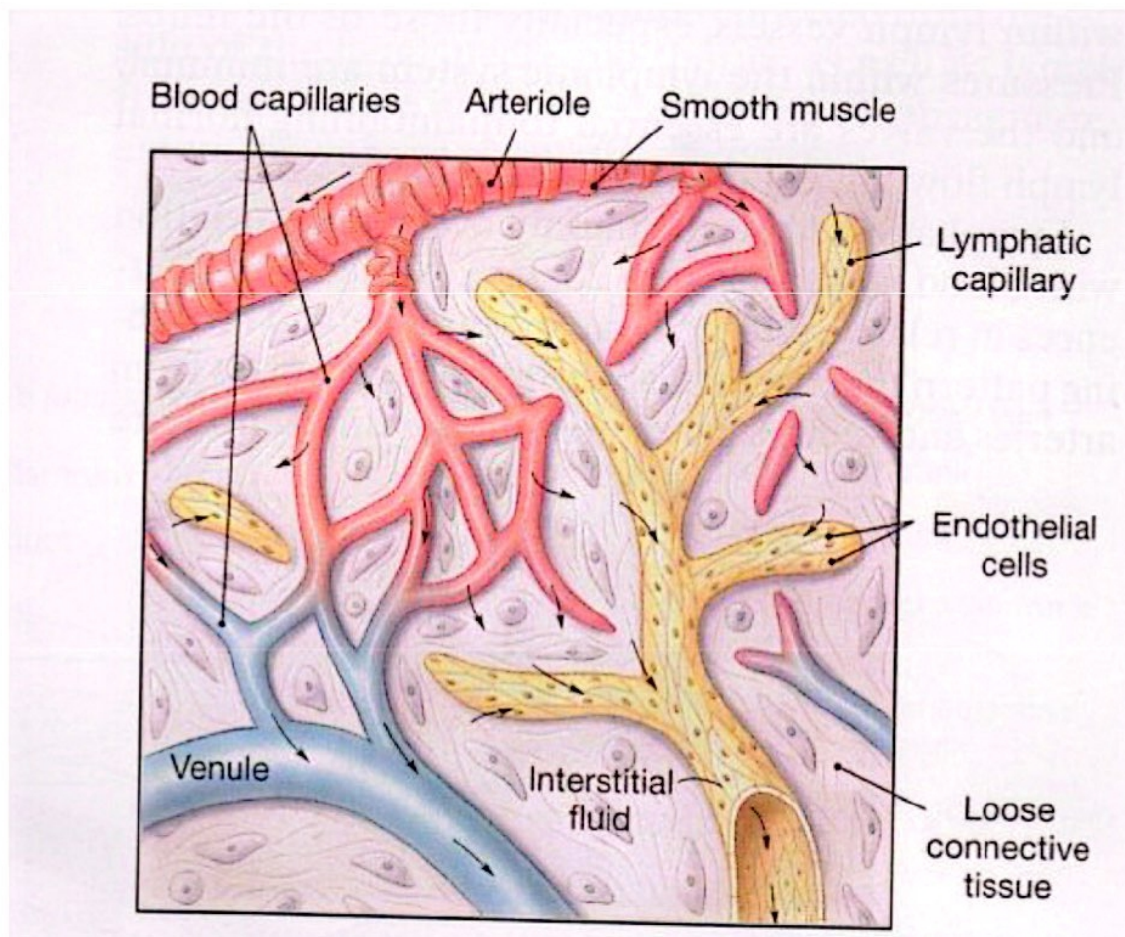
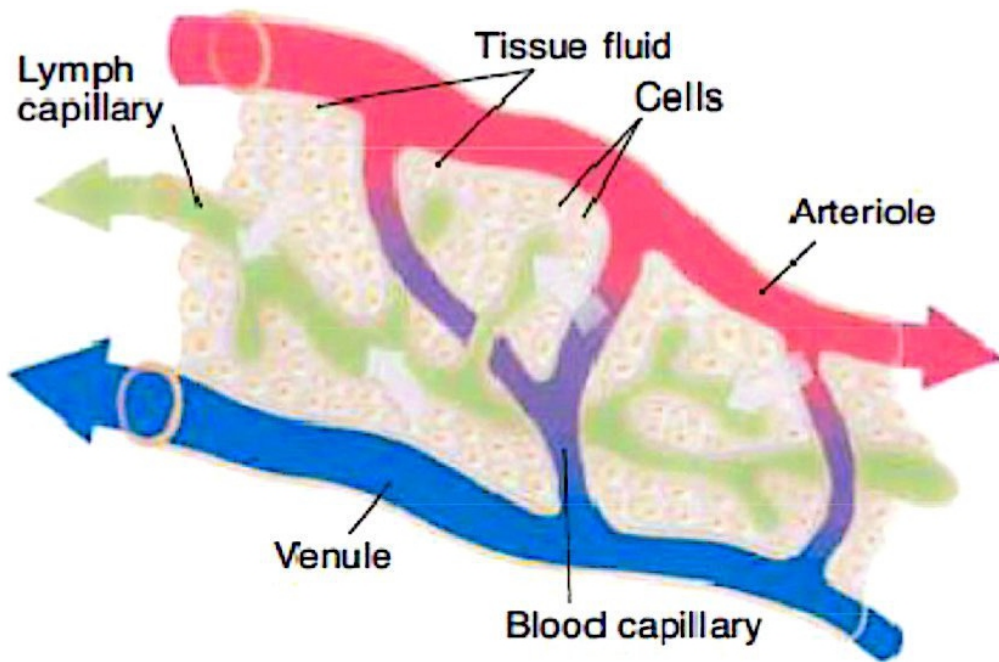
Dead-end lymph capillaries are found in most tissue spaces; collect tissue fluid and proteins, especially from subcutaneous and mucous membrane of respiratory, urinary, reproductive system. Also, from serous membrane of pleural and peritoneal cavity.

# Lymphatic Capillaries

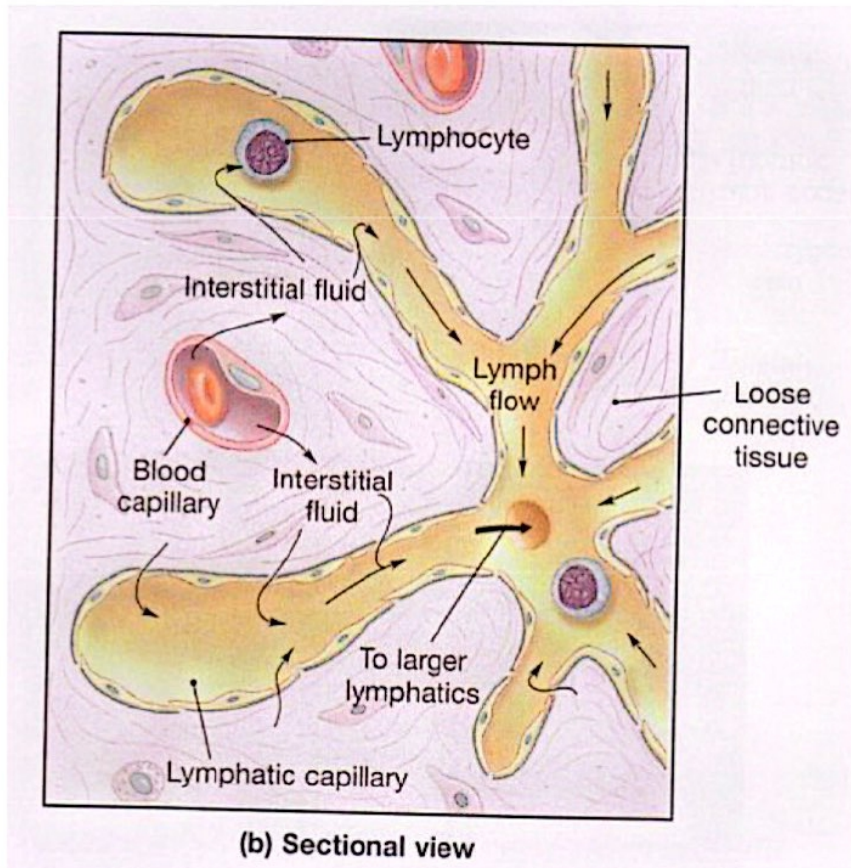




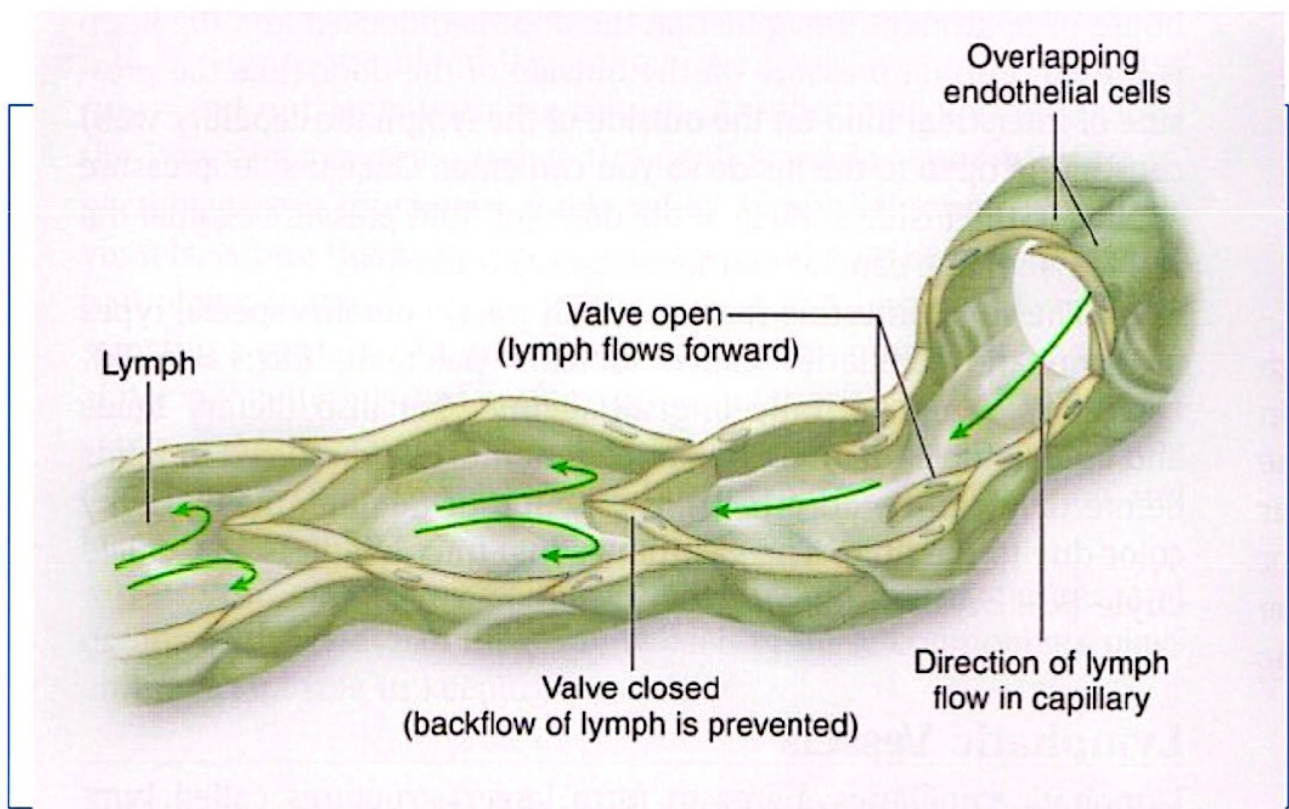
**Dead-end lymph capillaries found in tissue spaces.**



# Lymphatic capillaries or terminal lymphatic 753

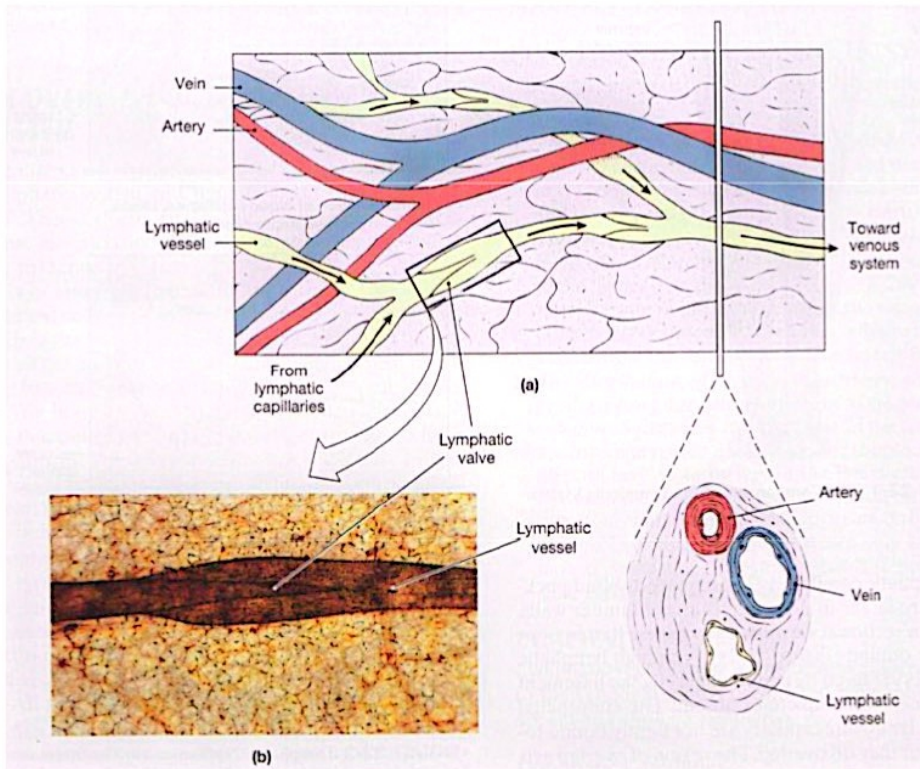


# Lymphatic capillaries or terminal lymphatic

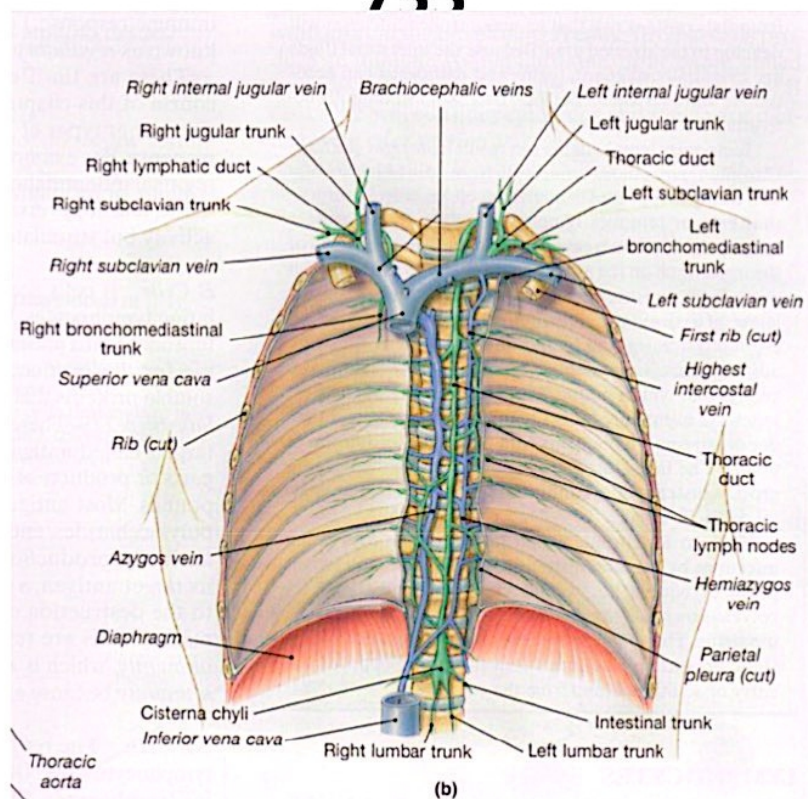




# Small lymphatic vessels 754



# Major lymphatic – Collecting vessels 755



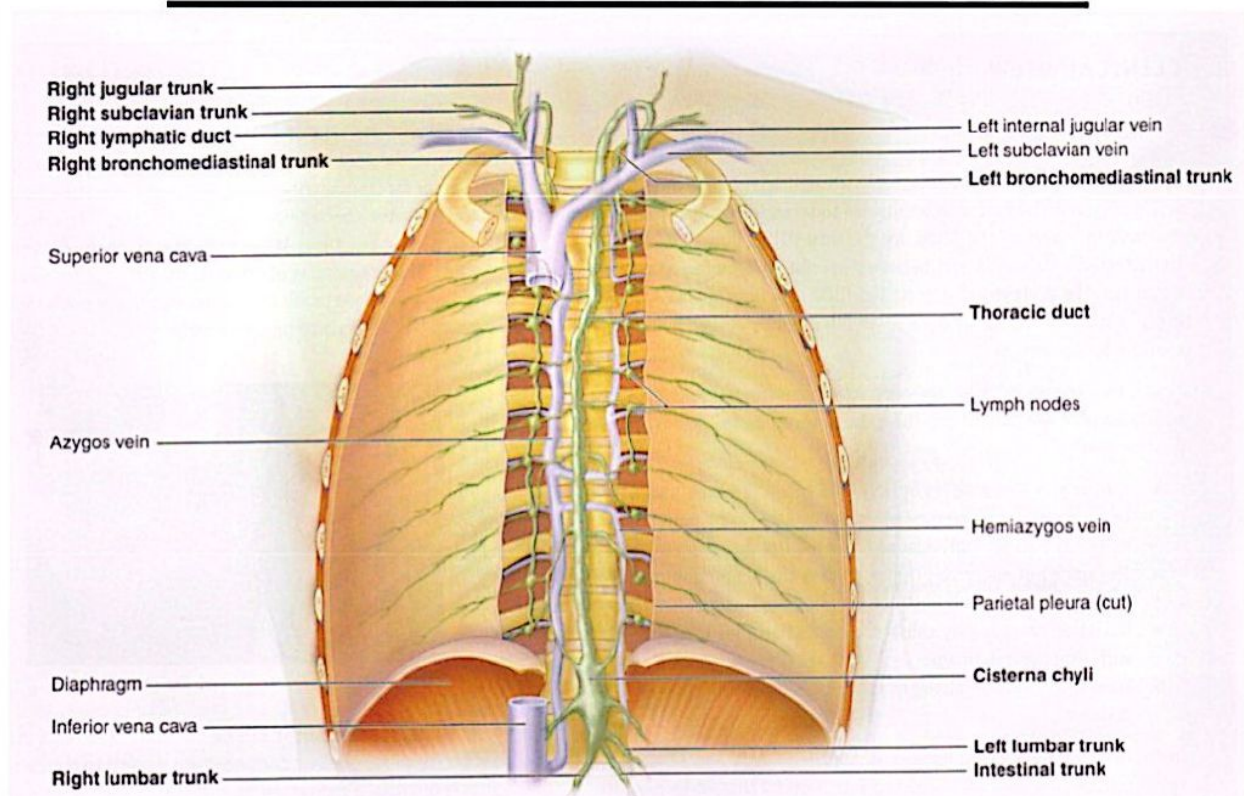
# Thoracic duct and cisterna chyli 755

## Thoracic duct (left lymphatic duct):

collect lymph from the body inferior to diaphragm, and from the left side of the body superior to diaphragm.

Thoracic duct empties (return) lymph into left subclavian vein.

## THORACIC TRUNKS AND DUCTS





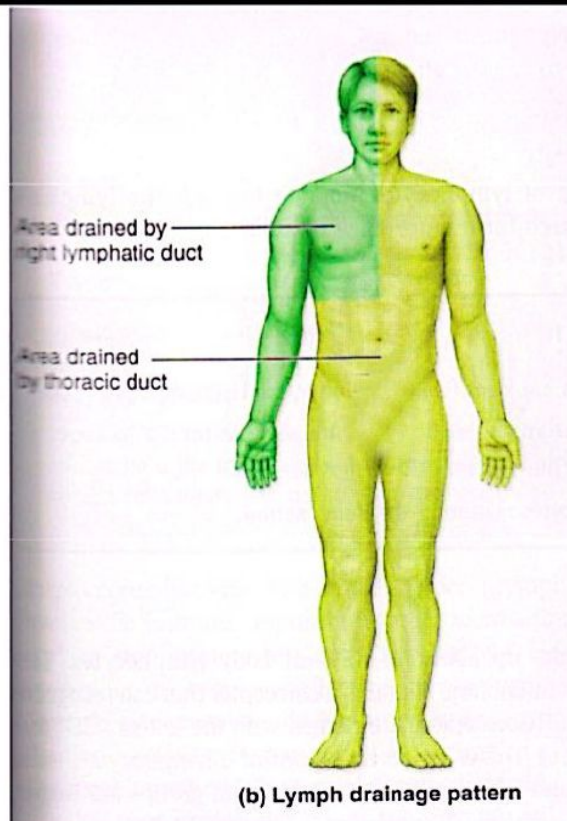
# Right lymphatic duct 756

Formed by merging of right jugular, right subclavian, and right bronchomediastinal trunks in the area near the right clavicle.

*This duct empties into the right subclavian vein ( delivering lymph from the right side of the body superior to the diaphragm)*

---

## THORACIC TRUNKS AND DUCTS



# **FUNCTIONS OF LYMPHATIC VESSELS**

- 1- Dead-end lymph capillaries are found in most tissue spaces; collect tissue fluid and proteins, especially from subcutaneous and mucous membrane of respiratory, urinary, reproductive system. Also, from serous membrane of pleural and Peritoneal cavity.
- 2- Thoracic duct (left lymphatic duct): collect lymph from the body inferior to diaphragm, and from the left side of the body superior to diaphragm. Thoracic duct empties (return) lymph into left subclavian vein.

---

## **Continue: FUNCTIONS OF LYMPHATIC VESSELS**

- 3- Right lymphatic duct : collect lymph from the right side of the body superior to the diaphragm, right thoracic duct drain (return) lymph into right subclavian vein
- 4- Cisterna chyli: the base of thoracic duct receive lymph from the inferior part of the abdomen.
- 5- The structure of larger lymph vessels is like that of veins; contain valves to prevent the backflow of lymph.
- 6- Lymph is kept moving in lymph vessels by:
  - a- constriction of the lymph vessels
  - b- the skeletal muscle pump
  - c- the respiratory pump



contents:

## III- LYMPHOCYTES

---

### LYMPHOCYTE

#### General Functions of Lymphocyte

Lymphocytes circulate continually in the blood and

lymph and, in common with their types of leukocytes,

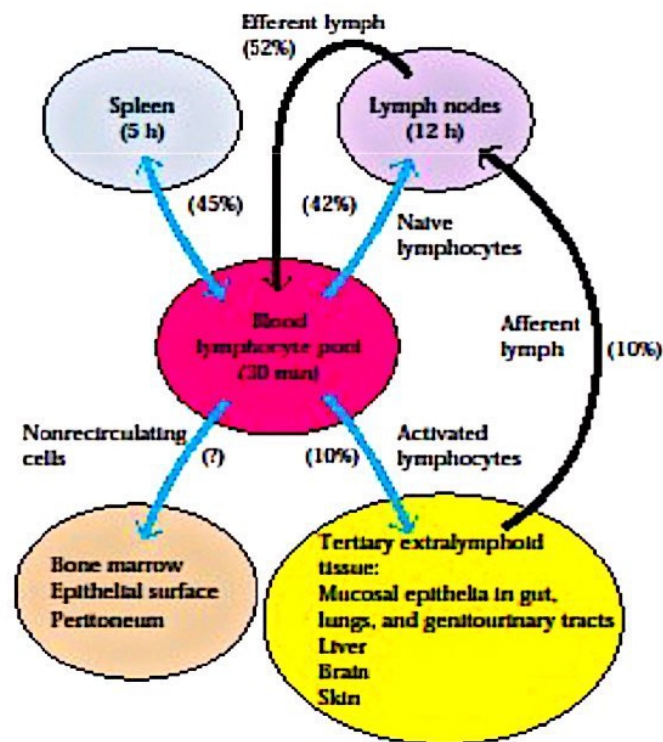
migrate into the tissues at sites of infection or tissue

Injury to:

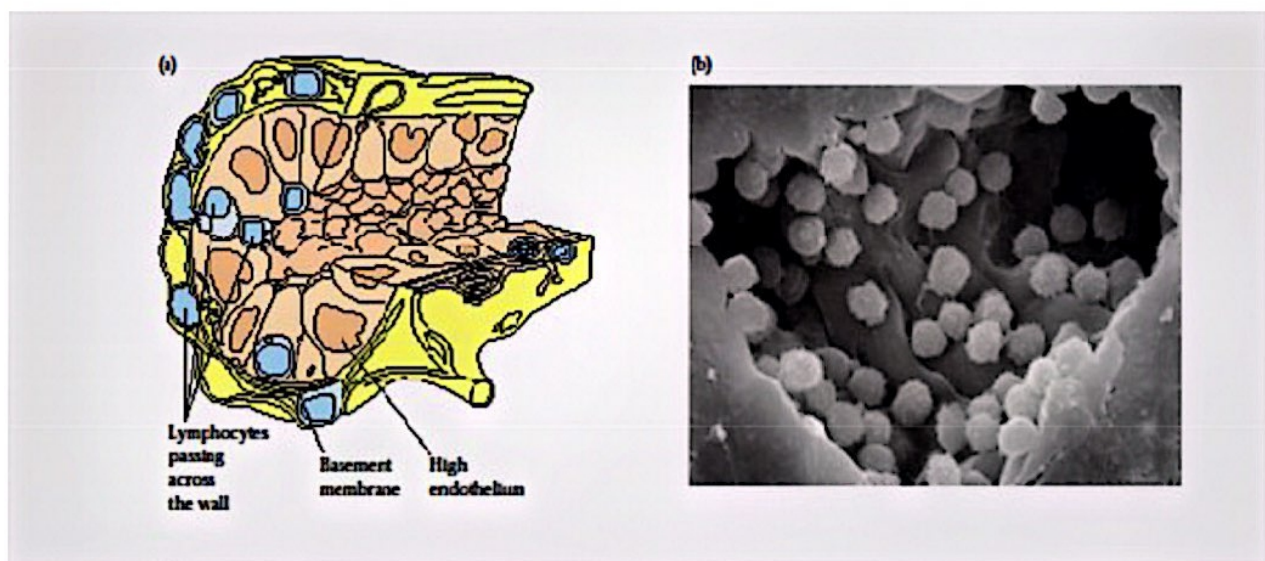
1- to attack antigen

2- involve in immune response

# Lymphocyte recirculation routes



## Lymphocytes Attached to the Surface of a High-Endothelial Venule





## TYPES OF CIRCULATING LYMPHOCYTES 756

<u>Types</u>	<u>Function</u>
1- B- Lymphocytes ( B-Cell )	Differentiate into plasma cells, And secrete <u>Antibody</u> called Humoral antibody.
2- T- Lymphocytes ( T- Cell) a- Helper T- cells b- Cytotoxic T- cells c- Suppressor T- cells d- Memory T- cells	Cellular immunity.
3- Natural killer (NK)	Destroys foreign cells; like Virus invade cells or cancer Cells.

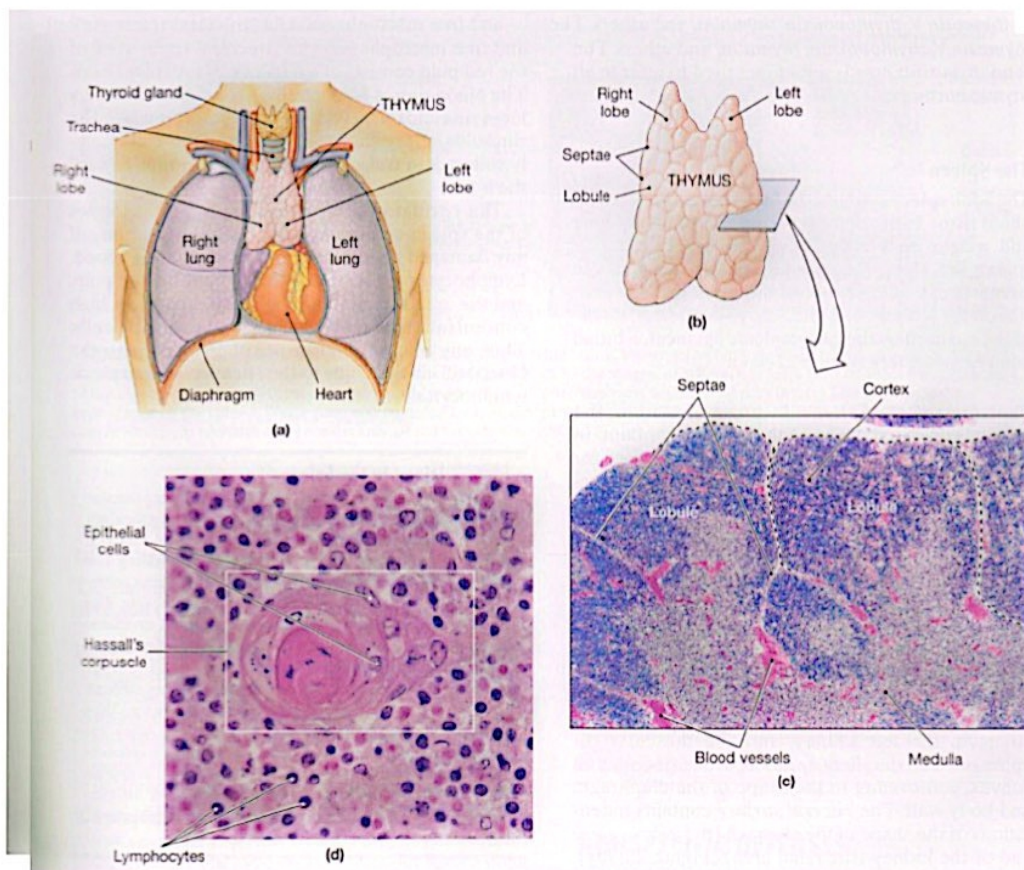
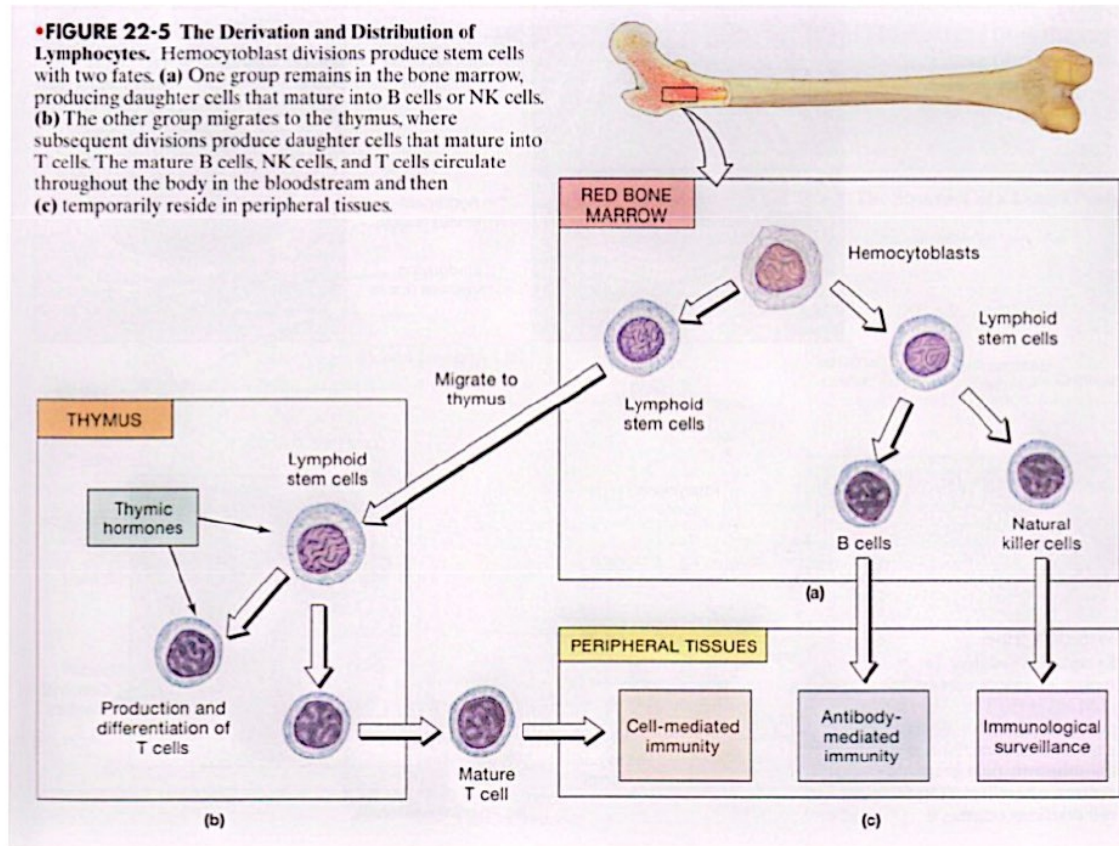
---

### LYMPHOPOIESIS (Lymphocyte Production)

- 1- Hemocytoblast divided in bone marrow to produce .... 2 groups lymphoid stem cells
- 2- One group of lymphoid stem cells remain in bone marrow to produce  
B-cells and NK cells
- 3- Second group of lymphoid stem cells migrates to the thymus to produce various  
types of T cells ( three types)
- 4- T cells and B cells migrate from the site of production to the different tissues ,  
and have the ability to divide.

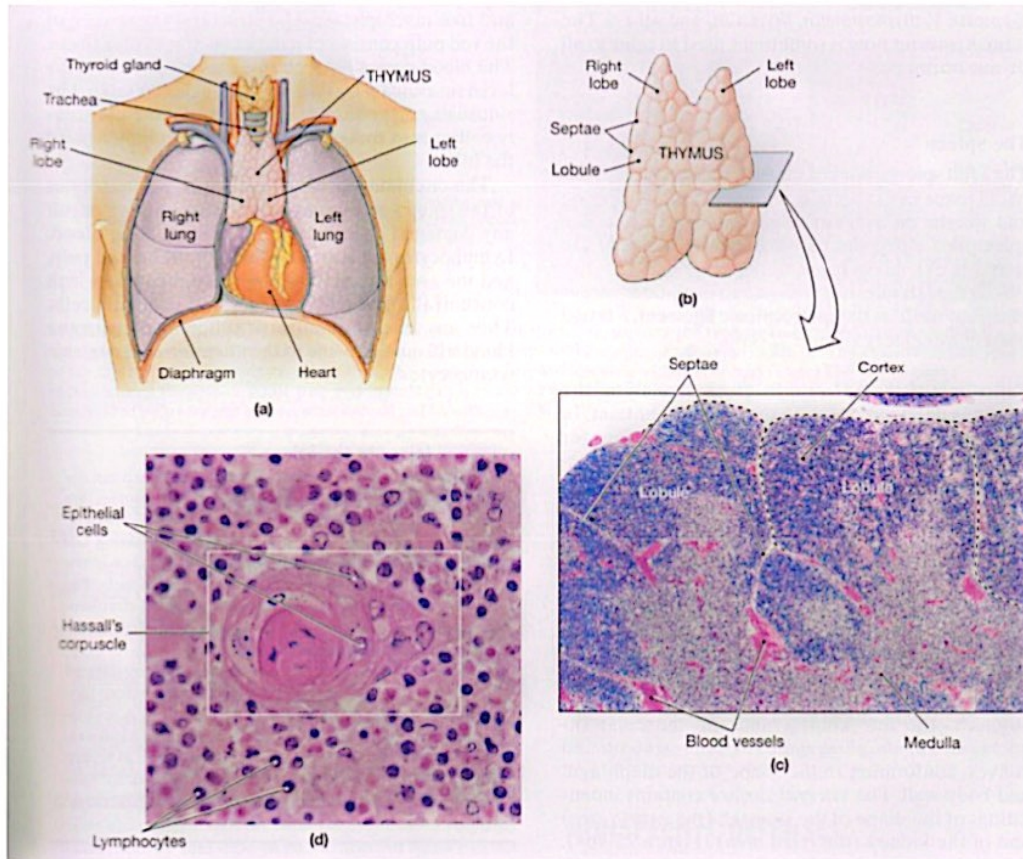
# LYMPHOPOIESIS (Lymphocyte Production)

• **FIGURE 22-5 The Derivation and Distribution of Lymphocytes.** Hemocytoblast divisions produce stem cells with two fates. **(a)** One group remains in the bone marrow, producing daughter cells that mature into B cells or NK cells. **(b)** The other group migrates to the thymus, where subsequent divisions produce daughter cells that mature into T cells. The mature B cells, NK cells, and T cells circulate throughout the body in the bloodstream and then **(c)** temporarily reside in peripheral tissues.

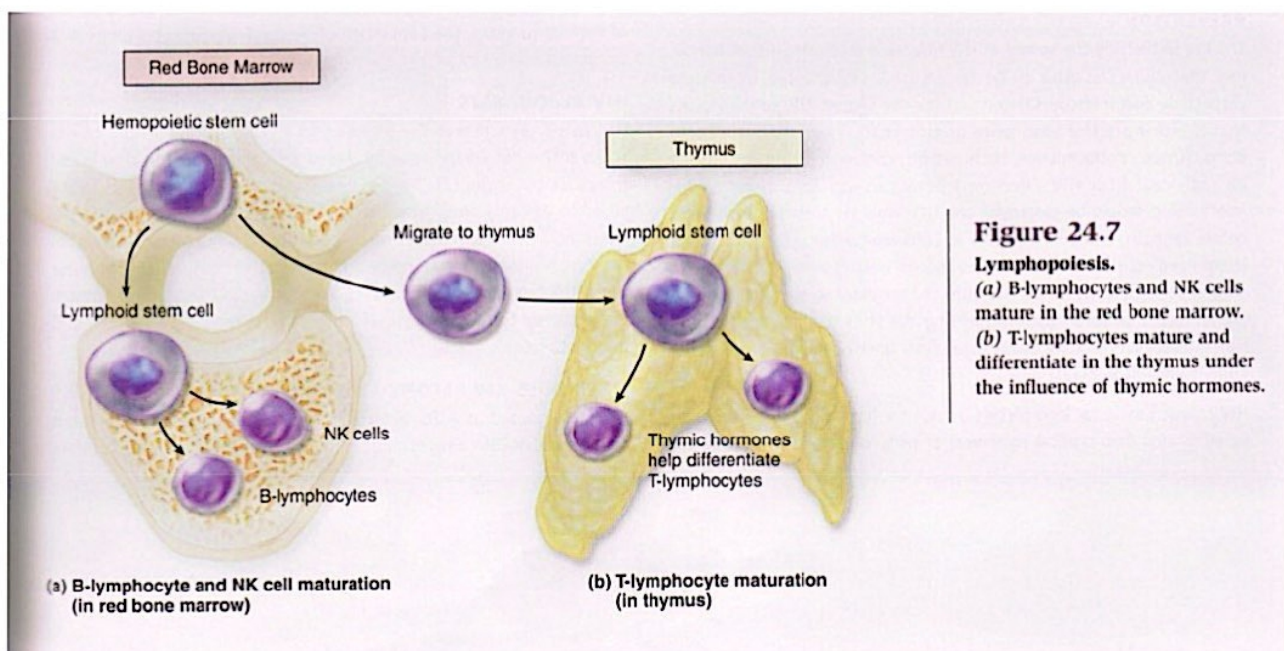




# THYMUS 761



## LYMPHOPOIESIS



**Figure 24.7**  
**Lymphopoiesis.**  
 (a) B-lymphocytes and NK cells mature in the red bone marrow.  
 (b) T-lymphocytes mature and differentiate in the thymus under the influence of thymic hormones.

**DISTRIBUTION OF LYMPHOCYTES**  
**IN LYMPHOID ORGANS and BLOOD**

**Lymphoid organ    T- Lymphocyte    B- Lymphocyte**

1- Thymus	100 %	----
2- Lymph Node	60 %	40 %
3- Spleen	45 %	55 %
4- Bone Marrow	10 %	90 %
5- Blood	80 %	20 %

---

**contents:**

**LYMPHOID**

**ORGANS**



# **LYMPHOID ORGANS**

**ORGANS INVOLVES IN LYMPHATIC CIRCULATION  
AND IMMUNE RESPONSE**

---

**LYMPHOID ORGANS are:**

- 1- BONE MARROW**
- 2- THYMUS**
- 3- LYMPH NODES**
- 4- SPLEEN**

## **LYMPHOID ORGANS**

**A number of morphologically and functionally diverse organs and tissues have various functions in the development of immune responses.**

---

***BONE  
MARROW***



---

# **BONE MARROW**

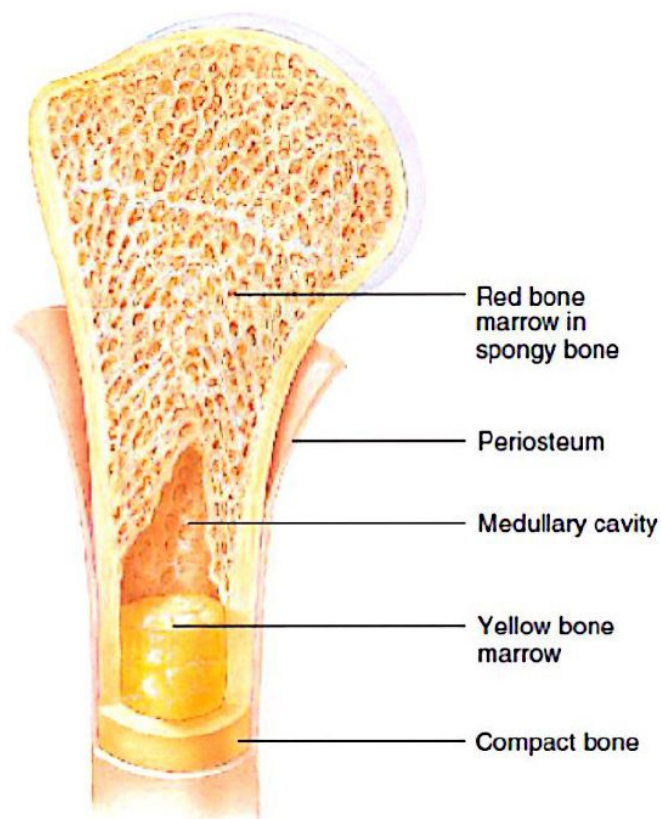
Soft, organic, sponge like material in the cavities of bones. It is a network of blood vessels and **Special connective tissue fibers** that hold together a composite of fat and blood producing cells. Its chief function is to manufacture erythrocytes, leukocytes, and platelets.

## **Types of bone marrow;**

### **1- Red bone marrow**

### **2- Yellow bone marrow.**

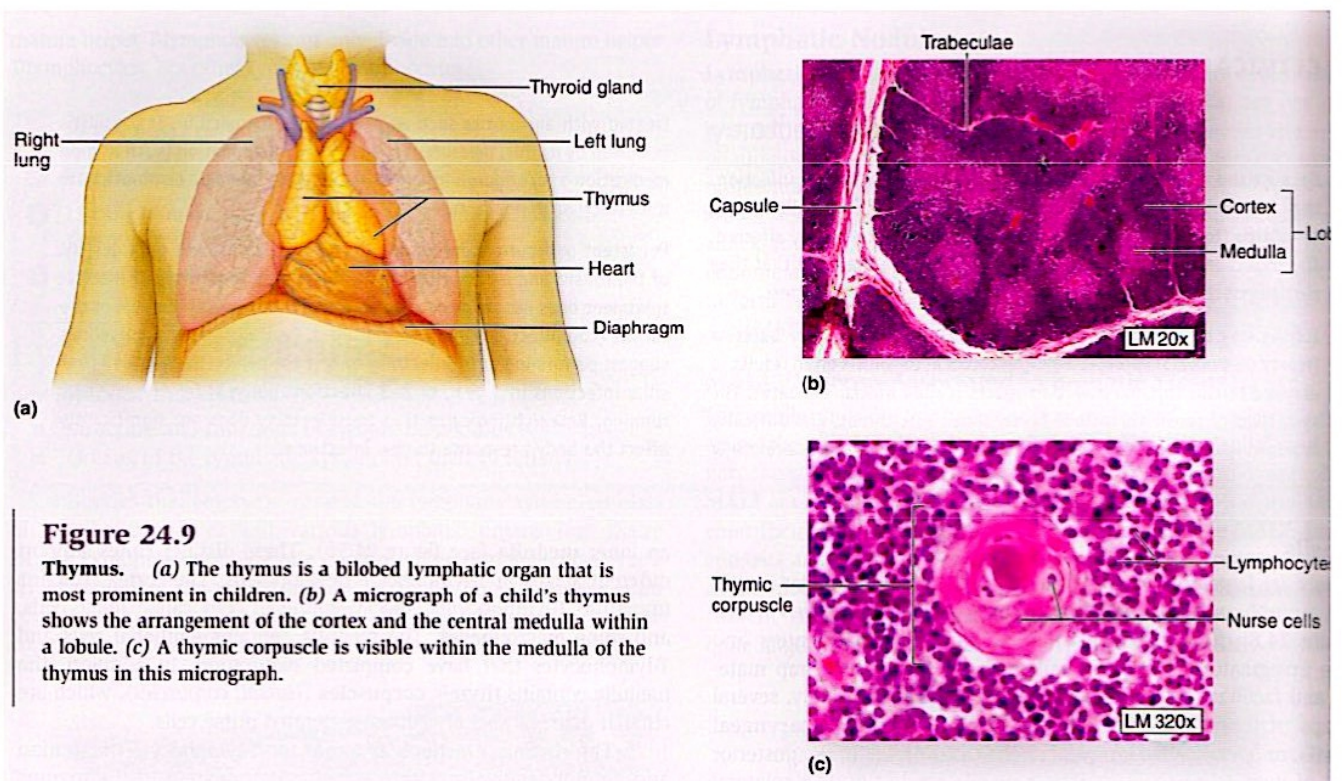
the red produce blood cells, and the yellow is formed from fatty tissue.



**FIGURE 6.2** Hemopoiesis is the process by which blood cells are formed. In an adult, blood cells are formed in the red bone marrow.

# THYMUS

## THYMUS



**Figure 24.9**

**Thymus.** (a) The thymus is a bilobed lymphatic organ that is most prominent in children. (b) A micrograph of a child's thymus shows the arrangement of the cortex and the central medulla within a lobule. (c) A thymic corpuscle is visible within the medulla of the thymus in this micrograph.



# **THYMUS, AND FUNCTIONS 761**

**Inferior to the thyroid gland; in the fetus and infant the thymus is large, with age the thymus shrinks (involution process).**

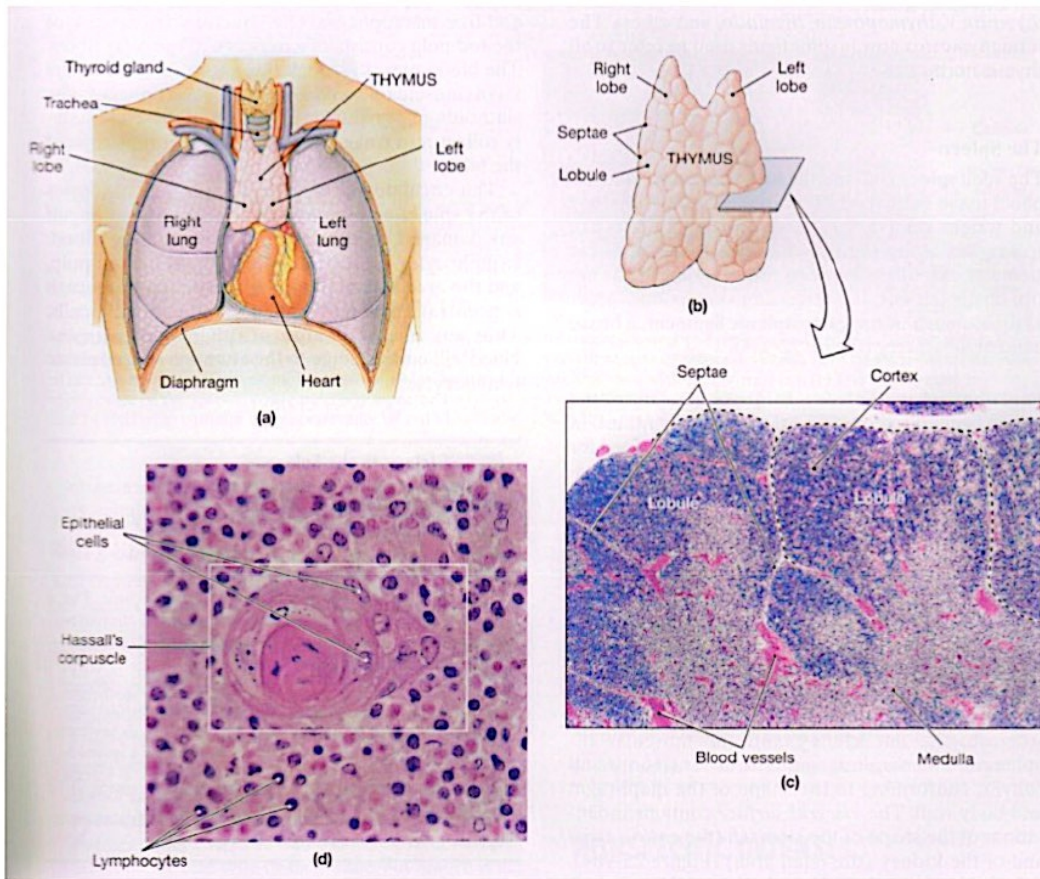
## **FUNCTIONS OF THMUS**

- 1. Produces T lymphocytes (T cells).**
  - 2. Produces thymic hormones that make T cells (called Thymosin ) immunologically competent, that is, able to recognize foreign antigens and provide immunity.**
- 

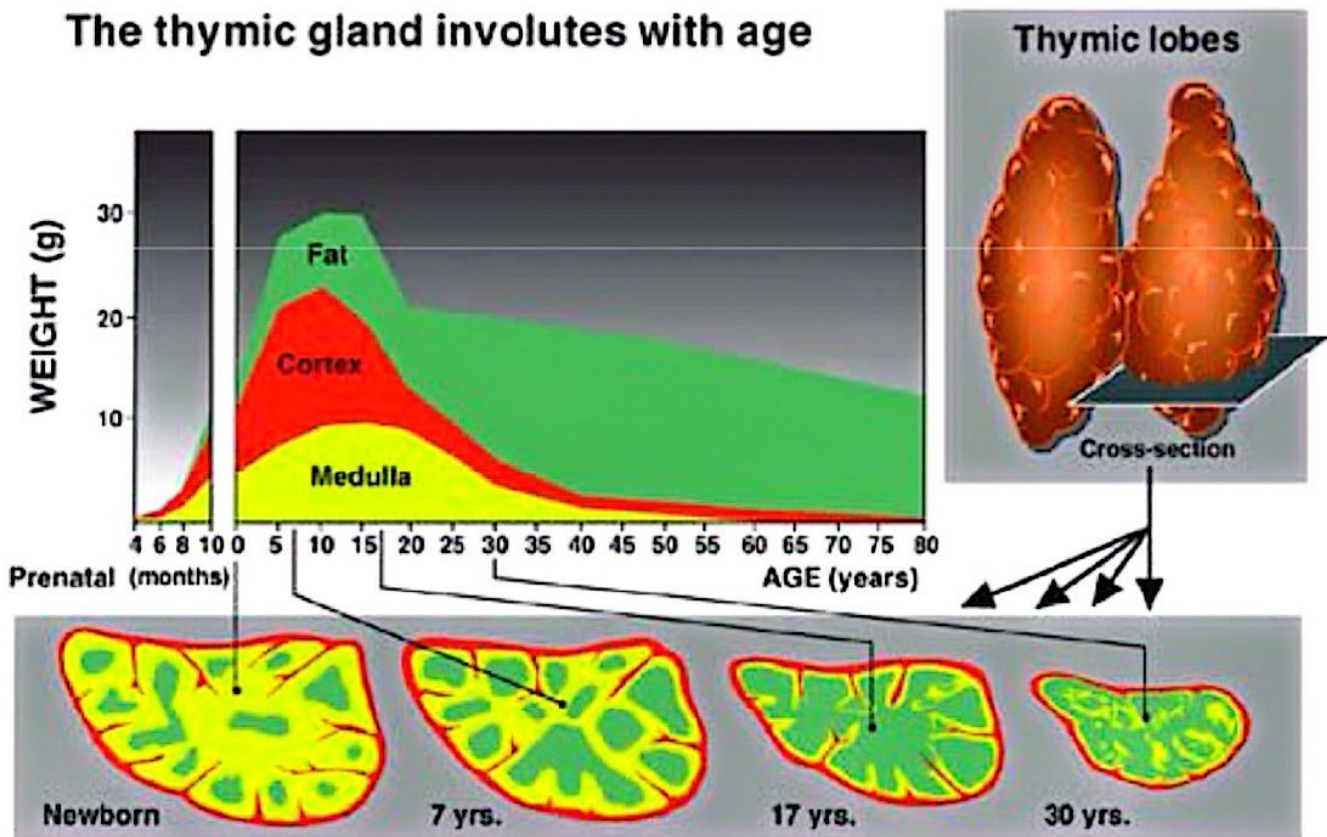
## **STRUCTURES OF THYMUS 761**

- 1- Right and left lobes**
- 2- Lobules (each lobe compose from several lobules)**
- 3- Each lobules compose from :**
  - a- cortex**
  - b- medulla**
  - c- thymic corpuscle (hassall`s corpuscle)**
  - d- lymphocytes**
  - e- epithelial cells**

# THYMUS 761



## The thymic gland involutes with age





# LYMPH NODES

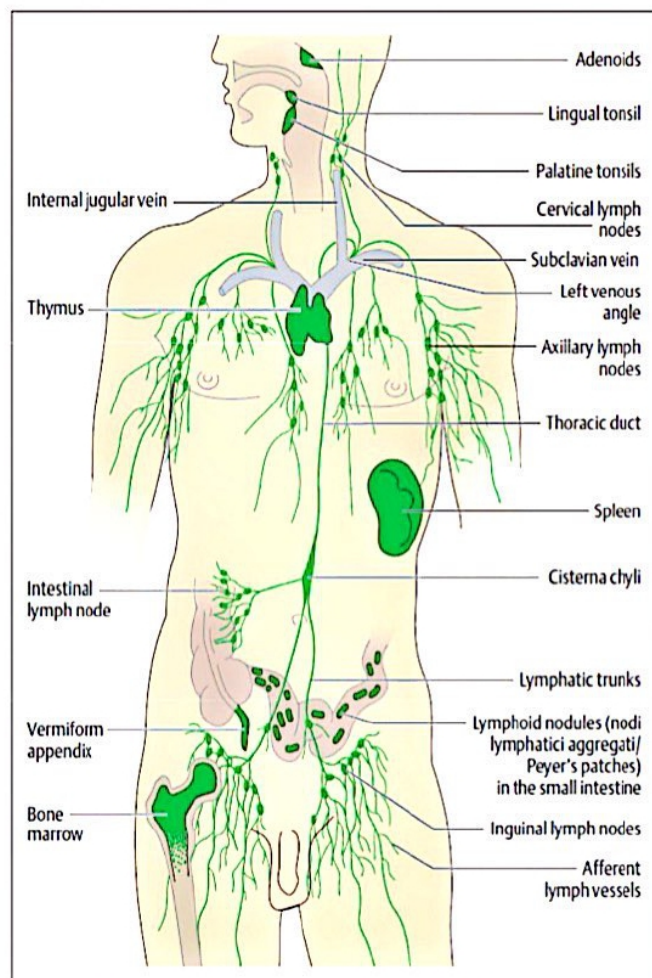


Fig 6.7 Lymphoid organs, lymph vessels, and regional collecting lymph nodes

# **LYMPH NODES      759**

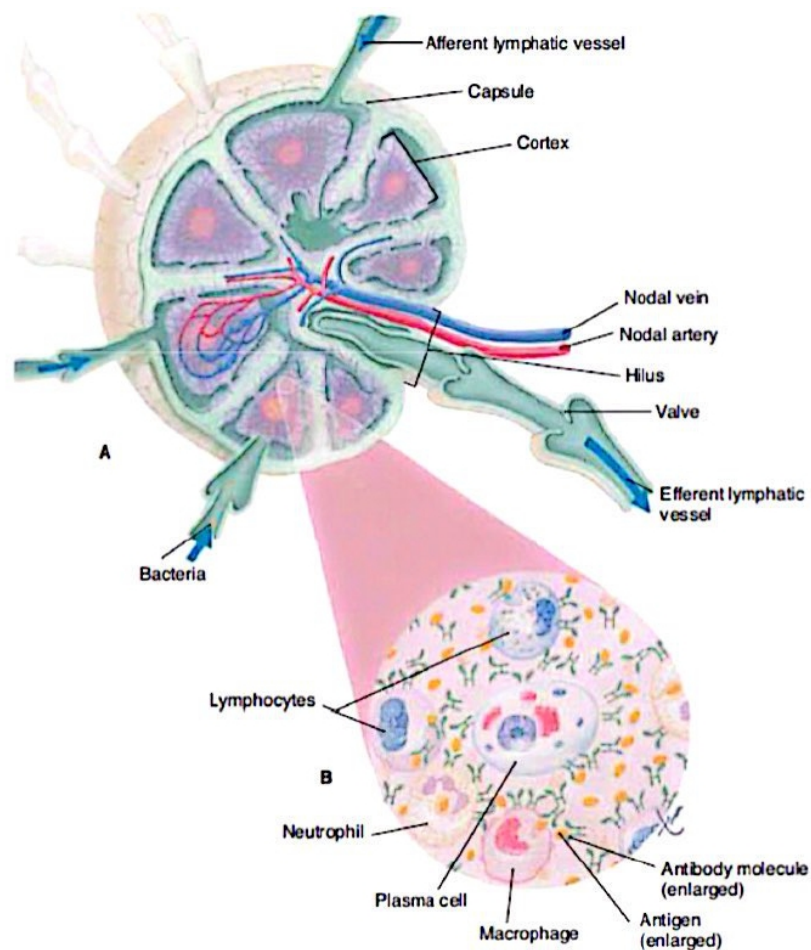
## **Capsulated masses of lymphatic tissue**

- 1- Also called a lymph gland, this node has a round shape and is about 0.4 inch (1 cm) in diameter. Lymph nodes are distributed throughout the body—in the neck, armpits, groin, and popliteal bone (behind the knees), as well as in the thorax and abdomen.
  - 2- Found in groups along the pathways of lymph vessels.
  - 3- The major paired groups of lymph nodes are the cervical, axillary, and inguinal groups. These are at the junctions of the head and extremities with the trunk; remove pathogens from the lymph from the extremities before the lymph is returned to the blood.
- 

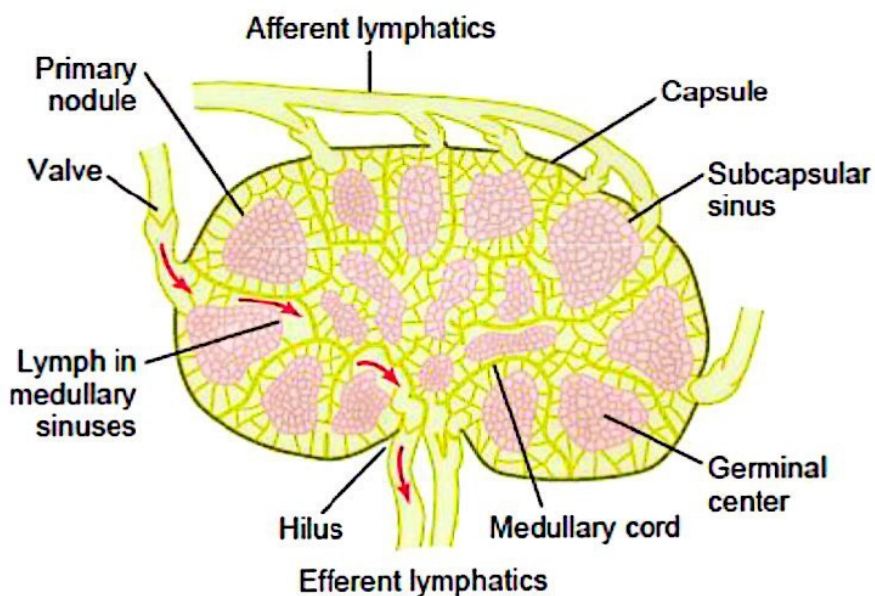
## Continue: **LYMPH NODES**

- 4- The lymph nodes filter harmful microorganisms from the lymph, which returns via blood vessels to maintain the equilibrium of the body's fluids.
- 5- Together with the white blood cells, the lymph nodes are in charge of maintaining the immune system
- 6- As lymph flows through the nodes:
  - foreign material is phagocytized by fixed macrophages
  - lymphocytes are activated and fixed plasma cells produce antibodies to foreign antigens





**Figure 14-4.** Lymph node. (A) Section through a lymph node, showing the flow of lymph. (B) Microscopic detail of bacteria being destroyed within the lymph node.



**Figure 33-3**

Functional diagram of a lymph node. (Redrawn from Ham AW: Histology, 6th ed. Philadelphia: JB Lippincott, 1969.) (Modified from Gartner LP, Hiatt JL: Color Textbook of Histology, 2nd ed. Philadelphia, WB Saunders, 2001.)

## **STRUCTURES OF LYMPH NODE 759**

- 1- Afferent lymphatic vessels
- 2- Efferent lymphatic vessels
- 3- Cortex - contain T and B lymphocytes
- 4- Medulla - contain macrophage and lymphocyte
- 5- Sinuses – contain macrophage
- 6- Capsule
- 7- Trabeculae
- 8- Artery and Vein

---

## **TYPES AND FUNCTIONS OF CELL AND MOLECULES IN LYMPH NODE**

<b><u>TYPE OF CELL</u></b>	<b><u>FUNCTION</u></b>
1- <i>B-lymphocyte</i>	<i>Produce plasma cell (humoral antibody)</i>
2- <i>T-lymphocyte</i>	<i>(cellular immunity)</i>
3- <i>Plasma cell</i>	<i>Produce antibodies</i>
4- <i>Macrophage</i>	<i>Phagocytosis</i>
5- <i>Neutrophil</i>	<i>Phagocytosis</i>
6- <i>Dendritic cell</i>	<i>Like Macrophage</i>
7- <i>Antibodies</i>	<i>Neutralize antigen</i>
8- <i>Antigen</i>	<i>Tissue damage</i>



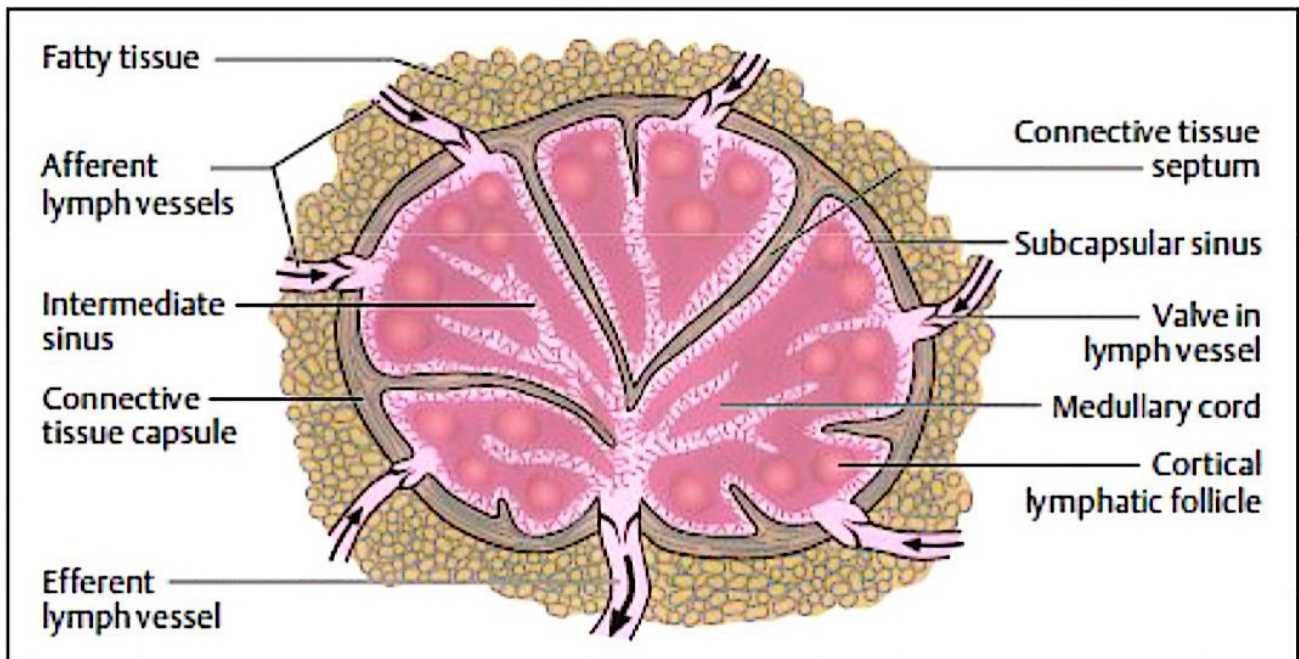
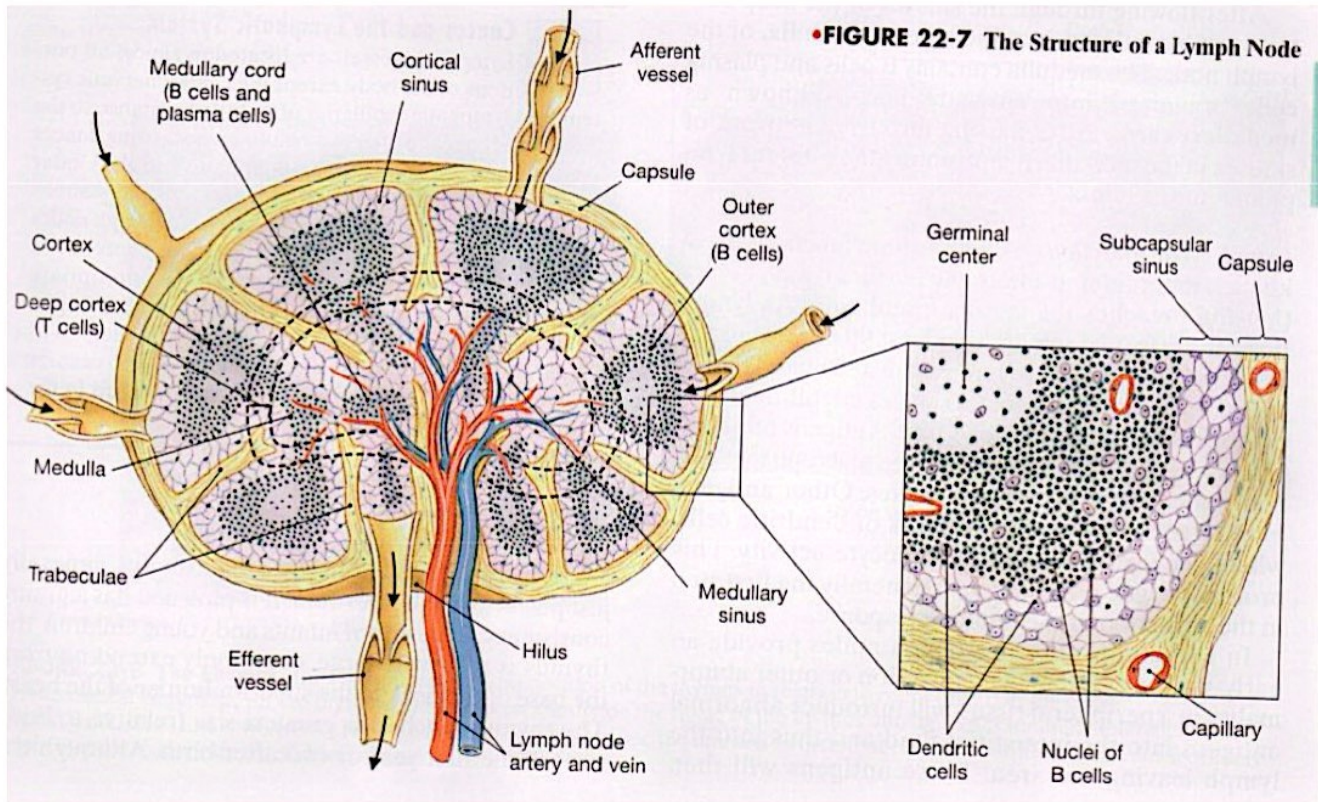


Fig. 6.10 Structure of a lymph node

# ***SUPERFICIAL LYMPH NODES***

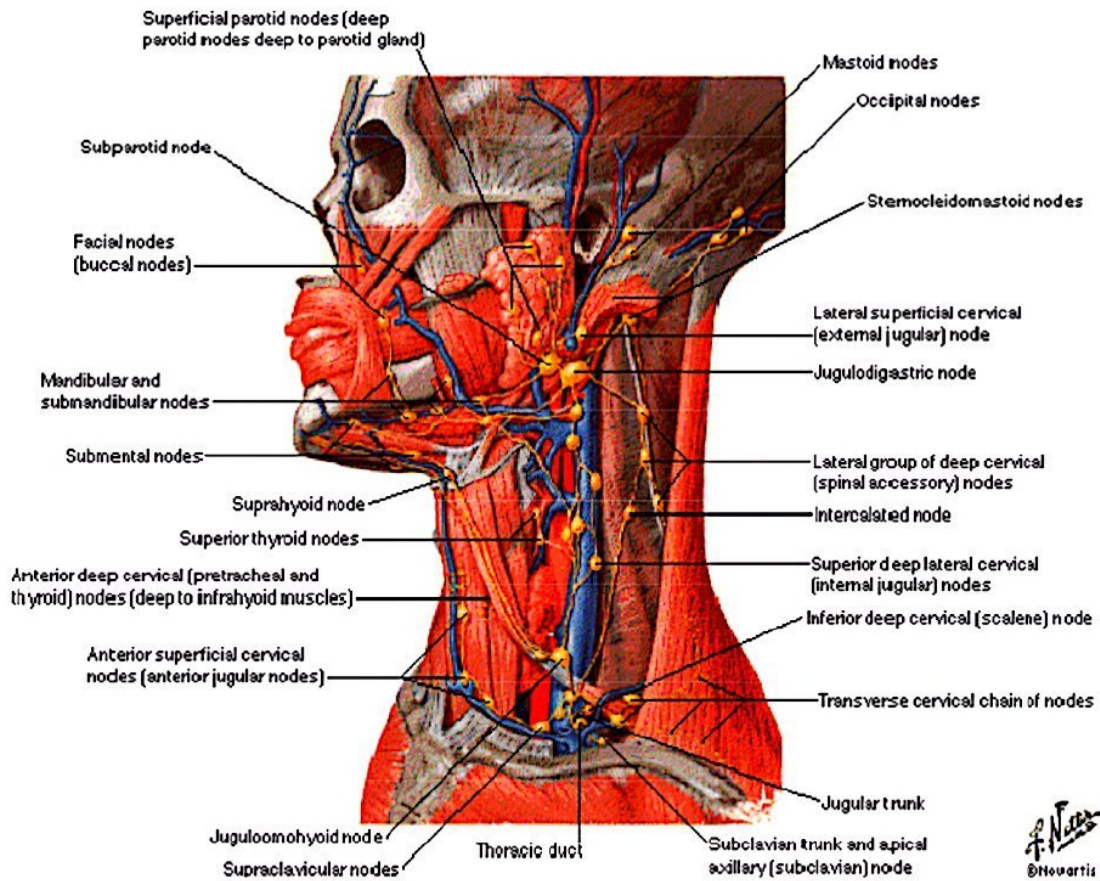
- 1- Submaxillary Lymph Nodes
  - 2- Cervical Lymph Nodes
  - 3- Axillary Lymph Nodes
  - 4- Inguinal Lymph Nodes
  - 5- Popliteal Lymph Nodes
  - 6- Adenoids Lymphoid Tissues
  - 7- Lingual Tonsils
- 

# ***DEEP LYMPH NODES***

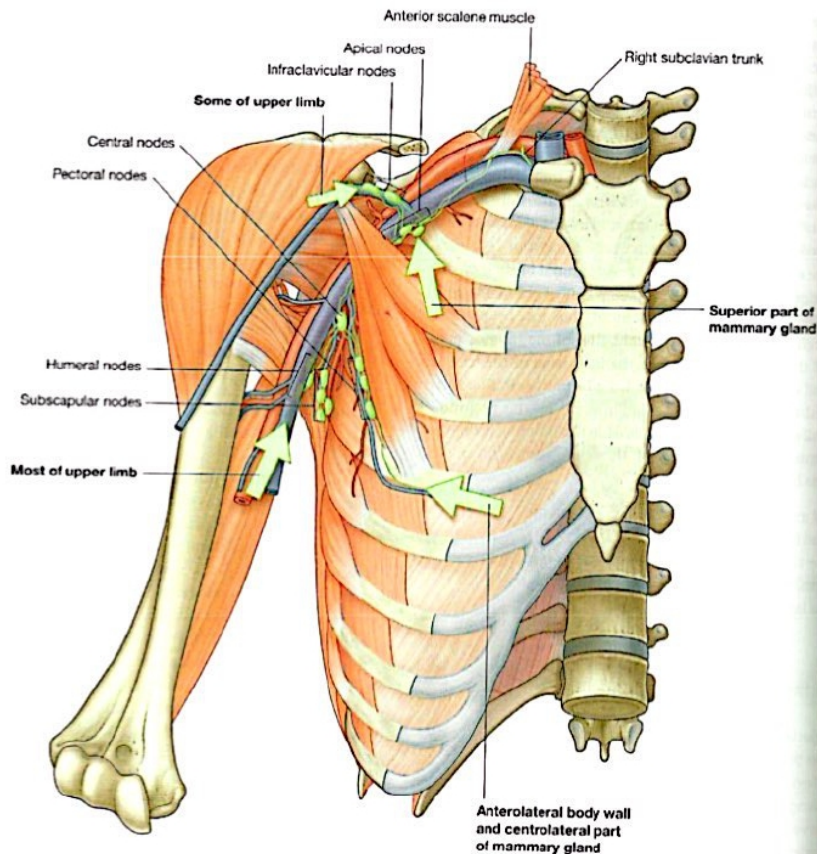
- 1- Cervical L.N.
- 2- Retropharyngeal L.N.
- 3- Tracheobronchial L.N.
- 4- Hilar L.N.
- 5- Parasternal L.N.
- 6- Aortic L.N.
- 7- Hepatic L.N.
- 8- Pancreatic L.N.
- 9- Celiac L.N.
- 10- Mesenteric L.N.



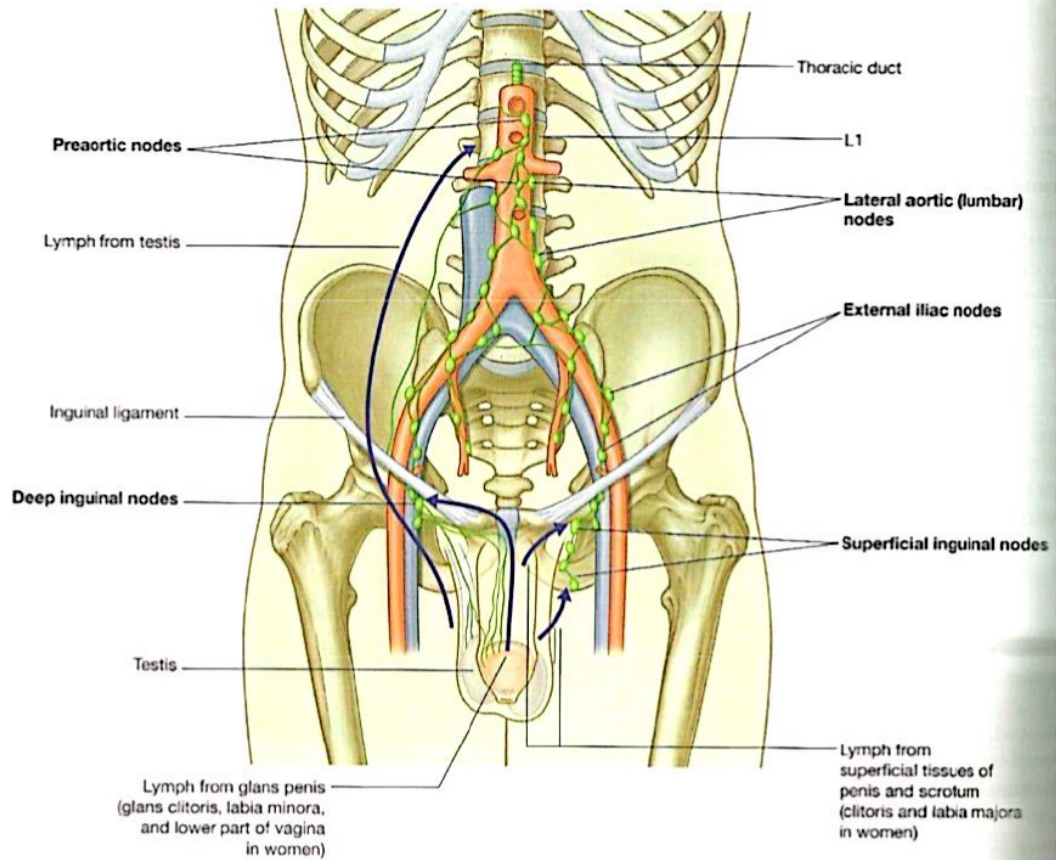
# Lymph Vessels and Nodes of Oral and Pharyngeal Regions



*of Notes*  
©Houartis



. 7.56 Lymph nodes and vessels in the axilla.



**Fig. 5.79** Lymphatic drainage of the perineum.

# ***SPLEEN***



# **SPLEEN, AND FUNCTIONS 763**

*Located in the upper left abdominal quadrant behind the stomach, and it is the largest lymphatic organ, and about 100 – 250 gram.*

## **FUNCTIONS OF SPLEEN**

I. The fetal spleen produces RBCs.

II. Functions after birth:

- 1- Filtering the blood.
- 2- Producing WBCs (T- lymphocyte)
- 3- Contains lymphocytes to be activated and fixed plasma cells that produce antibodies.
- 4- Contains fixed macrophages (RE cells) phagocytize pathogens and old RBCs.
- 5- Bilirubin is formed and sent to the liver for excretion in bile. Spleen stores blood and platelets.
- 6- Destroys damaged platelets.

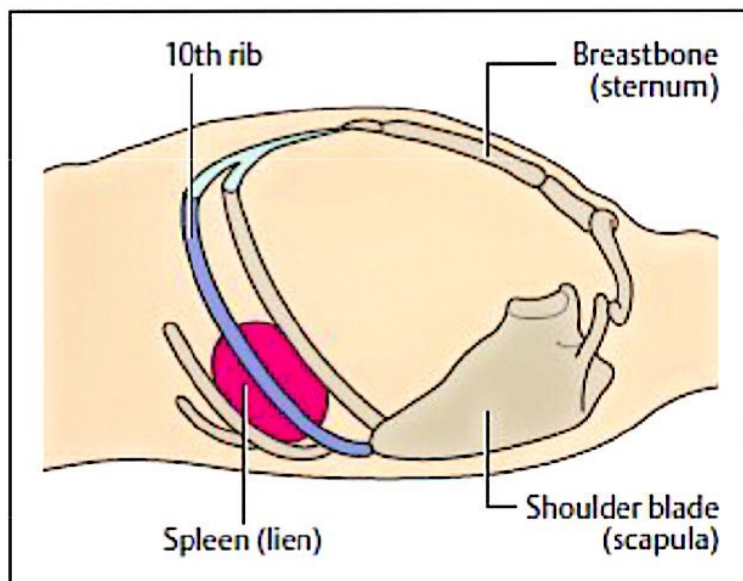
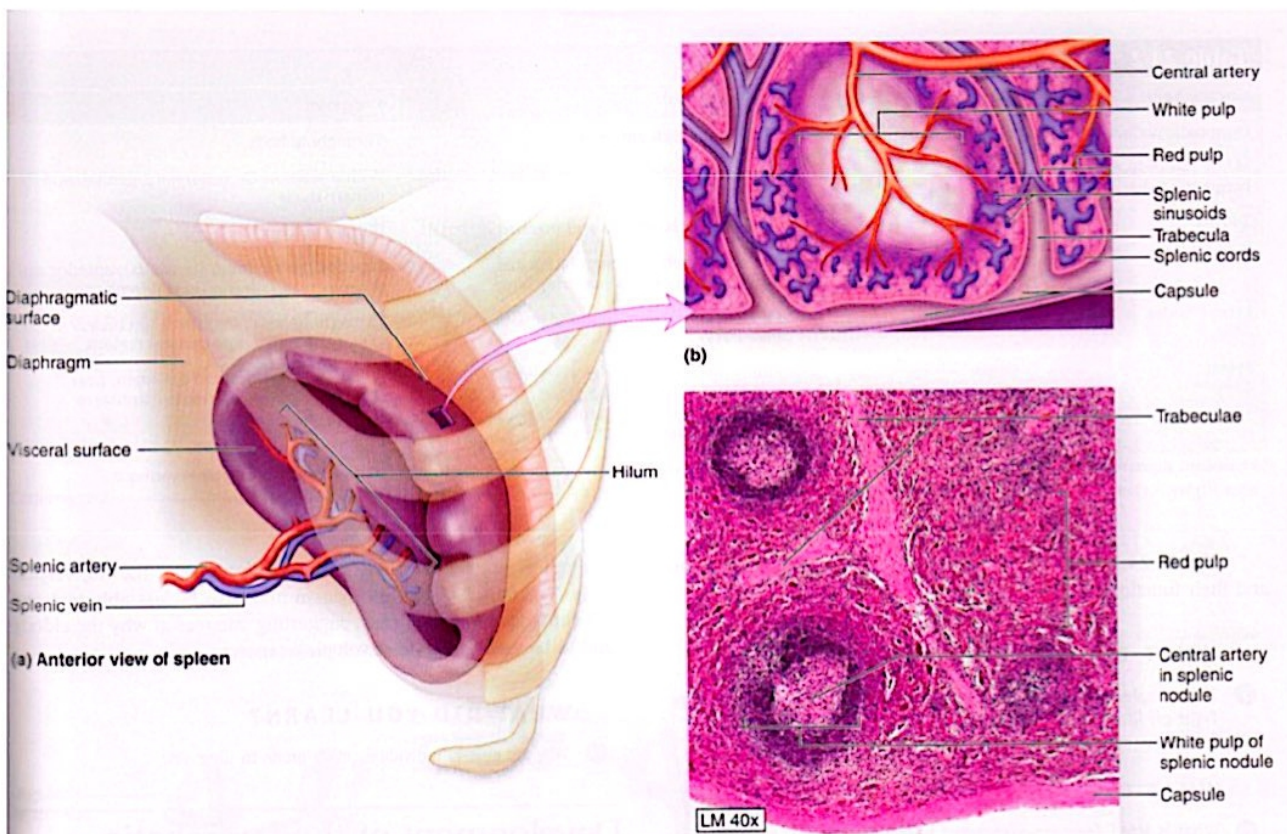


Fig. 6.11 Position of the spleen in a recumbent patient (viewed from the left). A normal-sized spleen is not palpable. It lies in the left upper abdomen with its longitudinal axis at the level of the 10th rib. (After Beske)

# HISTOLOGICAL STRUCTURES OF SPLEEN

- 1- Red pulp: contain normal component of the blood plus fixed and free macrophage, red pulp also contain network of reticular fibers, and sinusoid lined by fixed macrophage. Lymphocytes are scattered throughout the red pulp.
- 2- White pulp: resembles lymphoid nodules (composed from lymphocytes), and surrounded by high concentration of macrophages and dendritic cells.
- 3- Trabecular arteries.
- 4- Trabecular veins.
- 5- Capsule.

## SPLEEN





# Functional structures of the spleen

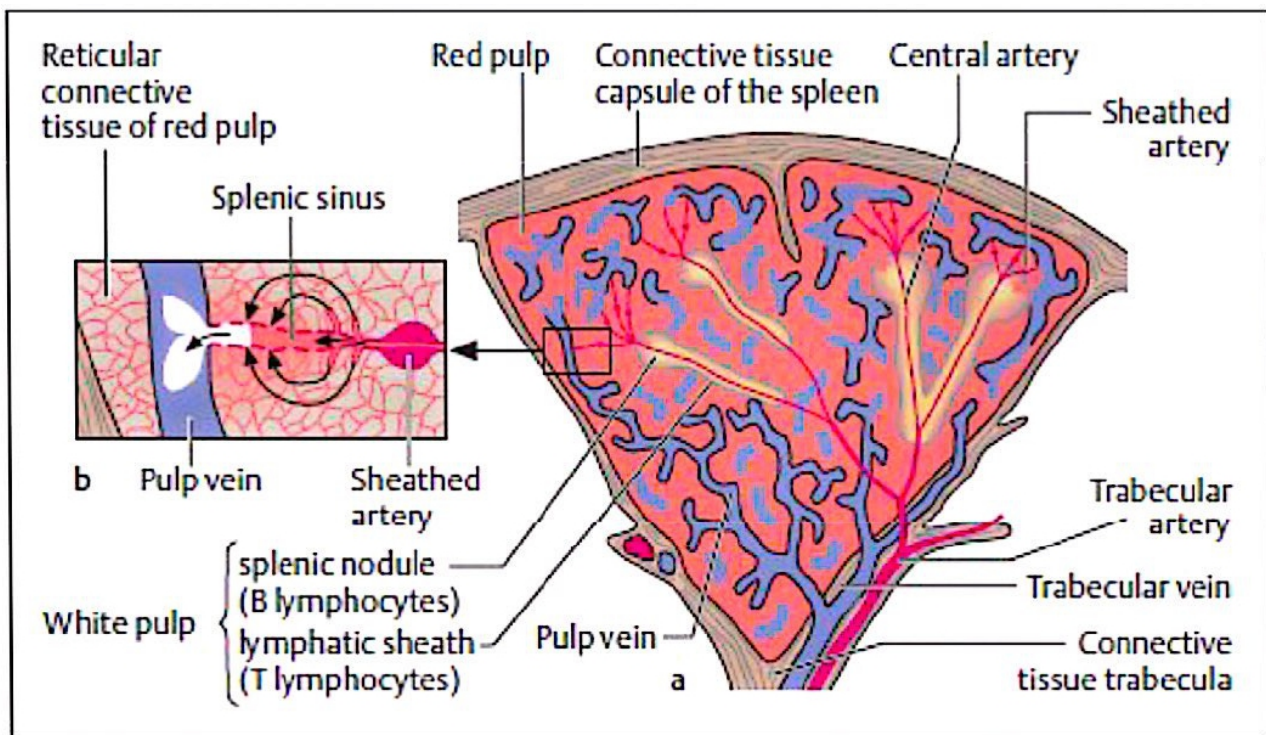


Fig. 6.12 a Simplified representation of the internal structure of the spleen. b Magnification of a section from a

## V- LYMPHOID TISSUES

### ( LYMPH NODULES )

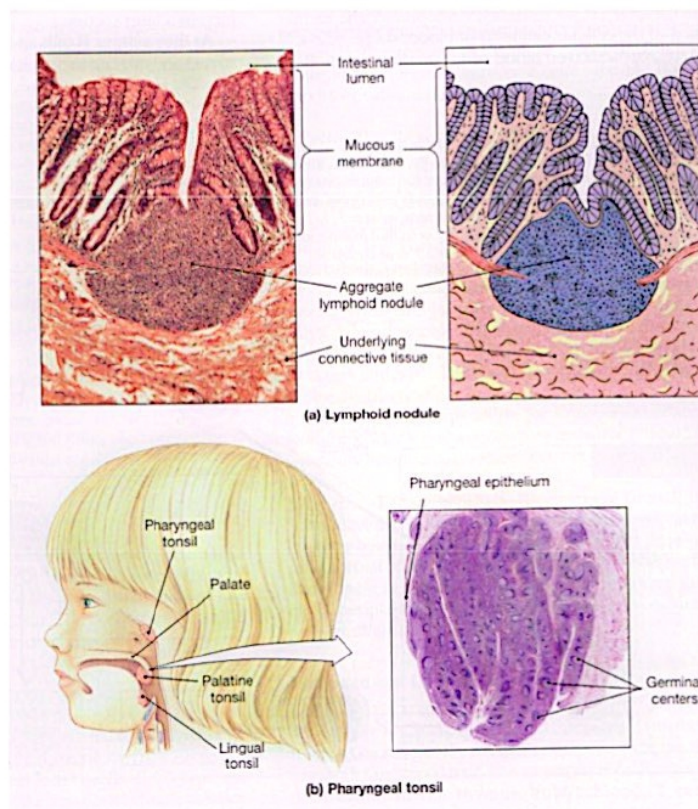
# LYMPHOID TISSUES 758

## ( LYMPH NODULES )

Small unencapsulated masses of connective tissues dominated by lymphocytes (lymphatic tissue)

1. Found beneath the epithelium of all mucous membranes, that is, the tracts that have natural opening to the environment.
2. Destroy pathogens that penetrate the epithelium of the respiratory, digestive, urinary, or reproductive tracts.
3. Tonsils are the lymph nodules of the pharynx.
4. Peyer's patches are those of the small intestine.
5. MALT (mucosa associated lymphoid tissue).

## LYMPHOID NODULES 758





## • Bone

- **Definition of Bone:** Bones are rigid organs forming the skeleton, providing structure, protection, and support for the body.

### **Functions of Bones:**

- Structural support for the body.
- Protection of vital organs (e.g., skull protects the brain, ribcage protects the heart and lungs).
- Facilitation of movement through articulation with muscles.
- Storage of minerals, especially calcium and phosphorus.
- Hematopoiesis (production of blood cells in the bone marrow).

## **Bone Structure**

- **Macroscopic Anatomy:**
    - **Compact Bone:** Dense outer layer that provides strength.
    - **Spongy Bone (Cancellous Bone):** Lighter, porous inner layer that houses bone marrow.
  - **Microscopic Anatomy:**
    - **Osteocytes:** Bone cells maintaining the bone matrix.
    - **Osteoblasts:** Cells responsible for bone formation.
    - **Osteoclasts:** Cells involved in bone resorption.
- 

## **Types of Bones**

1. **Long Bones:** Found in limbs (e.g., femur, humerus).
  2. **Short Bones:** Cube-shaped (e.g., carpals in the wrist).
  3. **Flat Bones:** Provide protection (e.g., skull, sternum).
  4. **Irregular Bones:** Complex shapes (e.g., vertebrae).
  5. **Sesamoid Bones:** Embedded in tendons (e.g., patella).
- 

## **Bone Growth and Development**

- **Ossification:** The process of bone formation.
  - **Intramembranous Ossification:** Direct bone formation (e.g., skull).
  - **Endochondral Ossification:** Bone forms by replacing cartilage (e.g., long bones).
- Growth plates (epiphyseal plates) are regions of growing cartilage in children.

---

## **Bone Remodeling and Repair**

- Continuous process of bone breakdown (resorption) and formation.
- Involves osteoblasts and osteoclasts.
- Influenced by hormones such as:
  - Parathyroid hormone (PTH).
  - Calcitonin.
  - Vitamin D.

---

## **Common Disorders of Bones**

1. **Osteoporosis:** Reduced bone density, leading to fractures.
2. **Osteomalacia/Rickets:** Softening of bones due to vitamin D deficiency.
3. **Fractures:** Types include simple, compound, and stress fractures.
4. **Osteoarthritis:** Degeneration of joint cartilage.

---

## **Role of Physical Therapy in Bone Health**

- Exercises to enhance bone strength and mobility.
- Techniques for rehabilitation after fractures or surgeries.
- Prevention strategies for bone-related conditions



## **The Respiratory System**

**The respiratory system, comprising the lungs and a sequence of airways leading to the external environment, functions in providing oxygen (O<sub>2</sub>) to and eliminating carbon dioxide (CO<sub>2</sub>) from the cells of the body.**

**Is subdivided into:**

- 1- conducting portions
- 2- respiratory portions

**Conducting portion Parts:**

nasal cavity, nasopharynx, larynx, trachea, primary bronchi, secondary (lobar) bronchi, tertiary (segmental) bronchi, and terminal bronchioles.

**functions:**

clean, warm and moisten air prior to reaching respiratory portion

**2- respiratory region ( respiratory epithelium )**

Ciliated columnar cells, Brush cells, Basal cells, Small granulecells, Goblet cells

**3- Olfactory region**

Olfactory epithelium comprises three types of cells: Olfactory cells

Sustentacular cells, Basal cells

## **Nasopharynx**

Epithelium is respiratory similar to the epithelium of nasal cavity

## **Larynx : It is conduct between pharynx and trachea**

**Epiglottis:** is an elastic cartilage of larynx . It is lined by stratified squamous epithelium on lingual surface Pseudostratified ciliated columnar epithelium lined the laryngealside.

**Trachea:** is a tube that connect the pharynx and larynx to the lung, allowing the passage of air . the trachea has three layers: mucosa, sub mucosa and adventitia.

**1- Mucosa,** composed of pseudostratified ciliated columnar epithelium with presence of goblet cells.

**2- Submucosa,** composed of dense irregular connective tissue housing numerous mucous and seromucous glands.

**3- Adventitia,** composed of c-ring of hyaline cartilage.

Trachea divided into two portion left and right (primary bronchi) that enter the lung, primary bronchi divided and gives secondary bronchi (three in right lung and two in left lung). Secondary bronchi continue to divided within the lung, and after multiple division give rise the bronchioles, terminal bronchiole and respiratory bronchioles (include alveoli , alveolar sacs and alveolar ducts).



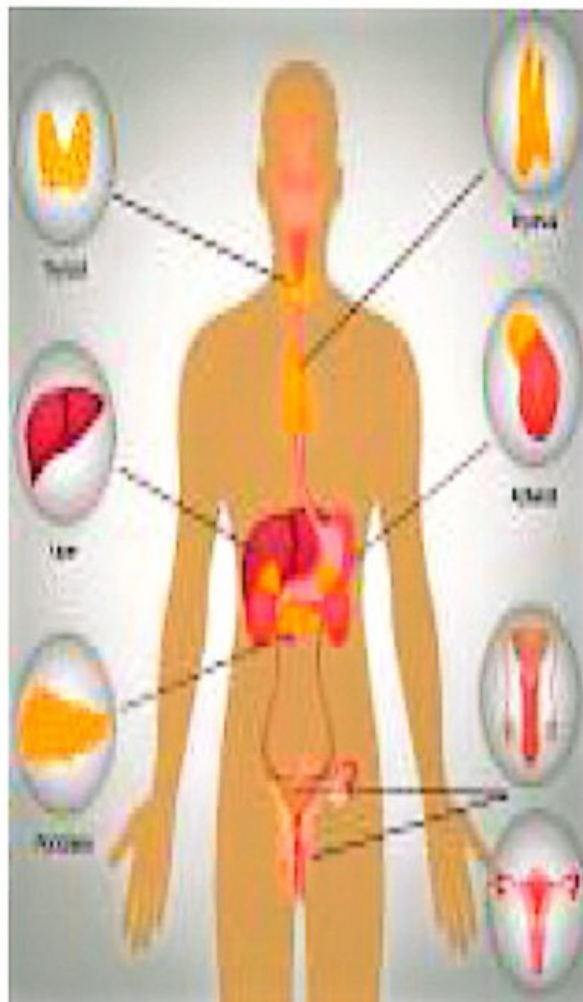
The structure of primary bronchi and secondary bronchi is identical to that of the trachea, with the following exception, the cartilage c-ring are replaced by irregular plates of hyaline cartilages.

**Bronchioles:** not possessing cartilage in their wall, the epithelial lining is pseudostratified ciliated columnar epithelium, with presence of Clara cells instead of goblet cells. Clara cells are columnar, are believed to protect the bronchiolar epithelium by lining it with their secretory product (secret glycoprotein) . the underlining epithelium is connective tissue and a layer of smooth muscles.

**Terminal bronchioles:** composed of simple cuboidal epithelium with Clara cells, the underlining epithelium is connective tissue and a layer of smooth muscles. Terminal bronchioles branch to give rise to respiratory bronchioles or respiratory portion.

**Respiratory bronchioles** (Respiratory portion) composed of alveolar ducts, alveolar sacs and alveoli. The wall of respiratory portion composed of simple squamous epithelium and smooth muscles.

# *THE ENDOCRINE* *SYSTEM*





# *THE ENDOCRINE SYSTEM*

**Endocrinology**, a branch of internal medicine, is the conventional field of study dealing with the endocrine system and its disorders.

The Functional model of endocrinology, which focuses on underlying mechanisms that contribute to hormone imbalance, is growing rapidly.

**Endocrine system**, a plethora of hormones regulate many of the body's functions, including growth and development, metabolism, electrolyte balances, and reproduction, this is done through a group of glands that secrete hormones directly into the circulatory system for subsequent transportation to distant target organs. The word endocrine means endo- "inside, within," and krinein.

## **Glands of the endocrine system**

A gland is an organ that generates and secretes hormones that perform particular functions in the body. The chemicals produced by endocrine and exocrine glands are released into bloodstream.

Hormones are molecules that are produced by endocrine glands, including the hypothalamus, pituitary gland, pineal gland, adrenal glands, gonads, (i.e., testes and ovaries), thyroid gland, parathyroid glands, and pancreas. The term "endocrine" implies that in response to specific stimuli, the products of those glands are released into the bloodstream.

Endocrine glands have no ducts; instead, they secrete hormones directly into the blood or circulatory system; hormones then travel to cells of the target organ. In contrast, exocrine glands, such as salivary glands, secrete saliva into ducts. Endocrine control is regulated by chemical messengers (hormones).

## **What Are Hormones**

A hormone is a chemical messenger that is transported via the bloodstream to act on distant target cells. The word hormone comes from the Greek word hormone, which means to excite or stimulate

Some hormones have only a few specific target cells, whereas other hormones affect numerous cell types throughout the body. The target cells for each hormone are characterized by the presence of certain docking molecules (i.e., receptors) for the hormone that are located either on the cell surface or inside the cell. The interaction between the hormone and its receptor triggers a cascade of biochemical reactions in the target cell that eventually modify the cell's function or activity.

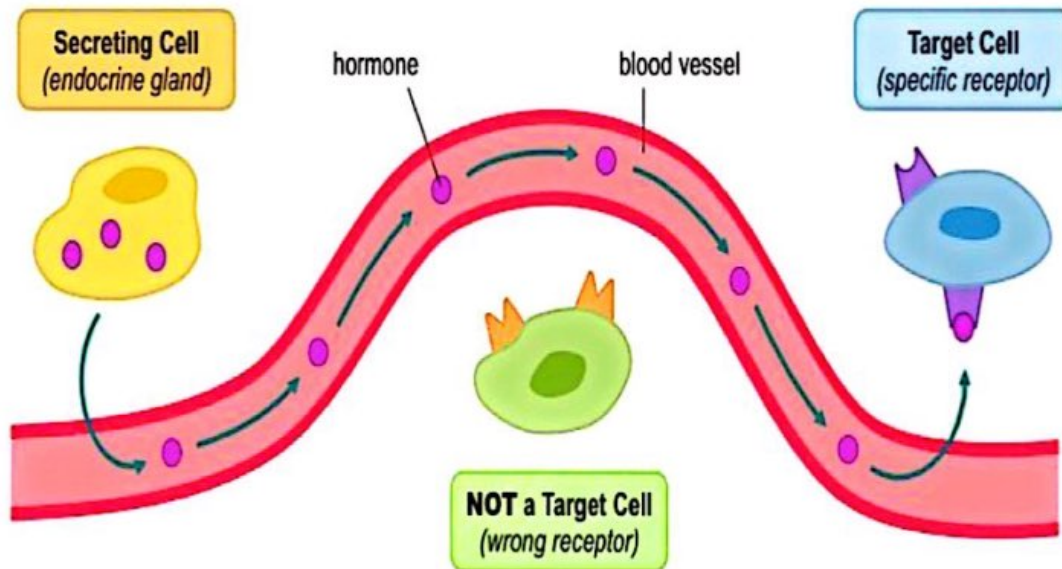
## **How does the endocrine system communicate?**

The biochemical process, known as endocrine signaling, is what serves to regulate the body's organs. The endocrine system is like a news network for the body that broadcasts hormonal messages to regulate bodily functions.

## **CLINICAL DISORDERS OF THE ENDOCRINE SYSTEM**

Clinical disorders of the endocrine system affect the secretion of hormones from the endocrine gland. Autoimmune diseases and tumors (either benign or cancerous) of the endocrine glands are the two main causes of disorders of the endocrine system. These diseases can cause either hypersecretion or hyposecretion of hormones. The most common diseases of the endocrine system are diabetes mellitus and diseases of the thyroid. Once a diagnosis is made, treatment may involve replacement of missing hormones or surgery.





Gland	Hormone	Target Organ	Function
Pineal gland	melatonin	many	biological clock
Pituitary gland	FSH / LH ADH growth hormone oxytocin prolactin	ovaries kidneys many uterus breast tissue	menstrual cycle osmoregulation growth & division birth contractions milk production
Thyroid gland	thyroxin	liver	metabolic rate
Adrenal glands	adrenaline cortisol	many many	fight or flight anti-stress
Pancreas	insulin / glucagon	liver	blood sugar levels
Ovaries	estrogen / progesterone	uterus	menstrual cycle
Testes	testosterone	many	male characteristics

### **Three different types of stimuli trigger actions of endocrine glands:**

1. **Humoral stimuli:** An example is regulation of blood glucose by the pancreas. High blood glucose levels stimulate the pancreas to secrete insulin while low blood glucose levels stimulate the pancreas to secrete glucagon. Insulin lowers blood glucose while glucagon raises blood glucose.
2. **Neural stimuli:** An example is the response of the sympathetic nervous system to stress. In response to stress, the adrenal gland secretes epinephrine and norepinephrine; other names for these hormones are adrenaline and noradrenaline. In times of short-term stress, for example, narrowly escaping a bicycle accident, these hormones increase heart rate and blood glucose to prepare the body for a quick response.
3. **Hormonal stimuli:** An example is when the hypothalamus regulates the secretion of the anterior pituitary hormones, releasing hormones and inhibiting hormones. The cascade of events begins with environmental stress, such as cold environmental temperatures which stimulate the secretion of thyroidstimulating hormone-releasing hormone (TSH-RH) from the hypothalamus. TSH-RH then stimulates the release of thyroid-stimulating hormone (TSH) from the anterior pituitary gland. TSH travels in the blood stream to the thyroid gland. Direct action of TSH on the thyroid gland is the secretion of thyroid hormone. The thyroid hormone increases heat production to warm the body.



## Classification and Functions of the Endocrine System

\* Adrenal gland (ah'-dre-nal):- two adrenal glands sit atop each kidney; each consists of two portions: the central region or *adrenal medulla* and the outer region or *adrenal cortex*. The adrenal cortex it secretes three types of *steroid* hormones called *corticosteroids*. The adrenal medulla, the inner portion of the adrenal gland, secretes two nonsteroidal hormones called *catecholamines*, *adrenaline (epinephrine)* and *noradrenaline (norepinephrine)*.

\* Ovaries (oh-vah-reez):- female gonads; two small glands located in the upper pelvic cavity, on either side of the uterine wall, near the fallopian tubes; each is almond shaped and held in place by ligaments. Ovaries produce mature ova as well as two hormones (*estrogen* and *progesterone*) responsible for female sex characteristics and regulation of the menstrual cycle.

\* Pancreas (pan-kree-as):- an elongated structure located behind the stomach in the left upper quadrant. The specialized cells that produce hormones are called the *islets of Langerhans*; these cells produce two hormones, *insulin* and *glucagon*, and both play a role in maintaining normal glucose levels.

\* Parathyroid (par'-ah-thi-royd):- The parathyroid glands are four pea-sized organs found in the neck embedded in the back side of the thyroid glands. When blood calcium levels are low, the parathyroid glands secrete parathyroid hormone or *parathormone (PTH)*, which increases blood calcium levels.

\* Pineal (pin-e-al):- is a cone-shaped structure attached by a stalk to the posterior wall of the cerebrum, secretes *melatonin*, the hormone that responds to darkness in the external environment. Darkness stimulates nerve impulses in the eyes to decrease and the secretion of melatonin to increase. The pineal gland functions as a "biological clock" to regulate patterns of sleeping, eating, and reproduction.

\* Pituitary gland (pe-tu-i-tar-ee):- also known as the hypophysis, the pituitary gland is about the size of a pea and is located on the underside of the brain in a depression at the base of the skull, protected by the brain above it and the nasal cavities below it. The pituitary is a very complex gland that is often referred to as the "master gland," because it produces

many hormones that affect body functions and because it travels throughout the body to stimulate other endocrine glands to secrete hormones. The pituitary gland secretes growth hormone (GH), prolactin (PRL), thyroid-stimulating hormone (TSH), adenocorticotropin (ACTH), gonadotropins (FSH, LH), antidiuretic hormone (ADH), and oxytocin.

\* Testes (tes-teez):- male gonads, also known as testicles, are two glands suspended from the inguinal region of the male by the spermatic cord and surrounded by the scrotal sac. Testes are the primary organs of the male reproductive system. produce sperm cells and secrete *testosterone*.

\* Thymus (thi-mus):- a single gland located behind the sternum in the mediastinum; it resembles a lymph gland in structure because it not only is a part of the lymphatic system, but it also is a hormone-secreting endocrine gland. The gland secretes *thymosin* and *thymopoietin* which stimulates the production of T cells, the specialized lymphocytes involved in the immune response.

\* Thyroid (thi-royd):- consisting of a right and left lobe, located in front of the neck just below the larynx; the lobes are connected by a narrow piece of thyroid cartilage that produces the prominence on the neck known as Adam's apple. Thyroid hormones affect metabolism, brain development, breathing, heart and nervous system functions, body temperature, muscle strength, skin dryness, menstrual cycles, weight, and cholesterol levels.



## **Clinical Disorders of the Endocrine System**

### ***Clinical Disorders of the Pituitary Gland***

\* Acromegaly (ak'-ro-meg-ah-le):- hypersecretion of the pituitary growth hormone (GH) after maturity; causes abnormal enlargement of the extremities of the skeleton, nose, jaws, fingers, and toes.

Most common cause is a noncancerous tumor of the pituitary gland.

\* Congenital growth hormone deficiency (con-gen-i-tal groth hor-mone de-fi-cien-cy):- abnormalities in the development of the pituitary gland and surrounding structures, resulting in short stature in children unless treated with growth hormone (GH).

\* Cushing's disease (koosh-ingz di-zez):- excessive growth of the pituitary gland caused by a tumor of the pituitary gland; results in the release of too much ACTH, which then leads to overproduction of cortisol. Symptoms of excess cortisol are obesity, weakness, moon face, edema, and high blood pressure.

\* Diabetes insipidus (dye-ah-bee-tez insi-ih-dus):- insufficient excretion of antidiuretic hormone (ADH; vasopressin) by the posterior pituitary gland; most common cause is damage to the pituitary gland (or hypothalamus) from head injury, surgery, or tumors. Lack of ADH causes the kidney tubules to fail to reabsorb needed water and salts. Clinical symptoms include *polyuria* (increased urination) and *polydipsia* (increased thirst); excessive thirst results in drinking large volumes of water and a very dilute urine.

\* Hypopituitarism (hahy-poh-pi-too-ituh-riz-uh-m):- pituitary insufficiency may be caused by a tumor or injury to the pituitary gland. Usually affects the anterior pituitary and releasing hormones necessary for normal functioning of other endocrine glands (thyroid, adrenal cortex, ovaries and testes).

\* Hyperprolactinemia (hy-per-pro-lac-ti-nemi-a):- higher than normal amounts of prolactin in the blood and production of breast milk in women when not pregnant or nursing; caused by tumor of the pituitary gland, certain medications, and chronic liver or kidney disease.

### ***Clinical Disorders of the Thyroid Gland***

congenital hypothyroidism (cretinism)( con-gen-i-tal hypo-thy-roid-ism

(kre-ti-nizm)):- overactive parathyroid gland with excessive secretion of parathyroid hormone (PTH); most common cause is a benign tumor of the parathyroid gland. PTH increases serum calcium by releasing calcium from bone, reabsorption of calcium by the kidney, and increasing phosphorous excretion by the kidney.

\* Graves' disease (Graves di-zez):- toxic diffuse goiter; autoimmune disease and most common cause of hyperthyroidism in the United States. Symptoms are nervousness, difficulty sleeping, fatigue, weight loss, goiter, and a protrusion of the eyeballs.

\* Hashimoto's disease (hash'-i-mo-toz di-zez):- chronic lymphocytic thyroiditis; most common cause of hypothyroidism in the United States. An autoimmune disease of the thyroid gland, with replacement of normal tissue with lymphoid tissue. The end result is a lack of production and secretion of thyroid hormone.

\* Thyroid nodule (thy-roid nod-ule):- solid or fluid-filled lumps within the thyroid gland; most are benign (noncancerous), although in some cases, the nodules produce excessive amounts of thyroxine .

\* Myxedema (mik'-se-de-mah):- advanced form of hypothyroidism in adults; a dry, waxy type of swelling with deposits of mucin in the skin, swollen lips, and thickened nose.

### ***Clinical Disorders of the Parathyroid Gland***

\* primary hyperparathyroidism (PHPT)(pri-ma-ry hy-perpar-a-thy-roid-ism)

overactive parathyroid gland with excessive secretion of parathyroid hormone (PTH); most common cause is a benign tumor of the parathyroid gland. PTH increases serum calcium by releasing calcium from bone, reabsorption of calcium by the kidney, and increasing phosphorous excretion by the kidney.

\* Secondary hyperparathyroidism (sec-ond-ar-y hy-perpar-a-thy-roid-ism):- overactive parathyroid gland secondary to chronic kidney failure, the most common (*continues*) disease causing secondary hyperparathyroidism.